

# Carbon Dioxide Laser Management of Plantar Verruca: A 6-Year Follow-up Survey

*Patients receiving treatment for plantar verruca by carbon dioxide laser vaporization from 1984 through 1989 were surveyed with follow-up from 3 months to 6 years. Materials and methods, operative technique, and results were reviewed. This procedure was used as both a primary treatment as well as secondary or tertiary treatments on recalcitrant verrucae. Solitary as well as multiple or mosaic lesions were evaluated. Patients were surveyed for elimination of all verrucae, partial or complete recurrence, postoperative complications, and satisfaction.*

*The overall success rate, considering all eight treatment categories, was 75%. Ultimate success rates ranged from 93% for solitary lesions to 62% for multiple recalcitrant lesions. The authors' findings show clinical significance in the marked differentiation of success rates in accordance with the classification scheme. That is to say, initial treatment of a solitary lesion showed a higher success rate than initial treatment of multiple lesions, and initial treatment of virgin lesions showed a higher success rate than initial treatment of recalcitrant lesions. Based on the data accumulated, the authors propose that treatment of plantar verruca be initiated early, i.e., while the lesion is solitary and has been heretofore untreated. On the other hand, those lesions having a second or third treatment by carbon dioxide laser vaporization resulted in a higher ultimate success rate than those which had only one primary treatment. The general conclusion is that carbon dioxide laser management should be considered as a viable treatment alternative in relation to other, more traditional, techniques in the treatment of plantar verruca.*

**John E. Mancuso, DPM, FACFS<sup>1,2</sup>**  
**Steven P. Abramow, DPM, FACFS<sup>2</sup>**

**Ben R. Dimichino, DPM**  
**Mark J. Landsman, DPM**

The treatment of verruca plantaris remains one of the most common and challenging dermatologic lesions with which the podiatric practitioner is faced. Historically, many treatment modalities have been employed for eradication of the lesions. Treatments have ranged from witchcraft (1) to surgical excision. Unfortunately, no one treatment regimen has offered a consistent success rate. This situation prompted the authors of this paper to undertake a 6-year follow-up evaluation of the carbon dioxide laser for removal of plantar verrucae. Materials and methods, operative technique, and results were reviewed. The procedure was used both as a primary treatment as well as a secondary or tertiary treatment on recalcitrant verrucae.

## Literature Review

Sollito *et al.* (2) reported a 32.2% cure rate using bleomycin sulfate, although other researchers cited have found a 63% to 95% success rate. Limmer *et al.* (3) used cryosurgery and obtained 91% cure rate. Steele *et al.* (4) reported an 81% and a 61% success rate using monochloroacetic and salicylic acid, respectively. Delacerte (5) reported on ultrasonic techniques for the treatment of plantar verrucae and obtained an 82% success rate. Vance *et al.* (6) examined intralesional recombinant  $\alpha$ -2-interferon (INF) for ablation of pedal verrucae. They reported 53% success rate using  $10^6$  IU of INF. Hughes *et al.* (7) did research on human warts permanently removed by static electricity and noted an 81% success rate. Israel (8) discussed treatment of warts by vaccination and placebo therapy. He found a 52% and 42% success rate, respectively. Norwitz and Marker (9) reported the efficacy of electrocautery (65%), keratolytic therapy (55%), and placebo therapy (27%). Davidson and Schuler (10) related the effects of skin curettage on pedal verrucae. They reported a 92% success rate.

The aforementioned classical procedures for the treatment of plantar verrucae have yielded variable success rates. Variations occurred among different treatment modalities and, more importantly, among

Winner of the 1990 Scientific Abstract Award for best paper presented at the Forty-Eighth Annual Meeting of the American College of Foot Surgeons.

<sup>1</sup> Chief of Staff, Department of Podiatric Surgery; Director, Podiatric Surgery Residency Training, Medical Arts Center Hospital, New York, New York. Address correspondence to: 133 East 54th Street, New York, New York 10022.

<sup>2</sup> Diplomate, American Board of Podiatric Surgery. Section on Laser Surgery, American College of Foot Surgeons. Fellow, American Societies for Laser Medicine and Surgery, and International Society of Podiatric Laser Surgery.

0449/2544/91/3003-0238\$03.00/0

Copyright © 1991 by The American College of Foot Surgeons



studies using the same technique. These studies suffered from some shortcomings that no doubt contributed to this general inconsistency. Such shortcomings included a limited population and follow-up, and a variable lesion distribution. Additionally, the lack of any clearly defined lesion classification scheme affected the validity of their results.

More recent studies using the carbon dioxide laser have documented better and more consistent results. Mueller *et al.* (11), in 1980, and McBurney and Rosen (12), in 1985, reported 94.7% and 81% success rates, respectively, after a single treatment with carbon dioxide laser. Both researchers claimed 100% success after multiple treatments. Borovoy (13) reported an 85% success rate. Levary *et al.* (14) carried out a comprehensive study using criteria similar to those used by the authors. They documented an 84.8% success rate with a single treatment of a solitary lesion and a 52.5% success rate when treating multiple lesions. They further reported a 74% success rate when treating recalcitrant solitary lesions and a 55% success rate when treating recalcitrant multiple lesions.

## Materials and Methods

Five hundred and fifty patients were surveyed by questionnaire (Fig. 1). Patients participating in this study ranged in age from 6 to 68 years old, and were treated during the time frame of 1984–1989. The follow-up period ranged from 3 months to 6 years. A total of 166 patients responded to the questionnaire, which translated into 494 lesions. This quantity provided an adequate random sampling of the total clinical population.

Data from the questionnaire were correlated with the respective patient charts. The average postoperative clinical follow-up ranged from 3 to 5 months. Three months was found to be the usual period necessary to detect recurrence of lesions. Additionally, clinical follow-up ranged into years for those patients being treated for unrelated pedal pathology. Not all patients were called back for clinical evaluation.

The lesion population itself was divided into four categories: 1) solitary, 2) solitary recalcitrant, 3) multiple, and 4) multiple recalcitrant. A solitary lesion was defined as a single lesion, or three or less lesions on one foot in different anatomical locations. A multiple lesion was defined as a mosaic verruca of any size, or more than three solitary lesions in any anatomical distribution. A recalcitrant lesion was defined as any verruca that has failed to respond to any treatment prior to presentation.

Each of these categories was evaluated following a single (primary) treatment, or two to three (multiple) treatments. These two treatment variants in relation to

each of the four types of lesions resulted in a total of eight possible classifications for analysis and evaluation: solitary, solitary recalcitrant, multiple, and multiple recalcitrant lesions for both primary or multiple treatments (Table 1). Primary and multiple treatment success rates were added to give the ultimate success rates.

## Surgical Technique

A mixture of 0.5% bupivacaine plain and 1% lidocaine with epinephrine 1:100,000 was infiltrated under the cutaneous areas. The hyperkeratotic verrucous lesions were debrided superficially, and a specimen was sent to pathology for confirmation. A cessation of natural skin lines and thrombosed or actively bleeding capillaries were noted upon debridement. The peripheral boundaries were identified. The carbon dioxide laser was used. A power setting of 10 to 15 watts was chosen on a continuous mode. The laser beam was

Your Name _____		Name of Doctor _____	
Please circle appropriate response below			
1. Have your warts been treated by previous methods?			
YES		NO	
If so, by what method? _____			
2. How did laser treatment compare to other treatments?			
ABOUT THE SAME		BETTER WORSE	
3. Were you satisfied with carbon dioxide laser treatment?			
YES		NO	
4. Postoperative discomfort was:			
MINIMAL		MODERATE SIGNIFICANT	
5. Did any of the warts recur?			
YES		NO	
6. If any warts did recur:			
a. Did they recur at the same site?			
YES		NO	
If so, how many? _____			
b. Did any recur in different areas?			
If so, how many? _____			
7. If there was recurrence, how long after surgery?			
WEEKS		MONTHS YEARS	
8. If there was recurrence, were these warts re-treated?			
YES		NO	
9. If so, by which method?			
CHEMICAL		LASER ELECTROCAUTERY	
CURETTAGE		OTHER _____	
10. Was this other treatment successful?			
YES		NO	
Additional comments: _____			

**Figure 1.** Questionnaire sent to patients who underwent laser treatment for verruca plantaris.



TABLE 1. Plantar verruca lesions: classifications

PRIMARY Tx	MULTIPLE Tx
• Solitary	• Solitary
• Solitary Recalcitrant	• Solitary Recalcitrant
• Multiple	• Multiple
• Multiple Recalcitrant	• Multiple Recalcitrant

directed at the lesion guided by the visible helium-neon laser. A distance of 2 to 2.5 cm. allowed precise focus of the 1-mm. focal spot size. A peak power density of 1000 to 1500 watts/cm.<sup>2</sup> was attained. The lesion was circumscribed approximately 2 to 4 mm. larger than the actual size (Fig. 2A). Using a transverse sweeping motion, the epidermal layer of cells was vaporized with the laser (Fig. 2B). The resultant char was wiped with a saline-soaked gauze.

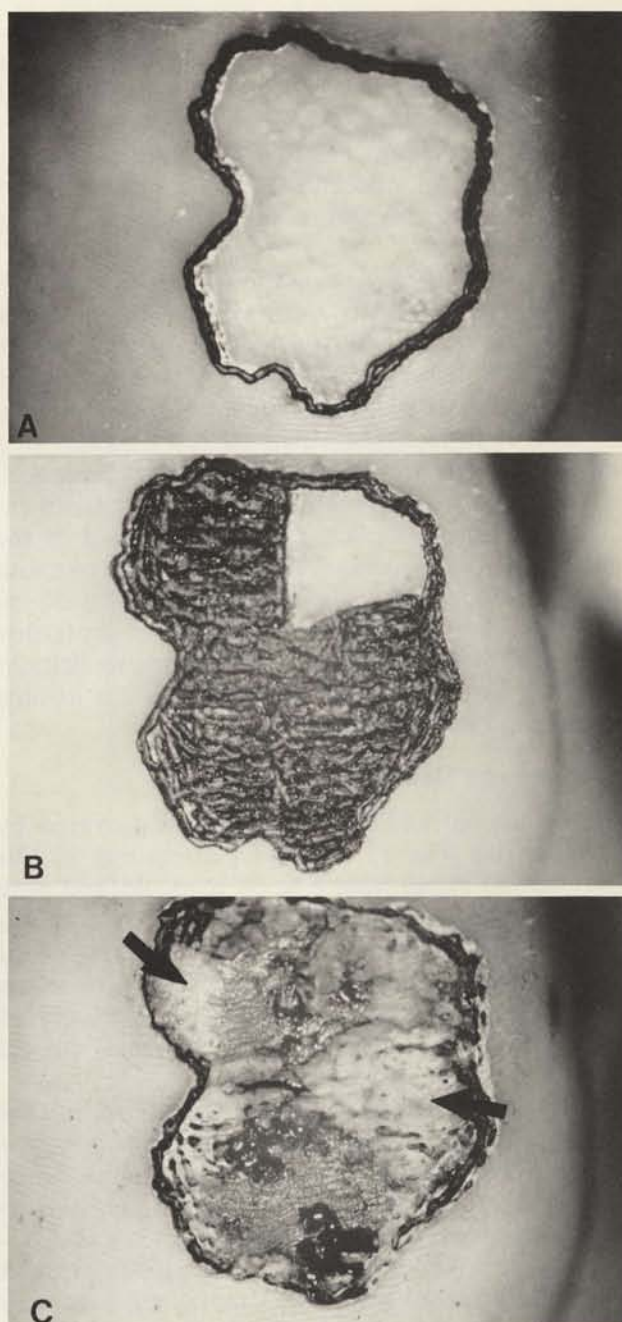
The surgical area was examined for evidence of verrucous tissue. The power was adjusted to control the depth of penetration depending on the appearance of the tissue being lased. The next layer of cells was lased following the same procedure (Fig. 2C). Any bleeding vessels were coagulated using a defocused beam, which causes heat coagulation. Layer by layer, the lesion was deepened and inspected until the area was found to be free of verrucous tissue.

Verrucous tissue responds to the laser vaporization by a bubbling or boiling effect (Fig. 3), whereas normal tissue shrinks or melts. Superficial lesions were sometimes free of pathologic tissue at the dermal-epidermal junction, while others had verrucous rete ridges that extended into the papillary and reticular dermis. Laser penetration was not to exceed the level of the superficial fascia. Once the area was found to be free of verrucous tissue, the entire area was exposed to a defocused laser beam. This caused heat coagulation and heat denaturation of the collagen bundles with a resultant contraction (shrinking up) of the wound.

The surgical areas were packed with an antibiotic ointment and Gelfoam.<sup>3</sup> A dry, sterile dressing was applied. The patient was allowed to bathe the area the following morning. Each patient was also instructed on local wound care, which consisted of daily dressing changes with Cortisporin<sup>4</sup> ointment and a cotton adhesive bandage. The patient was followed-up at the authors' office 1 week postoperatively and then every 2 to 3 weeks thereafter until full granulation was attained.

<sup>3</sup> Upjohn Company, Kalamazoo, Michigan.

<sup>4</sup> Burroughs Wellcome Company, Research Triangle Park, North Carolina.



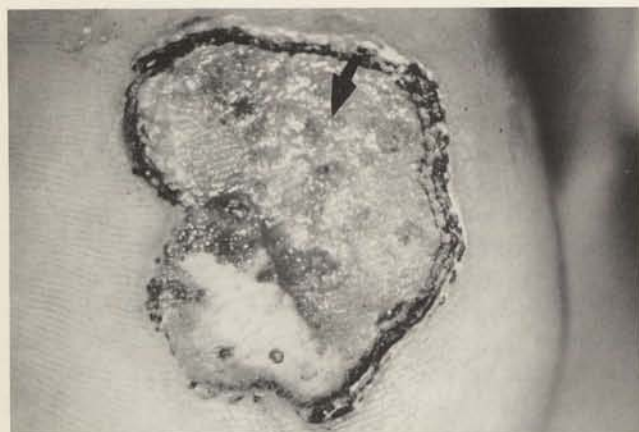**Figure 2.** A, the hyperkeratotic verrucous lesion is circumscribed approximately 3 mm. larger than the actual size. B, using a transverse sweeping motion, the epidermal layer of cells is vaporized (lased). C, the resultant char is removed with a saline-soaked gauze pad. The dermal-epidermal junction is now visible. Note the superficial epidermal layer still present medially and laterally (arrows).

## Results

All surgical areas were confirmed by pathology.

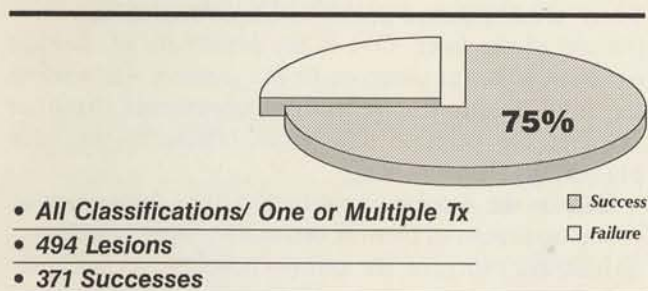
The treatment of pedal verrucae combining all classifications gave a 75% overall success rate (Table 2). When broken down into their respective categories





**Figure 3.** Note the bubbling effect (arrow) of the verrucous tissue still present.

**TABLE 2.** Total successes of CO<sub>2</sub> laser management of plantar verruca

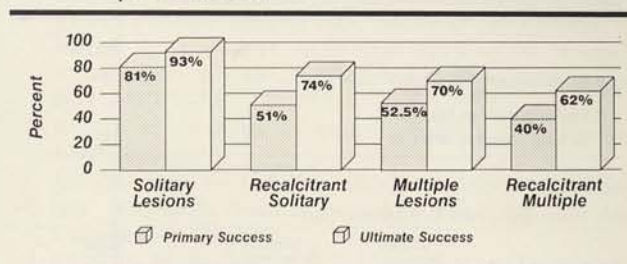


based on the classification scheme enunciated above, treatment of these pedal lesions provided the following results: The first-time treatment of solitary lesions resulted in an 81% success rate, while two or more treatments produced an additional 12%, giving a 93% ultimate success rate. Solitary recalcitrant lesions had a 51% success rate for first-time treatment *versus* a 74% ultimate success rate after multiple treatments. Multiple lesions had a 52.5% primary success rate *versus* a 70% ultimate success rate. Multiple recalcitrant lesions had a 40% primary success rate *versus* a 62% ultimate success rate (Tables 3 and 4).

### Complications

There were some complications encountered during the postoperative course of treatment. These included excessive bleeding (1.2%), sterile abscess (4.2%), infection of the soft tissue requiring antibiotics (1.2%), bone infection (0.6%), epidermoid inclusion cyst (1.2%), hyperkeratotic scar tissue (5.4%), and painful scar tissue (2.4%). Asymptomatic scar tissue was 90% (Table 5). Note that the preceding percentages are based not on the number of lesions treated but on the number of individual patients affected.

**TABLE 3.** Results by classification of CO<sub>2</sub> laser management of plantar verruca



**TABLE 4.** Comparison of the primary and ultimate successes of treatment

Variable	% Primary Success	% Ultimate Success	X <sup>2</sup>	P-value*
• Single Isolated Warts	81%	93%	8.32	< 0.01
• Single Warts, Previously Treated	51%	74%	10.79	< 0.01
• Multiple Isolated Warts	52.5%	70%	4.45	=0.035
• Multiple Warts, Previously Treated	40%	62%	13.78	< 0.001
• All Warts	57%	75%	35.70	< 0.001

\*Degree of Freedom = 1; Yate's Correction Factor.

The effect of multiple treatments yields a statistically significant increase in success for each type of condition tested ( $P < 0.05$ ).  
The ultimate success rate was always greater than that first noted.

**TABLE 5.** Complications (166 patients)

	# Pts.	Percent
• Excess Bleeding	2	1.2%
• Sterile Abscess	7	4.2%
• Infection Soft Tissue (requiring antibiotics)	2	1.2%
• Infection (osteo)	1	0.6%
• Epidermoid Inclusion Cyst	2	1.2%
• Painful Scar Tissue	4	2.4%
• Hyperkeratotic Scar Tissue	9	5.4%
• Asymptomatic Scar Tissue	149	90%

Miscellaneous results: spontaneous remission, 2%; development of new lesions following treatment (predominantly peripheral to the surgical area), 28%; time span for recurrence of lesions within 4 weeks, 13.5%; within 12 months, 31%; greater than 12 months, 7% (Table 6). It was calculated, through review of the respective patient charts, that 3 months was the period of time necessary to note recurrences among over 90% of the patients who responded by affirming recurrence within months of the surgical laser procedure.

The chi-square test was used for testing the equality of proportions. Data was corrected for continuity using the Yates correction factor. A level of significance of  $p$ , where the value was always less than 0.05, was attained. All results were found to be clinically significant (Table 4).



TABLE 6. Miscellaneous results (166 patients)

	# Pts.	Percent
• Spontaneous Remission	3	2%
• Development of Lesions in New Location After Tx	46	28%
<i>predominantly peripheral</i>		
• Recurrence/ New Occurrence Time		
	<u>Weeks</u>	<u>Months</u>
	13.5%	31%
		<u>Years</u>
		7%
• Pain (subjective)		
	<u>Min.</u>	<u>Mod.</u>
	51%	32%
		<u>Sig.</u>
		17%

## Discussion

The authors have found laser surgery to be a viable alternative to traditional techniques for the treatment of plantar verrucae. Success rate was dependent on the number of lesions and prior history of treatment. The range of success was between 40% and 93%. The data clearly indicate that the highest success rate was accomplished with solitary untreated verrucae, and the lowest success rate was with multiple recalcitrant verrucae.

The authors have also found that in order to prevent or minimize recurrence of lesions, the surgical area should extend to the reticular dermis and should be 3 to 4 mm. larger than the visible verrucous margin. Extending the surgical level down to the reticular dermis did not cause a problem with hypertrophic scar formation. Although the majority of the patient population did form scar tissue, 90% of the areas were mild and asymptomatic. Only 2.4%, or 4 out of 166 patients, developed symptomatic plantar scar tissue (Table 5). Lemont and Parekh (15) proposed that the superficial fascia should be the deep anatomical boundary to assure the elimination of the verruca and minimize scar tissue formation.

Additionally, the piezoelectric properties of collagen may aid in the limitation of scar tissue, *i.e.*, pressure applied to the plantar wound would aid in the organized alignment of healing collagen fibers (16). For this reason, a weight-dispersion bandage was not used in order to facilitate weightbearing pressure. Also noted was a 28% peripheral recurrence following treatment. That is to say, new lesions were found to develop within 2 to 3 mm. of the surgical border. The authors surmise that this could be related to immune deficiency, subepidermal occult verruca (17), peripheral seeding from the laser plume (18, 19), or latent papillomavirus (20). A 3- to 4-mm. enlargement of the surgical border therefore was established in order to reduce the possibility of peripheral recurrence.

On a subjective basis through use of the questionnaire, respondents indicated that the laser offered min-

imal discomfort (no patient required postoperative medication for pain) (Table 6). Laser treatment was also found to result in minimal postoperative complications. Other advantages include: Accurate control of the laser beam, allowing the surgeon to control precisely the depth and periphery of the surgical site; rapid ablation of the verrucous lesion; intraoperative hemostasis, since the laser can cauterize vessels. This alleviates the need for postoperative compression dressings; minimal necrosis of adjacent tissue, since the beam affects well-defined areas of the skin. Consequently, postoperative pain, edema, and scarring are minimized; and laser sterilization of the surgical site, since the laser vaporizes bacteria, viruses, fungi, etc., as well as human tissue (11).

Disadvantages of laser surgery include the high cost of instrumentation, its inability to function in the presence of a wet field, and the possibility of laser burn. There are also some potential hazards attendant with the use of the laser. One is the possibility of damage either to adjacent tissue or to the surgeon when using the laser beam near reflective instruments. Another involves the possible deleterious effects of the laser plume (18, 19).

Despite the success rate this study has demonstrated in the treatment of plantar verruca by means of carbon dioxide laser surgery, the authors nevertheless feel compelled to state that laser surgery does not by itself guarantee a high success rate. Familiarity with intracutaneous anatomy and technical expertise are also essential prerequisites for an effective outcome.

## Conclusion

This study has endeavored to break new ground in the area of carbon dioxide laser vaporization and its success rate in treating specific classes of verrucous lesions. A 6-year period of time allowed for an adequate random sampling and substantial data to be generated, all of which were found to be clinically significant. The results indicate that certain types of lesions have a significantly higher success rate than other types, allowing for greater clinical insight into the effectiveness of the technique in specific cases.

The overall success rate, considering all eight treatment categories, was 75%. Ultimate success rates ranged from 93% for solitary lesions to 62% for multiple recalcitrant lesions. The authors' findings show clinical significance in the marked differentiation of success rates in accordance with the classification scheme. That is to say, initial treatment of a solitary lesion showed a higher success rate than initial treatment of multiple lesions, and initial treatment of virgin lesions showed a higher success rate than initial treat-



ment of recalcitrant lesions. Based on the data accumulated, the authors therefore propose that treatment of plantar verruca be initiated early, *i.e.*, while the lesion is solitary and has been heretofore untreated. On the other hand, those lesions having a second or third treatment *via* carbon dioxide laser vaporization were found to result in a higher ultimate success rate than those which had only one primary treatment.

The general conclusion is that carbon dioxide laser management should be considered as a viable treatment alternative in relation to other, more traditional, techniques for the treatment of plantar verruca. Finally, the study's results are reproducible as well as consistent with the high success rates published by previous researchers. Considering the range of practical application and the clinical significance of the results, carbon dioxide laser vaporization should be viewed as a valuable component in the practitioner's armamentarium with respect to the treatment of verruca plantaris.

#### References

1. Ross, M. S. Warts in the medical folklore of Europe. *Intern. J. Dermatol.* 18:505, 1979.
2. Sollitto, R. J., Napoli, R. C., Gazivoda, P. L., Hart, T. J. A perspective study using bleomycin sulfate in the treatment of plantar verrucae. *J. Foot Surg.* 28:141, 1989.
3. Limmer, B. L., Bogy, L. T. Cryosurgery of plantar warts. *J. A. P. M. A.* 69:713, 1979.
4. Steele, K., Shirodaria, P., O'Hare, M., Merrett, J. D., Irwin, W. G., Simpson, D. I. H., Pfister, H. Monochloroacetic acid and 60% salicylic acid as treatment for simple plantar warts: effectiveness and mode of actions. *Br. J. Dermatol.* 118:537, 1988.
5. Delacerde, F. G. Ultrasonic techniques for treatment of plantar warts in athletes. *J. Orthop. Sports Ther.* 2:100, 1979.
6. Vance, J. C., Bart, B. J., Hansen, R. C., Reichman, R. C., McEwen, C., Hatch, K. D. Intralesional recombinant alpha-2 interferon for the treatment of patients with condyloma acuminatum or verruca plantaris. *Arch. Dermatol.* 122:272, 1986.
7. Hughes, E., Marshall, H., Mehlmauer, M., Koch, M., Whitaker, K., Weinstein, R. Human warts permanently removed by static electricity. *Cutis* 31:319, 1983.
8. Israel, R. M. Treatment of warts by vaccination. *Arch. Dermatol.* 100:222, 1969.
9. Horwitz, O., Marker, T. The efficacy of electrocaustic, keratolytic, and placebo treatment in patients with single warts. *Dermatologica* 40:127, 1960.
10. Davidson, M. R., Schuler, B. S. Skin curette and the treatment of plantar verrucae. *J. A. P. M. A.* 66:331, 1976.
11. Mueller, T. J., Carlson, B. A., Lindy, M. P. The use of the carbon dioxide surgical laser for the treatment of verrucae. *J. A. P. M. A.* 70:136, 1980.
12. McBurney, E. I., Rosen, D. Carbon dioxide laser treatment of verrucae vulgares. *J. Dermatol. Surg. Oncol.* 10:45, 1984.
13. Borovoy, M. The treatment of verrucae vulgaris with carbon dioxide laser surgery. *Clin. Podiatr Med. Surg.* 4(4): 749-807, 1987.
14. Levary, L., Cutler, J. M., Galinski, A. W., Gastwirth, B. W. The efficacy of laser surgery for verruca plantaris: report of a study. *Clin. Podiatr Med. Surg.* 5(2):377-382, 1988.
15. Lemont, H., Parekh, V. Superficial fascia—an appropriate anatomic boundary for excising warts on the foot. *J. Dermatol. Surg. Oncol.* 15:7, 1989.
16. Price, H. Connective tissue in wound healing. In *Wound Healing: Alternative in Management*, pp. 39-41, edited by L. C. Kloth, J. M. McCulloch, J. A. Feedar, F. A. Davis, Philadelphia, 1990.
17. Laffitte, F., Chavoin, J. P., Bonafe, J. L., Costaglidia, M. Under heel foot wart. *Dermatologica* 171:206, 1985.
18. Garden, J. M., O'Banion, K. O., Shelnitz, L. S., Pinski, K. S., Bakus, A. D., Reichmann, M. E., Sundberg, J. P. Papillomavirus in vapor of carbon dioxide laser treated verrucae. *J. A. M. A.* 259:1199, 1988.
19. Sawchuck, W. S., Weber, P. J., Lowy, D. R., Dzubow, L. M. Infectious papillomavirus in the vapor of warts treated with carbon dioxide laser or electrocoagulation detection and protection. *J. Am. Acad. Dermatol.* 21:41, 1989.
20. Ferenczy, A., Mitao, M., Nagai, N. Latent papillomavirus and recurring genital warts. *N. Engl. J. Med.* 313:784, 1985.