

Accessory Ossicle of the Lateral Malleolus

The authors present a case history of a patient with chronic lateral ankle pain and instability secondary to an accessory ossicle of the fibula. Conservative therapy failed to alleviate the patient's symptoms, therefore surgical management was indicated. The ossicle was excised, and a modified, double-ligament lateral ankle stabilization procedure was performed. At 12-months follow-up, the patient is symptom-free.

John E. Mancuso, DPM, FACFS^{1,2}
Paul W. Hutchison, DPM

Steven P. Abramow, DPM, FACFS³
Mark J. Landsman, DPM

Literature Review

According to Tachdjian (1), the accessory ossicle of the lateral malleolus, also known as os subfibulare, has been reported in 1% of the population. A separate center of ossification first appears between the ages of 7 and 10 years. It usually fuses to the malleolus between the ages of 15 and 17 years (2). When fusion occurs, the main body of the lateral malleolus appears larger than normal. Occasionally, fusion with the main body does not occur, and junction of the ossicle occurs by fibrous, cartilaginous, or synovial-lined articulations.

Radiographically, the lateral malleolus has been shown to have two different areas where an apophysis can be found. The most frequently seen apophysis is located anterior to the malleolus and is oval in shape. The other is located distal to the malleolus and is smaller in size (3). The ossification center has smooth borders. However, when the ossification is incomplete or irregular, it can resemble a fracture (2, 3). In questionable cases, radiographic evaluation of the contralateral limb should be performed. According to Turek (4), the ossicle is most commonly found bilaterally. Other studies to be considered are ⁹⁹Tc bone scans, stress views, and computerized tomography scans to aid in making the proper diagnosis and help determine the course of treatment.

Symptoms of pain and instability can be initiated following a minor traumatic episode, usually an inversion injury. They are even possible with no history of trauma (2, 3, 5, 6). Trauma can lead to a rupture of the fibrous or cartilaginous attachments of the ossicle to

the lateral malleolus, resulting in a painful pseudoarthrosis (2).

Clinical examination is extremely important in making the proper diagnosis. All too often, a misdiagnosis of fracture is made and the patient is treated with a below-the-knee cast for 6 weeks. Pinpoint pain is elicited on palpation immediately anterior to the lateral malleolus. Edema and ecchymosis may or may not be present.

Various conservative treatment regimens have been attempted. These consist of immobilization for 3 to 6 weeks, corticosteroid injection therapy, orthoses, and various ankle supports. If conservative treatment is unsuccessful, the procedure of choice is resection of the ossicle with primary repair of the anterior talofibular ligament.

Case History

A 38-year-old female first presented to the authors' office in 1986, complaining of pain and instability of the left ankle. She had a history of chronic low-grade ankle sprains. The patient described the pain as a dull ache, occasionally radiating up the lateral aspect of the leg, and increasing in severity upon activity. The patient's medical history was unremarkable and she has no known drug allergies.

Physical examination revealed mild edema surrounding the lateral malleolus. No erythema or ecchymosis were noted. Pain was elicited on palpation anterodistal to the lateral malleolus at the talofibular joint. Increased inversion range of motion was noted when compared to the contralateral ankle, as well as pain on forced inversion of the pathologic ankle.

Radiographic evaluation revealed an ossicle anterior to the lateral malleolus. The borders were smooth and well demarcated. A noticeable depression within the talus was observed, indicating a possible articulating surface with the ossicle (Fig. 1).

During the period from 1986 through 1989, various

¹ Address correspondence to: 133 East 54th Street, New York, NY 10022.

² Diplomate, American Board of Podiatric Surgery; Chief-of-Staff, Department of Podiatric Surgery; Director, Podiatric Residency Training, Medical Arts Center Hospital, New York, New York.

³ Diplomate, American Board of Podiatric Surgery.

0449/2544/91/3001-0052\$03.00/0

Copyright © 1991 by The American College of Foot Surgeons

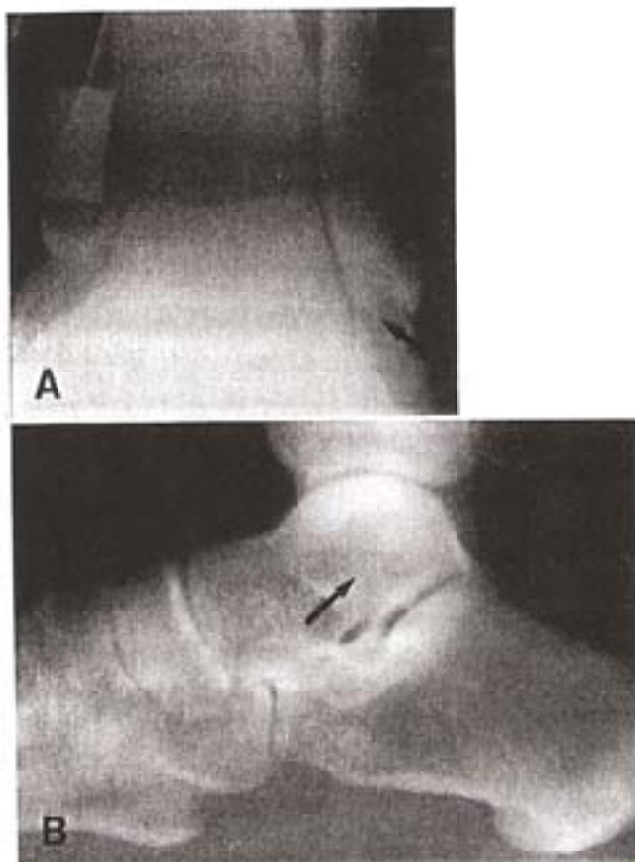


Figure 1. A, mortise view of the ankle. Arrow indicates the accessory ossicle. B, lateral view of the ankle. Arrow indicates the accessory ossicle.

conservative treatment modalities were implemented, including immobilization, oral anti-inflammatory medications, ultrasound, and corticosteroid injections. These various treatment modalities failed to give the patient satisfactory relief. She therefore opted for surgical management.

Further radiographic studies were necessary to assess the position of the ossicle and the integrity of the lateral collateral ligaments. Stress views revealed that both the anterior talofibular ligament and the calcaneofibular ligament were disrupted. Anterior draw test revealed 5 mm. of anterior displacement of the talus out of the mortise on the pathologic side, as compared to 2 mm. of displacement on the contralateral side. A 14° talar tilt was measured in the pathologic ankle compared to 4° in the normal ankle (4). Normal values for these tests are 1 to 2 mm. anterior displacement, not to exceed 4 mm., and a controversial 5° to 23° of talar tilt (7, 8). Computerized tomographic scans revealed a syndesmotomic attachment of the ossicle to the fibula. An articulating surface with the talus was also noted (Fig. 2).

The surgical plan was to excise the ossicle and assess

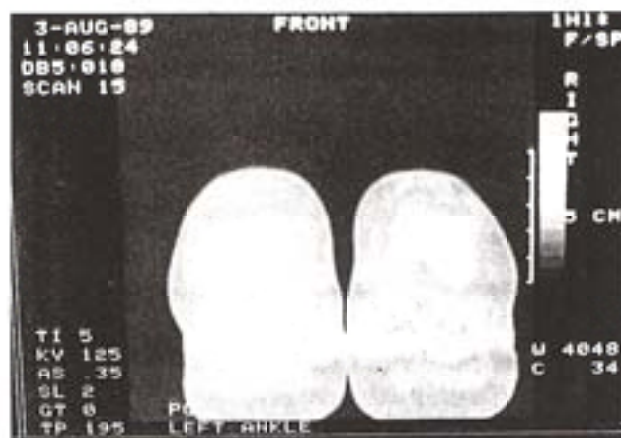

Figure 2. Computerized tomographic scan, revealing ossicle articulating with the lateral aspect of the talus.

ligamentous integrity intraoperatively. If the ligaments were found to be intact but stretched, shortening procedures with primary repair would be implemented. However, if primary repair were not possible, a lateral ankle stabilization procedure would be performed.

Surgical Procedure

A 20-cm. hockey stick incision was made paralleling the peroneal tendons, extending from the lower one third of the leg to the insertion of the peroneus brevis tendon. This incision was used in anticipation of performing a lateral ankle stabilization procedure. The incision was deepened, adhering to strict anatomical dissection. The ossicle was identified at the anteromedial aspect of the lateral malleolus and found to be freely movable. Other important intraoperative findings were: 1) an articulating surface between the ossicle and the talus; 2) the anterior talofibular ligament inserted into the ossicle only and had no attachment to the malleolus (Fig. 3); and 3) following excision of the ossicle, the anterior talofibular ligament was found to be too short to reanastomose with the malleolus (Fig. 4). Since physiologic repair was not possible, a modified split peroneus brevis double-ligament, lateral ankle stabilization procedure was performed.

Postoperative Treatment

Postoperatively, the patient was placed in a below-the-knee nonweightbearing cast for 6 weeks. Following cast removal, the patient was placed on a vigorous physical therapy program to regain subtalar and ankle joint range of motion and to increase strength of the

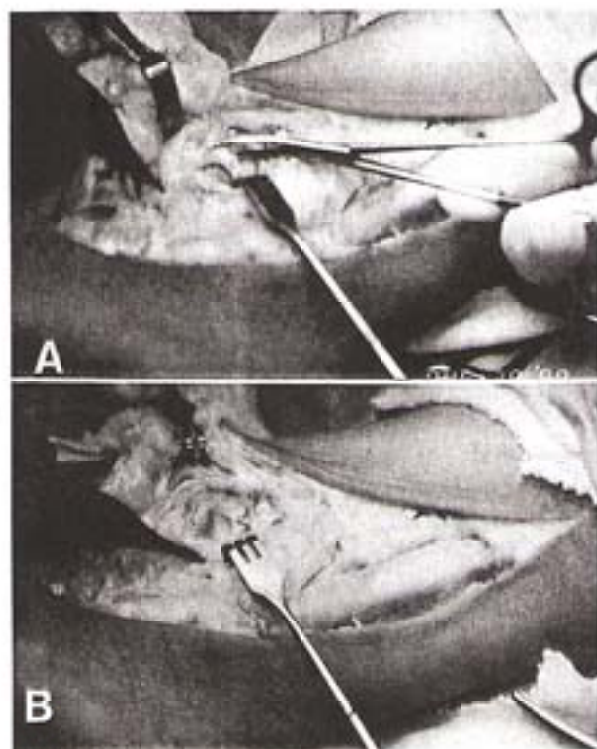


Figure 3. A, ossicle is within hemostat. Only the anterior talofibular ligament inserts into the ossicle. No attachment to the lateral malleolus is noted. B, excision of ossicle reveals an articulating surface with the talus, as well as an erosive surface of the talus.

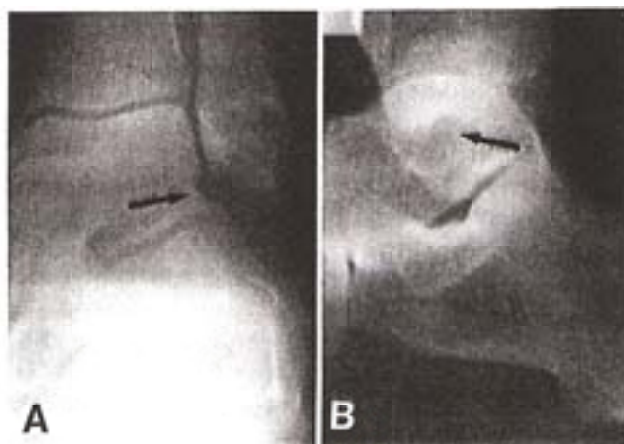


Figure 4. A, postoperative mortise view of the ankle. Arrow indicates absence of ossicle with an erosive lesion in the talus. B, postoperative lateral view. Arrow indicates absence of ossicle.

peronei. At 12 months, the patient was without pain and with good range of motion in the subtalar and ankle joints when compared to the contralateral limb. She is back to full activity and is wearing all types of

shoes, including sneakers, flat dress shoes, and pumps with 2-inch heels.

Discussion

There are many etiologies of ankle pain and instability. When evaluating an ankle, the practitioner must rule out ankle sprain, fracture, accessory ossicle, and systemic inflammatory disease. The case presented here exhibits a patient with a history of chronic lateral ankle pain and instability. Standard radiographs can be evaluated to differentiate an accessory ossicle from an avulsion fracture. The ossicle is round to oval in shape, with smooth, well-demarcated cortical margins. The accessory ossicle is often bilateral. Hence, contralateral radiographs can be useful when making the diagnosis. Adjunct radiographic studies can be performed as well, including computerized tomographic scans and stress views, to assess ligamentous integrity.

Conservative therapy should be the first mode of treatment. Various modalities are available in any medical armamentarium, such as immobilization, oral anti-inflammatory medications, corticosteroid injections, ultrasound, physical therapy, and external braces for support. If conservative treatment fails to alleviate the patient's symptoms, then surgical intervention is indicated.

During surgery, proper anatomical dissection and evaluation is essential. In the case presented, significant intraoperative findings included the following: 1) the anterior talofibular ligament attached directly to the ossicle with no attachments to the malleolus, and 2) the ossicle articulated with the talus and had a fibrous attachment to the malleolus. After excision of the ossicle, the anterior talofibular ligament was found to be too short for primary anastomosis to the malleolus. The calcaneofibular ligament was observed to be stretched and very thin, to the extent that primary shortening procedures were doubtful as effective remedies. Since physiologic repair of the ligaments was not possible, a modified double-ligament lateral ankle stabilization procedure was performed using a split peroneus brevis tendon graft.

Conclusion

Surgical excision and lateral ankle stabilization produced an excellent result in this case presentation. Surgery is not always the treatment of choice. However, when a recalcitrant condition exists, surgical management of the problem can and does produce satisfactory results.

References

1. Tachdjian, M. O. *Pediatric Orthopedics*, p. 1270, W. B. Saunders, Philadelphia, 1972.

2. Griffiths, J. D., Menelaus, M. B. Symptomatic ossicles of the lateral malleolus in children. *J. Bone Joint Surg.* 69B:317-319, 1987.
3. Goedhead, G. The apophyses of the lateral malleolus. *Radiol. Clin. Biol.* 39:330-331, 1970.
4. Turek, S. L. *Orthopedics: Principles and Their Application*, 4th ed., pp. 1477-1479, J. B. Lippincott, Philadelphia, 1984.
5. Bowles, T. H., Korman, S. F., Desilvio, M., Climo, R., Accessory os fibulare avulsion secondary to the inversion ankle injury. *J. A. P. A.* 70:302-303, 1980.
6. Bjornson, R. G. Developmental anomaly of the lateral malleolus simulating fracture. *J. Bone Joint Surg.* 38A:128-130, 1956.
7. Downing, J. W., Oloff, L. M., Jacobs, A. M. Radiologic diagnosis and assessment of lateral ankle ligamentous injuries. *J. Foot Surg.* 18:135-145, 1979.
8. Visser, H. J., Oloff, L. M., Jacobs, A. M. Lateral ankle stabilization procedures: criteria and classification. *J. Foot Surg.* 19:74-83, 1980.

Additional References

- Fairbank, H. A. T. A separate centre of ossification for the tip of the internal malleolus. *Arch. Radiol. Electrother.* 27:238-241, 1923.
- Kelikian, H., Kelikian, A. S. *Disorders of the Ankle*, pp. 282-283, W. B. Saunders, Philadelphia, 1985.
- Klein, S. N., Oloff, L. M., Jacobs, A. M. Functional and surgical anatomy of the lateral ankle. *J. Foot Surg.* 20:170-175, 1981.
- Kushel, S. W., Rampino, R. D., Oloff, L. M., Jacobs, A. M. A review of conservative and surgical treatment of acute rupture of the lateral collateral ligaments of the ankle. *J. Foot Surg.* 18:149-152, 1979.
- Montagne, J., Chevrot, A., Galmiche, J. M. *Atlas of Foot Radiology*, p. 24, Mason Publishing, New York, 1981.
- Powell, H. D. W. Extra centre of ossification for the medial malleolus in children. *J. Bone Joint Surg.* 43B:107-113, 1961.
- Tachdjian, M. O. *The Child's Foot*, p. 128, W. B. Saunders, Philadelphia, 1985.