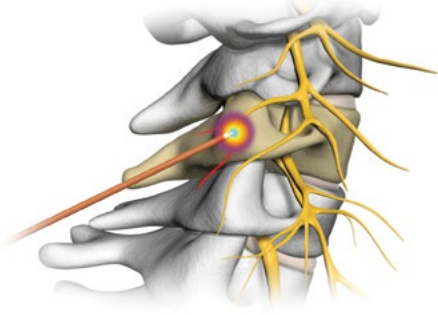
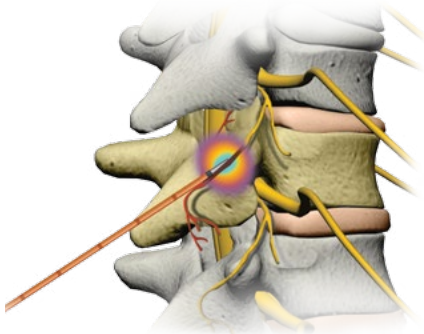


# SPINE ANATOMY

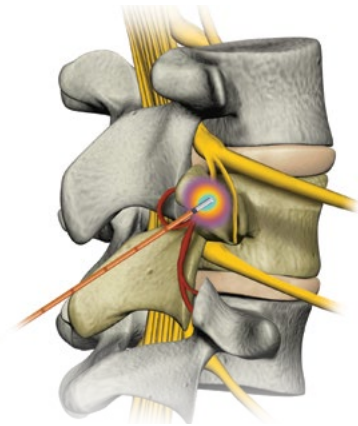
## COOLIEF\* Cervical Lesioning



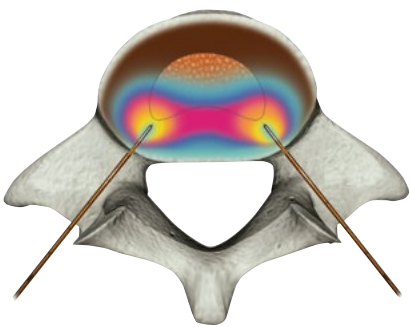
## COOLIEF\* Thoracic Lesioning



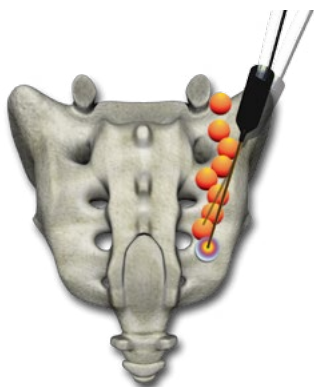
## COOLIEF\* Lumbar Lesioning



## COOLIEF\* Intervertebral Disc Biacuplasty



## COOLIEF\* Sacroiliac Lesioning (used in treatment of SIJ syndrome)



## CERVICAL VERTEBRAE

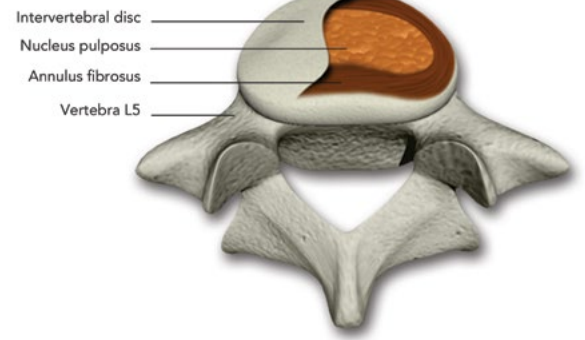
## THORACIC VERTEBRAE

## LUMBAR VERTEBRAE

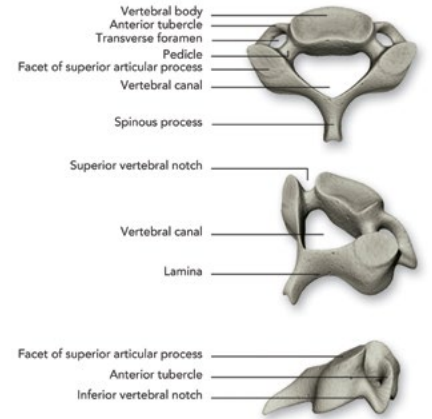
## SACRUM

## COCCYX

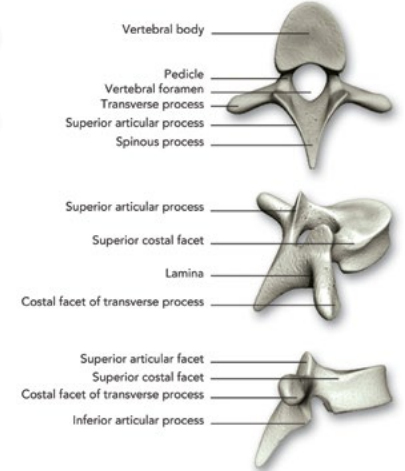
## Intervertebral Disc



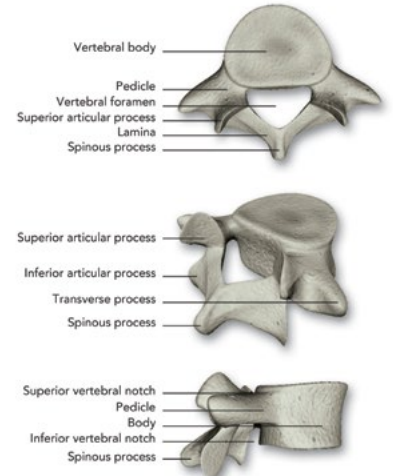
## Fourth Cervical Vertebrae



## Fifth Thoracic Vertebrae



## Fifth Lumbar Vertebrae



## Sacrum and Coccyx

