

A SUPPLEMENT TO

# cosmetic DERMATOLOGY®

February 2005 Volume 18 No. 2 S2



## NEW OPTIONS

in the Recognition and Treatment  
of Lipoatrophy With Volume  
Restoration

# Foreword

## New Options in the Recognition and Treatment of Lipoatrophy With Volume Restoration

Facial lipoatrophy is best known for its association with human immunodeficiency virus infection. However, it is also seen as a natural part of the aging process. In addition, patients with certain types of cancer and type-2 diabetes mellitus often experience this condition. Effective treatment of patients with facial lipoatrophy provides a broad range of individuals with psychological relief and an improved self-image.

The articles in this supplement summarize information from a symposium entitled "New Options in the Recognition and Treatment of Lipoatrophy With Volume Restoration," which was presented during the 3rd Annual Meeting and Exhibition of the American Society of Cosmetic Dermatology & Aesthetic Surgery in Phoenix, Arizona, December 2-4, 2004. The process of assessing patients with facial lipoatrophy is presented, and the concept of nonsurgical total facial restoration as a strategy for managing this condition is introduced. An overview of appropriate treatment options, with emphasis on the results of clinical trials with injectable poly-L-lactic acid (Sculptra™), is presented. We hope this information is helpful to our colleagues in the field of aesthetic dermatology.

Wm. Philip Werschler, MD  
Section Chief of Dermatology  
Sacred Heart Medical Center  
Spokane, Washington  
Assistant Clinical Professor  
University of Washington  
Seattle

Douglas R. Mest, MD  
Clinical Director  
Blue Pacific Aesthetic Medical Group  
Hermosa Beach, California

# Experience With Injectable Poly-L-Lactic Acid in Clinical Practice

Douglas R. Mest, MD

*The initial response to poly-L-lactic acid (Sculptra™) is related to a mechanical volume effect that lasts up to one week followed by a delayed effect secondary to collagen synthesis. The effects of poly-L-lactic acid can persist for as long as 2 years but are not permanent, and patients may require additional treatment.*

In 2004, the US Food and Drug Administration approved injectable poly-L-lactic acid (Sculptra™) for correction of lipoatrophy in individuals with human immunodeficiency virus (HIV) infection. Poly-L-lactic acid is the first drug to receive this indication in the United States, though it has been approved for use in Europe since 1999 for soft tissue augmentation and correction of wrinkles. This article summarizes the clinical trial experience with injectable poly-L-lactic acid and its acceptability among physicians and patients.

## PHARMACODYNAMICS

Poly-L-lactic acid is a biocompatible, biodegradable, synthetic polymer derived from vegetable sources. It does not act as a dermal filler. The initial response is related to a mechanical volume effect that lasts up to one week followed by a delayed effect in which there is an increase in fibroblasts and collagen production. Poly-L-lactic acid is eventually degraded and undergoes resorption.<sup>1</sup>

## EFFICACY

In a study evaluating the efficacy of injectable poly-L-lactic acid in patients with HIV infection and

severe facial lipoatrophy (N=50), initial treatment consisted of 4 sets of injections of poly-L-lactic acid (one vial per cheek) at baseline and every 2 weeks thereafter for 6 weeks.<sup>2</sup> Median total cutaneous thickness increased ( $P<.001$ ) from baseline where median facial fat thickness was set at 0 (range, 0.0–2.1 mm). Total cutaneous thickness increased 5.1 mm (range, 2.2–8.6 mm) at week 6, 6.4 mm (range, 3.1–9.1 mm) at week 24, 7.2 mm (range, 4.2–9.6 mm) at week 48, 7.2 mm (range, 3.5–9.6 mm) at week 72, and 6.8 mm (range, 3.9–10.1 mm) at week 96 (Figure 1).<sup>2</sup>

## IMMEDIATE VERSUS DELAYED-TREATMENT RESPONSE

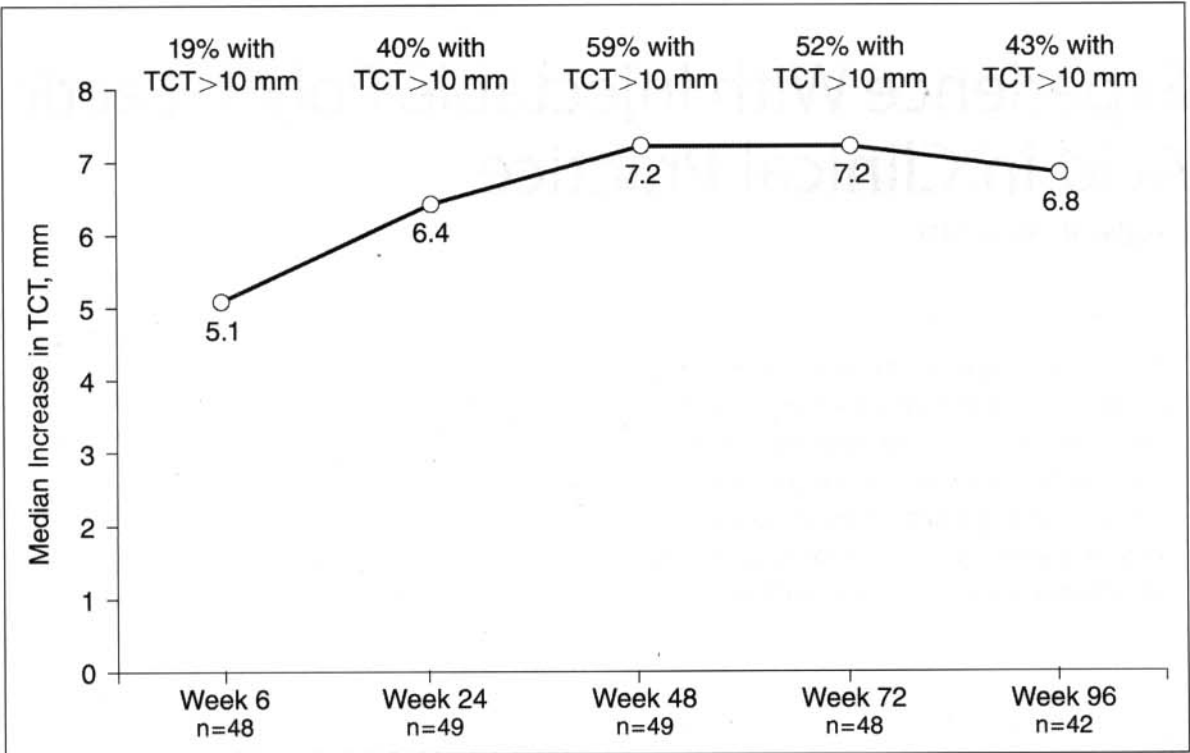
In a 24-week study of patients with HIV infection and facial lipoatrophy (N=30), the temporal association between treatment and outcomes was evaluated.<sup>3</sup> Patients randomized to immediate treatment (n=15) received one vial of injectable poly-L-lactic acid bilaterally into the deep dermis overlying the buccal fat-pad at baseline, 2 weeks, and 4 weeks. Patients in the delayed-treatment group (n=15) received injections on weeks 12, 14, and 16. Median age was 41 years, with a mean of 80 months of nucleoside reverse transcriptase inhibitor therapy and 44 months of prior protease inhibitor therapy. Median CD4 count was 428 to 460 cells/ $\mu$ L; 47% (7) of patients in the immediate-treatment group and 93% (14) of patients in the delayed-treatment group had fewer than 50 HIV-1 RNA copies/mL at baseline.<sup>3</sup>

Patient visual analogue assessments (graded on a 10-point scale where 0=thin as ever and 10=not at all thin), photographic assessments, and anxiety and depression scores improved with treatment. At week 12, patients in the immediate-treatment group had better visual analogue scores and lower anxiety scores than patients in the delayed-treatment group (7 vs 1 [ $P<.001$ ] and 6 vs 9 [ $P=.056$ ], respectively). The benefits measured on the visual analogue scale and Hospital Anxiety and Depression Scale persisted through week 24.<sup>3</sup>

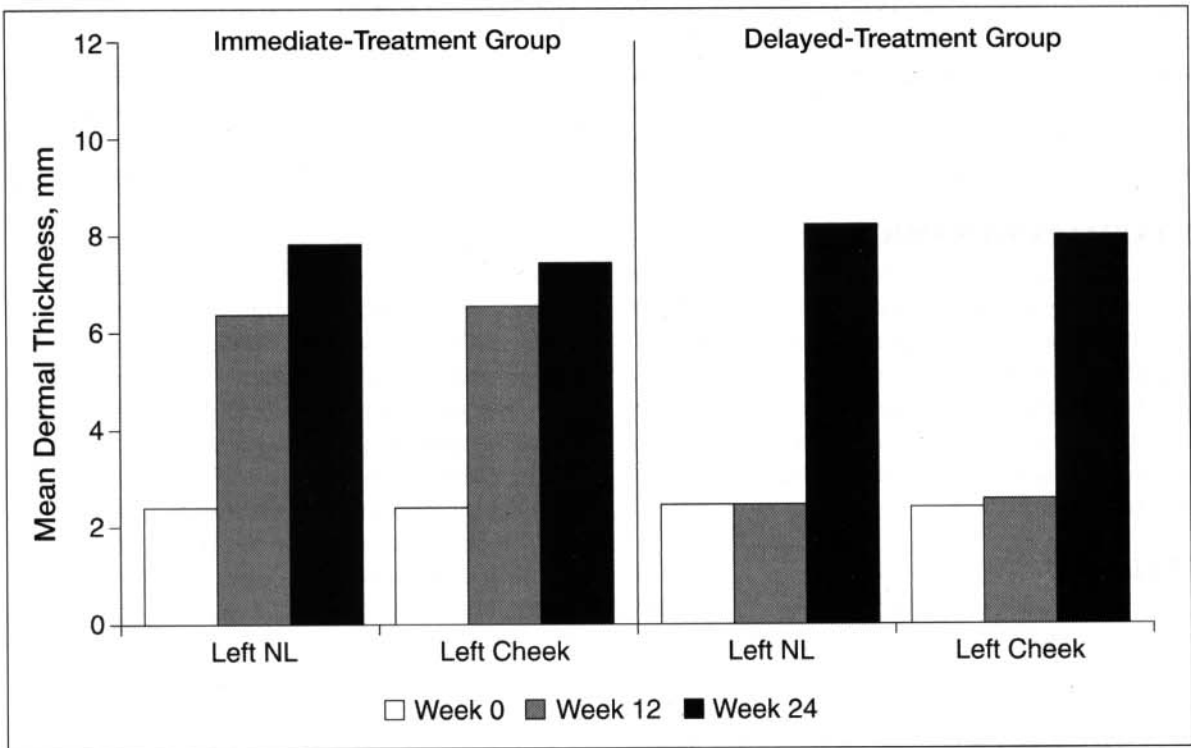
Dr. Mest is Clinical Director, Blue Pacific Aesthetic Medical Group, Hermosa Beach, California.

Dr. Mest is a consultant for Dermik Aesthetics and has received a research grant from Aventis Pharmaceuticals Inc.





**Figure 1.** Evolution of total cutaneous thickness as measured by ultrasonography during poly-L-lactic acid treatment of patients with HIV infection and severe facial lipoatrophy (N=50). Changes from baseline were statistically significant ( $P<.001$ ) at each evaluation period. TCT indicates total cutaneous thickness. Adapted with permission from Valantin MA, Aubron-Olivier C, Ghosn J, et al. Poly-L-lactic acid implants (New-Fill) to correct facial lipoatrophy in HIV-infected patients: results of the open-label study VEGA. *AIDS*. 2003;17:2471-2477.<sup>2</sup>



**Figure 2.** Ultrasound studies demonstrated increases in mean dermal thickness. Differences in mean dermal thickness were significant ( $P=.001$ ) between groups at week 12. No significant variations in mean dermal thickness were observed between groups at week 24. NL indicates nasolabial fold. Adapted from Moyle et al.<sup>3</sup>

## Poly-L-Lactic Acid Treatment–Related Adverse Events\*

Adverse Event	Valantin et al <sup>2</sup> (N=50)	Moyle et al <sup>3</sup> (n=29) <sup>†</sup>	Average Duration <sup>‡</sup>
Injection procedure related, n (%)			
Bruising	3 (6)	11 (38)	6 d
Edema	2 (4)	2 (7)	3 d
Discomfort	0	3 (10)	3 d
Hematoma	14 (28)	0	17 d
Inflammation	0	3 (10)	3 d
Erythema	0	3 (10)	3 d
Device related, n (%)			
Injection site subcutaneous papule <sup>§</sup>	26 (52)	9 (31)	7-mo onset <sup>  </sup>

\*Follow-up period was 2 years.

<sup>†</sup>Safety data were collected post hoc for 27 of the patients at approximately 2 years from study start.

<sup>‡</sup>Duration and onset data are available from Valantin et al<sup>2</sup> only.

<sup>§</sup>Subcutaneous papules refer to lesions of 5 mm or less, typically palpable, asymptomatic, and nonvisible.

<sup>||</sup>Duration was not noted for subcutaneous papules because most were ongoing at study completion.

A mean increase in dermal thickness of 4 mm (range, 4–6 mm) was noted at week 12 in the cheek and nasolabial regions of patients in the immediate-treatment group, but only a slight increase was noted in patients in the delayed-treatment group (Figure 2). Differences in dermal thickness were significant ( $P=.001$ ) between groups at week 12 but not at week 24.<sup>3</sup>

## TOLERABILITY

Tolerability of injectable poly-L-lactic acid has been reported in a study of 300 patients (aged 45–64 years; 70% women; 3% with HIV-related facial lipoatrophy) with various soft tissue defects. There were 819 areas treated, such as nasolabial folds, Marionette lines, labiomental creases, upper lip (cutaneous portion), cheeks, chin, and temples.<sup>4</sup> Bruising, erythema, and slight swelling occurred frequently at the injection site for a few days. Development of subcutaneous

papules ranged from less than 1% to 10% and appeared to be relevant to the method of drug reconstitution. The Table lists injection procedure-related adverse events observed in 2 clinical trials with a 2-year follow-up.<sup>2,3</sup>

## PATIENT AND PHYSICIAN SATISFACTION

Patient and physician satisfaction with poly-L-lactic acid has been surveyed as part of the Blue Pacific Study.<sup>5</sup> Patients who participated in this study (N=99; mean age, 45 years) had been infected with HIV for an average of 13.4 (2–24) years and were treated with antiviral agents for an average of 9 (2–22) years. Patient satisfaction was 4.6 and 4.8 (1=dissatisfied, 5=very satisfied) when measured at the end of treatment and at the 12-month follow-up, respectively. Physician satisfaction with treatment ranged from 4.5 and 4.8, respectively, for the same periods.

### POLY-L-LACTIC ACID IN THE AESTHETIC DERMATOLOGY PRACTICE

The effects of poly-L-lactic acid can persist for as long as 2 years<sup>6</sup> but are not permanent. Patients may require additional treatment. Poly-L-lactic acid does not restore lost fat mass at the site. Rather, the polymer expands cutaneous thickness, predominately through an initial increase in fibroblasts and a subsequent increase in the deposition of collagen fibers.<sup>7</sup> This may be advantageous in that the underlying mechanism for the lipoatrophy is likely to remain in progress. Thus, the new tissue will not be lost in the ongoing lipoatrophy.<sup>3</sup> To gain the maximum benefit, following the manufacturer's guidelines when preparing poly-L-lactic acid for injection is essential.

### REFERENCES

1. Lexi-Comp. Poly-L-lactic acid (Sculptra™). Available at: <http://www.lexi.com/web/content/newdrugs/chapter/mono/newdrugsdisp.jsp?id=hf103266>. Accessed November 23, 2004.
2. Valantin MA, Aubron-Olivier C, Ghosn J, et al. Poly-L-lactic acid implants (New-Fill) to correct facial lipoatrophy in HIV-infected patients: results of the open-label study VEGA. *AIDS*. 2003;17:2471-2477.
3. Moyle GJ, Lysakova L, Brown S, et al. A randomized open-label study of immediate versus delayed poly-L-lactic acid injections for the cosmetic management of facial lipoatrophy in persons with HIV infection. *HIV Med*. 2004;5:82-87.
4. Woerle B, Hanke CW, Sattler G. Poly-L-lactic acid: a temporary filler for soft tissue augmentation. *J Drugs Dermatol*. 2004;3:385-389.
5. Mest DR, Humble G. Safety and efficacy of intradermal poly-L-lactic acid (Sculptra) injections in patients with HIV-associated facial lipoatrophy [abstract]. *Antiviral Ther*. 2004;9:L36.
6. Vleggaar D, Bauer U. Facial enhancement and the European experience with Sculptra (Poly-L-lactic acid). *J Drugs Dermatol*. 2004;3:542-547.
7. Gogolewski S, Jovanovic M, Perren SM, et al. Tissue response and in vivo degradation of selected polyhydroxyacids (PLA, PHB, PHB/VA). *J Biomed Mater Res*. 1993;27:1135-1148. ■