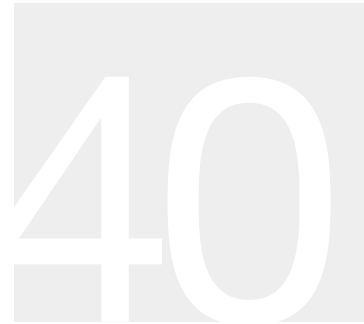

# ROTATOR CUFF TEAR: ARTHROSCOPIC TREATMENT



**KYLE R. FLIK**  
**ANDREAS H. GOMOLL**  
**BRIAN J. COLE**

Arthroscopic treatment of rotator cuff tears has become a routine procedure following a general trend toward using less invasive procedures. Proponents of this technique emphasize the decreased risk of complications such as infection, stiffness, and deltoid avulsions, whereas critics mention the lack of long-term studies, the controversy over the strength of fixation, and the technical challenge of all-arthroscopic repair of large tears for inexperienced practitioners. To help address the latter, this chapter will provide an overview of the indications, technique, and rehabilitation associated with arthroscopic rotator cuff repair.

## **PATHOGENESIS**

### **Etiology**

Although the exact pathogenesis is controversial, a combination of intrinsic and extrinsic factors is likely responsible for most rotator cuff tears. Intrinsic factors relate to the quality of the tendon substance itself, such as the chronic degeneration brought on by the relative hypoperfusion of a watershed area close to the insertion on the greater tuberosity, in conjunction with repetitive microtrauma.

Impingement ranks foremost among external factors implicated in rotator cuff tears. External or outlet impingement, the most common form, is caused by compression of the rotator cuff tendons as they pass underneath the coracoacromial arch. Narrowing of the subacromial space can be caused by the acromion itself as a result of arthritic changes of the acromioclavicular joint or by posttraumatic changes after proximal humerus fractures, especially with displacement of the greater tuberosity. In contrast, internal impingement is a controversial entity that has been described more recently and is thought to occur primarily in overhead and throwing athletes. Its anatomic

correlate consists of undersurface fraying of the infraspinatus tendon where it contacts the posterior glenoid as the arm is placed in maximum abduction and external rotation, such as the late cocking phase of throwing. Although this contact may often be present physiologically, the repetitive injury and eccentric loading associated with throwing can lead to labral and rotator cuff tears. Last, and intrinsically related to internal impingement, is secondary or nonoutlet impingement. This is often described as a dynamic process in which subtle subluxation of the humeral head with activity can acutely narrow the subacromial space and thus lead to impingement symptoms. It is associated with mild glenohumeral instability but can also result from contraction of the posterior capsule, which causes obligate anterosuperior humeral head translation with forward flexion.

A thorough understanding of the etiology of rotator cuff tears enables the physician to formulate a treatment plan to address the specific pathology present in a particular patient.

### **Epidemiology**

The point prevalence of shoulder pain has been estimated at 7% to 25% and the incidence at 10 per 1,000 per year, peaking at 25 per 1,000 per year among those 42 to 46 years of age. However, these are likely underestimates, as a large proportion of patients with rotator cuff tears remain asymptomatic. It is clear, nonetheless, that rotator cuff tears are strongly related to age; magnetic resonance imaging (MRI) scans of participants without shoulder pain reveal partial- and full-thickness rotator cuff tears in 4% of individuals younger than 40 years of age and in >50% older than 60 years. Furthermore, autopsy studies have demonstrated a prevalence of full-thickness rotator cuff tears of 6% in subjects younger than 60 years and 30% in those older than 60 years, although it was unknown how many of these had shoulder pain. Overall, the number of individuals with

## 2 Section III / Shoulder Reconstruction

rotator cuff dysfunction is expected to grow with an aging population that is increasingly active and less willing to accept functional limitations.

### Pathophysiology

In most rotator cuff tears, a combination of intrinsic and extrinsic factors leads to chronic tendon degeneration with eventual tensile failure. Rarely, acute tensile overload can lead to rupture of a healthy or minimally degenerated tendon. Most tears occur in and around the critical zone of the supraspinatus, an area between the bony insertion and musculotendinous junction, with relative hypoperfusion leading to increased susceptibility to damage. The natural history of rotator cuff dysfunction is not well understood. Prior investigations have demonstrated that 50% of individuals with asymptomatic tears developed pain within 5 years, although only 30% demonstrated increases in tear size. Studies investigating partial tears of the rotator cuff have demonstrated enlargement or progression to full-thickness tears in 80% of patients over a period of 2 years with nonoperative therapy. Once tears occur, there seems to be little to no evidence of spontaneous healing. A histopathologic study showed no signs of healing in pathologic specimens from partial-thickness tears. Furthermore, although shoulder complaints may be short lived, one study reported persistence or recurrence of symptoms in 40% to 50% of individuals 1 year after the initial presentation. It should also be understood that irreversible changes occur over time in the muscle tendon complex in the setting of rotator cuff detachment.

### Classification

Partial tears generally involve <50% of the tendon thickness and do not lead to retraction of the muscle. Depending on the location within the rotator cuff tendon, partial-thickness tears can be classified as intrasubstance, bursal sided, or articular sided (undersurface), the latter constituting approximately 90% of partial tears. Weakness is uncommon in partial thickness tears but can arise from pain, which is often greater than in complete tears.

In contrast, full-thickness tears represent complete discontinuity of rotator cuff fibers resulting in communication between the articular and bursal spaces. The extent of the lesion on imaging studies is described in both anteroposterior and mediolateral directions. One centimeter is generally considered small, 1 to 3 cm medium, 3 to 5 cm large, and >5 cm massive. Tears that involve two or more tendons can also be classified as massive and require more complex reconstruction. In larger tears, chronically retracted muscles undergo fatty degeneration over time that may be irreversible and may make results of direct repair unsatisfactory.

Rotator cuff tears can be further classified based on tear configuration. Crescent-shaped, L-shaped, and U-shaped tears have been described, all of which require slight modifications in repair technique to achieve excellent fixation (see below).

## DIAGNOSIS

### Physical Examination and History

#### Clinical Features

Rotator cuff pain is frequently described as a dull ache of insidious onset extending over the lateral arm and shoulder. Overhead activities exacerbate the pain, and pain frequently increases at night and may awaken the individual from sleep. Weakness with the inability to abduct and elevate the arm is seen in more advanced cases; patients frequently describe difficulties combing hair, holding a hair dryer, and removing the wallet from their back pocket. Acute onset of weakness, especially in association with trauma, may indicate an acute tear.

The clinical examination of a candidate for arthroscopic rotator cuff repair follows the standard shoulder exam described in earlier chapters. As in any preoperative evaluation, assessment of associated pathology that could be encountered at the time of surgery is crucial. The biceps tendon, capsulolabral complex, acromioclavicular joint, acromion, and especially the subscapularis tendon are structures that may require additional interventions that could considerably prolong and complicate an all-arthroscopic procedure. Recognition of the size, shape, and tissue quality is crucial to a successful arthroscopic repair.

#### Radiologic Features

**Radiography.** In the anteroposterior (AP) view, joint space narrowing and osteophyte formation may indicate arthritis of the glenohumeral or acromioclavicular joints. Calcium deposits from calcifying tendonitis usually present just proximal to the rotator cuff insertion. Elevation of the humeral head on AP radiographs, especially when the subacromial space is decreased to less than <5 to 7 mm, has been associated with large rotator cuff tears. The axillary view is essential to exclude the possibility of a dislocation. This view also shows the joint space and helps identify the rare but occasionally symptomatic os acromiale, which is a persistent and ununited ossification center at the end of the acromion. The 30-degree caudal tilt view is useful to assess the condition of the acromioclavicular joint. Finally, the supraspinatus outlet view allows visualization of the bony structures of the scapulothoracic motion interface and shows acromial spurs or calcification of the coracoacromial ligament that might compress the underlying rotator cuff.

**Ultrasound.** Ultrasound is noninvasive, readily available, and inexpensive. Recent studies using arthroscopy or MRI for validation of ultrasound have demonstrated sensitivities of 58% to 100% and specificities of 78% to 100% for full-thickness tears. It is less accurate in the detection of partial-thickness tears with sensitivities ranging from 25% to 94%.

**MRI and MR Arthrography.** Magnetic resonance imaging has sensitivities close to 100% for full-thickness tears and has all but replaced arthrography for the diagnosis for rotator cuff pathology. Moreover, the additional

quantitative and qualitative information gleaned from this cross-sectional study aids in the surgical planning and prognosis. The combination of MRI and gadolinium arthrography further improves sensitivity, especially for the detection of partial tears, to >90%, and of labral pathology to >80%. Important concerns regarding MRI include the associated cost and high frequency of false-positives. Up to 30% of asymptomatic volunteers have findings of rotator cuff anomalies, and up to 50% show labral anomalies.

The surgeon should closely review all MRI series and images preoperatively to determine tear size and location, as well as tissue quality, since massive tears with retraction and fatty degeneration of the muscle might prove to be irreparable. Coronal images best show the supraspinatus and degree of tendon retraction, axial images best display subscapularis disruption, and sagittal images will give an estimate on the width of the cuff insertion that is disrupted.

## TREATMENT

### Nonoperative Treatment

A trial of nonoperative treatment is indicated in virtually all patients with rotator cuff pathology. One exception is the young patient presenting with acute weakness owing to a traumatic event. Conservative treatment includes subacromial steroid injections and anti-inflammatory medications to control pain in the acute period, followed by a physical therapy program designed to increase muscle strength and balance. This is best accomplished with attention to proper rehabilitation of the scapular stabilizers, the remaining intact rotator cuff, and the anterior deltoid.

### Surgical Indications/Contraindications

The indications for arthroscopic rotator cuff repair follow those of open rotator cuff repair. The primary indication for surgical treatment is persistent pain unresponsive to nonoperative measures; poor function and diminished strength are secondary indications. The ideal surgical candidate is a compliant patient with adequate tendon quality who can follow a rigorous postoperative rehabilitation program. All patients should recognize that the results are dependent on many factors including tear size and retraction, tissue quality, muscle degeneration and atrophy, and overall health of the patient.

The few contraindications to arthroscopic rotator cuff repair include active or recent infection, medical comorbidities that make surgery or anesthesia unsafe, and advanced glenohumeral arthritis requiring arthroplasty. Relative contraindications may include significant fatty infiltration of the involved muscles and fixed superior migration of the humeral head with marked retraction of tendon edges on MRI.

### Operative Treatment

#### Surgical Considerations

The goal of arthroscopic rotator cuff repair is to relieve pain and improve shoulder function while addressing all

concomitant intra-articular pathology in a minimally invasive manner. Many technical aspects of arthroscopic rotator cuff surgery are evolving as our understanding of failure mechanisms and patient outcomes grows. Many issues remain controversial, such as the need for routine acromioplasty, the management of incomplete tears, optimal suture management, and anchor configuration—single row versus double row. Nonetheless, the successful arthroscopic treatment of rotator cuff tears depends on recognition of tear patterns, appropriate use of releases, secure fixation with restoration of the footprint under minimal tension, and proper rehabilitation.

Currently, most surgeons routinely perform an acromioplasty as part of the decompression prior to initiating repair. This may improve visualization in addition to reducing potential external compression of the cuff from the anterolateral acromion while affording space for the repaired tendon to clear the acromion during rotation. However, recent studies have suggested that routine performance of an acromioplasty may not be necessary. The primary technical concern while performing the acromioplasty relates to release of the coracoacromial (CA) ligament. A complete release of the ligament should be avoided, especially in large and massive rotator cuff tears, since it provides a restraint to superior escape of the humeral head in the rotator cuff deficient shoulder. An adequate acromioplasty, however, can easily be performed even without complete release of the CA ligament. Also, sparing the most anterior attachment of the CA ligament, as well as the deltoid fascia, helps to minimize fluid extravasation during subacromial arthroscopy.

#### Anesthetic Considerations

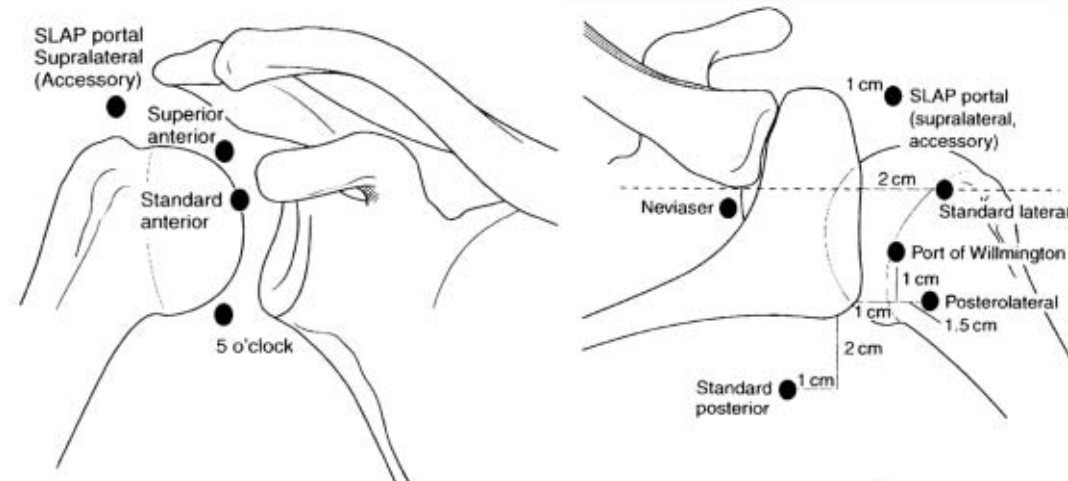
Arthroscopic rotator cuff repair is usually performed under general anesthesia with endotracheal intubation, laryngeal mask ventilation, regional anesthesia through an interscalene nerve block, or a combination thereof. The decision is made in collaboration with the patient and anesthesiologist. Regional anesthesia is beneficial especially for same-day surgical procedures since its analgesic effects commonly continue for several hours past discharge. Preemptive analgesia with nonsteroidal anti-inflammatories (NSAIDs) given the night before the operation is being used by an increasing number of surgeons and is usually continued for several days postoperatively. Concerns are emerging, however, regarding the potential inhibitory effects that NSAIDs might have on the early healing process.

#### Patient Positioning and Portal Placement

Based on the surgeon's preference, the patient is placed in either the beach-chair or lateral decubitus position. Although each position has unique advantages and limitations, both are acceptable choices for arthroscopic rotator cuff repair.

Portals useful in arthroscopic rotator cuff repair include standard posterior, anterior, anterolateral, and posterolateral portals (Fig. 40-1) as described in previous chapters. Anchor placement occasionally requires accessory portals that deviate from the standard portals described above. These portals should be kept as small as possible to minimize injury to the deltoid muscle and used only for percutaneous anchor placement without the use of a cannula. Another portal that we have recently described and find particularly

4 Section III / Shoulder Reconstruction



AU/PE: Please check callouts. (My copy is illegible.)

Figure 40-1 Standard portals in shoulder arthroscopy.

useful is the posteromedial portal, which is placed approximately 3 cm medial to the standard posterior portal and allows an in-line passage of a suture retrieving instrument (i.e., penetrating suture grasper).

#### Surgical Technique

**Diagnostic Arthroscopy.** A brief diagnostic arthroscopy is performed through standard anterior and posterior portals to evaluate potentially associated pathology. After the rotator cuff tear is visualized, it is often helpful to mark the exact location by passing a suture percutaneously through the tear into the subacromial space, especially in small tears, which can be difficult to visualize once the subacromial space is entered.

**Subacromial Decompression.** A bursectomy and limited acromioplasty is performed with an arthroscopic bur and radiofrequency ablation device to control bleeding. The rotator cuff tear is judiciously debrided simply to freshen the leading edge. The insertion site on the greater tuberosity (footprint) is cleaned of soft tissues and gently superficially debrided to create a bleeding subcortical surface.

**Releases.** Torn rotator cuff tendons often are contracted through their capsular attachments or are adherent to surrounding tissue. Releasing these attachments and adhesions with an electrothermal device or an arthroscopic elevator is crucial to obtaining full cuff mobilization. With a grasper or traction suture on the leading edge, the surgeon can evaluate the results of the performed release. If the tendon can be reduced to the footprint only by applying significant tension, further releases should be performed to allow for a tensionfree repair.

Releases should be performed between the cuff tendons and the undersurface of the acromion. Anterior releases in the rotator interval region can separate adhesions between the supraspinatus and the coracoid and subscapularis. Occasionally, posterior release between the supraspinatus and infraspinatus is required. In long-standing tears, the cuff may be adherent to the glenoid neck, and releasing the

capsule adjacent to the superior and posterior labrum is particularly useful. However, the suprascapular nerve and vessels are at risk during this dissection, which should not extend further than 1 to 2 cm medial to the glenoid rim.

**Tear Patterns.** As mentioned earlier, several tear configurations have been described. Crescent-shaped tears are more commonly found acutely or subacutely and usually are easily mobilized and repaired directly to bone with suture anchors (Figure 40-2). U-shaped tears are usually larger and may require side-to-side repair (i.e., margin convergence) to reduce tear size and decrease tension on the leading edge, thus allowing for a more stable repair to the tuberosity (Figure 40-3). L-shaped tears are best addressed with a side-to-side repair of the longitudinal limb before securing the horizontal limb to bone with suture anchors (Figure 40-4). Side-to-side repairs are performed with free sutures that can be passed through the tendon substance with various instruments and techniques (Figure 40-5). Our preference is to use a straight penetrating suture grasper when working in the posterior two thirds of the cuff as well as during repair of the more medial extent of the side-to-side

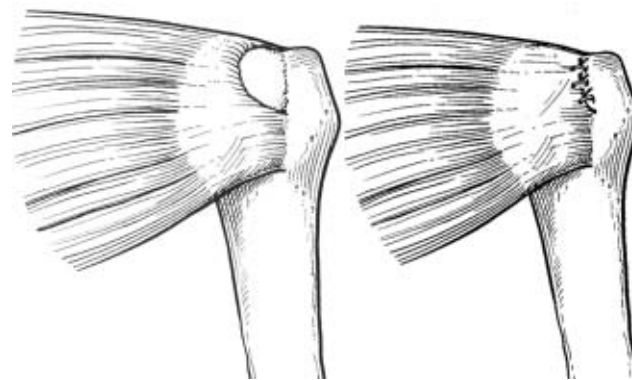


Figure 40-2 Crescent-shaped tear and repair.

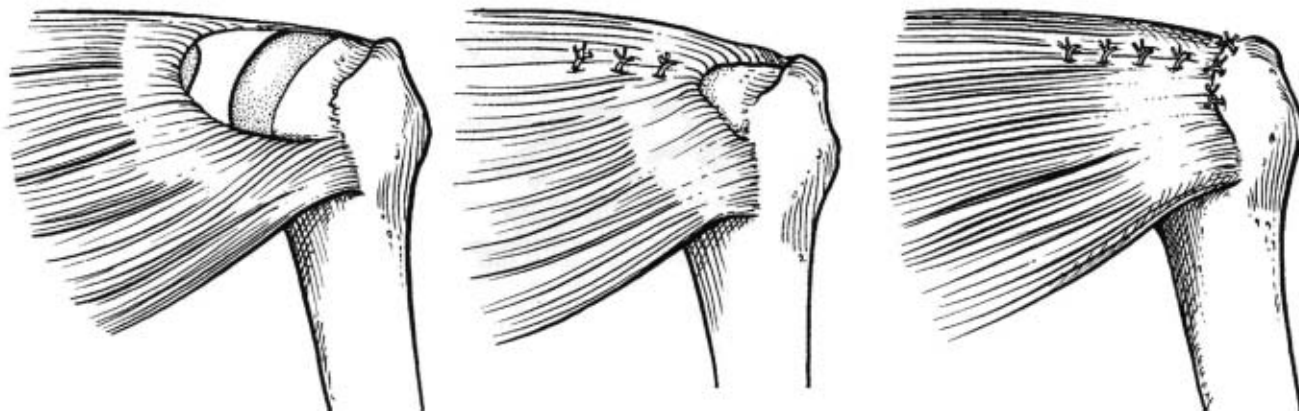


Figure 40-3 U-shaped tear and repair.

component of the tear. More laterally and anteriorly, a straight shuttle-type suture passing device is more effective.

**Fixation.** The actual repair of the tendon to the tuberosity can be performed with various techniques. The two most common portal configurations involve visualization through the lateral portal with instrumentation through the posterior or posteromedial portal (our preference), and vice versa. The first step is to prepare the footprint on the greater tuberosity to obtain an optimal environment for healing. Increasingly, surgeons refrain from extensive decortication during preparation of the footprint with an arthroscopic bur since it does not appear to improve healing and can compromise suture anchor fixation.

Arthroscopic repair of the rotator cuff tendon to the footprint uses suture anchors, which can be either bioabsorbable or metal, depending on surgeon preference. Advantages of bioabsorbable anchors include decreased artifacts on follow-up MRI and eventual resorption, potentially making revisions easier and reducing concerns over

loose anchors that could damage the joint. Advantages of metal anchors include lower cost, decreased risk of anchor breakage during insertion, and lack of reactivity in the surrounding bone. Anchors are placed in the lateral aspect of the footprint for a single-row technique, or medially and laterally for a double-row technique in larger tears amenable to this anchor/suture configuration. The double-row technique reduces tension on the lateral anchors and secures the tendon to a larger bony surface.

After anchors are placed, the suture on the anchor must be passed through the rotator cuff tendon. There are many devices on the market to facilitate this process; however, the senior author prefers working with low-profile penetrating suture graspers for the posterior cuff in combination with a 45-degree ipsilateral (i.e., right curve for right shoulder) curved suture shuttle device for the more anterior aspect of the tear. Alternatively, there are several excellent devices that can be passed with a loaded suture directly through the anterolateral or lateral portal (while viewing from posteriorly) and passed antegrade directly through the lateral tendon edge. Whenever shuttling or making use of the antegrade suture passing device, it is helpful to avoid having more than a single suture limb within the cannula at any give time to avoid entanglement.

It is important to consider the direction of tear retraction when placing sutures. Since most tears of the supraspinatus and infraspinatus tendons retract in a posteromedial fashion, sutures should be placed more posteriorly relative to the anchor to restore proper tendon orientation. Suture anchors should be placed in a methodical order to help with suture management, often from posterior to anterior. Sutures should be stored in unused cannulas to avoid entanglement, and only one suture should be kept in a working cannula during knot tying. We typically, whenever possible, place a central and medial anchor loaded with two sutures and retrieve all four limbs with a penetrating suture grasper placed through the posteromedial or posterior portal, creating two independent horizontal mattress sutures. Next, we place at least two additional anchors beginning more posterior and lateral to the first medial anchor already in position. The final anchor is placed typically just behind the bicipital groove in line with the second more laterally placed anchor.

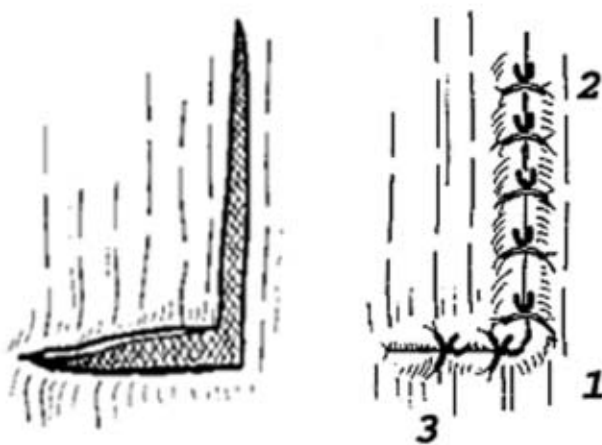
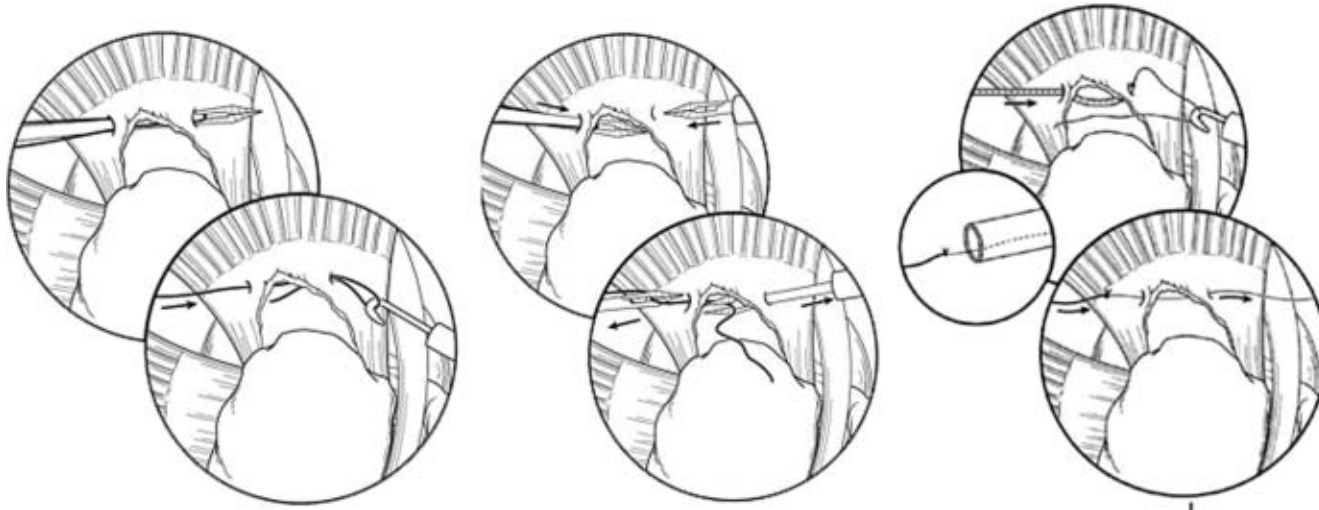


Figure 40-4 L-shaped tear and repair.

6 Section III / Shoulder Reconstruction



**Figure 40-5** Side-to-side repair techniques for margin conversion sutures: antegrade (left), antegrade hand-off (middle), and antegrade shuttle (right) techniques.

Arthroscopic knot tying is a crucial technical aspect of a successful repair. Although many different sliding and non-sliding techniques have been described, the senior author prefers simple half hitches on alternating posts. This reliable and simple method does not require sliding of the suture through the tissue, which has been incriminated in suture cutout. Irrespective of the technique used, care must be taken to ensure that the knot tightly reduces the tendon to the anchor and bony bed of the footprint to allow healing.

### Results and Outcome

Clinical outcomes after arthroscopic rotator cuff repair have been comparable to open reconstruction, despite the fact that radiologic investigations have demonstrated a comparatively higher rate of recurrent tears on MRI follow-up. Between 77% and 98% of patients are satisfied with their outcome after rotator cuff repair, with excellent pain relief and functional improvement in >80%. Benefits of arthroscopic repair versus open or mini-open techniques include smaller incisions with less soft tissue dissection, avoidance of deltoid detachment, improved visualization of the entire glenohumeral joint for evaluation and treatment of concomitant pathology, and decreased postoperative pain. However, arthroscopic repair has been associated with a significant rate of recurrent tears. Our own results have demonstrated a retear rate of  $\leq 47\%$  at 2 years on MRI examination. Nonetheless, clinical results do not seem to suffer in these patients. We have found significantly improved functional and pain scores, as well as improved strength, even in the setting of a recurrent tear, with patients rating their postsurgical shoulder at 85% of their normal contralateral side.

Complications are comparatively low, with infection reported in <1% of cases. Traction injuries of the brachial plexus occur as very rare complications when shoulder arthroscopy is performed in the lateral decubitus position,

but are usually transient. The incidence of minor complications related to edema from fluid extravasation is unknown and is typically inconsequential; however, there have been reports of subcutaneous emphysema causing serious pulmonary complications during shoulder arthroscopy, which emphasizes the need for continued monitoring of the patient's shoulder and neck for excessive swelling or crepitus.

### Postoperative Management

The postoperative rehabilitation program is one of the most important factors in achieving a good result. Postoperatively, patients are typically placed in a sling and a supportive abduction pillow, which is worn at all times, except for hygiene and therapeutic exercise. The rehabilitation program is divided into three phases, which are based on the progression of healing with increasing strength of the reconstruction:

In phase 1 (weeks 0 to 4), exercises are restricted to passive range of motion (ROM), with limits of motion based on intraoperative assessment of repair stability. Therapeutic exercises during this phase include pendulum exercises; elbow, wrist and hand ROM; grip strengthening; and isometric scapular stabilization.

During phase 2 (weeks 4 to 8), the sling is discontinued and ROM is progressed to 140 degrees of forward flexion, 40 degrees of external rotation, abduction to 60 to 80 degrees, and posterior capsular stretching to maintain or improve internal rotation. Therapeutic exercises are advanced to gentle active-assisted exercises in the supine position with progression to active exercises with resistance at 6 weeks. Deltoid and biceps strengthening is initiated, with the arm kept close to the side to minimize lever arm forces on the rotator cuff.

Phase 3 (approximately weeks 8 to 12) is characterized by progression to full motion as tolerated. Scapular strengthening is continued, and internal and external rotation isometric exercises are added to the program. During the

final phase of rehabilitation, sport-specific activities are initiated, flexibility is maintained, and strengthening exercises are continued. Usually, formal physical therapy is discontinued after approximately 4 months, with return to unrestricted athletic activities at 6 months.

### SUGGESTED READING

- Berjano P, Gonzalez BG, Olmedo JF, et al. Complications in arthroscopic shoulder surgery. *Arthroscopy*. 1998;14:785–788.
- Bigliani LU, Ticker JB, Flatow EL, et al. The relationship of acromial architecture to rotator cuff disease. *Clin Sports Med*. 1991;10:823–838.
- Burkhart SS, Athanasiou KA, Wirth MA. Margin convergence: a method of reducing strain in massive rotator cuff tears. *Arthroscopy*. 1996;12:335–338.
- Carpenter JE, Flanagan CL, Thomopoulos S, et al. The effects of overuse combined with intrinsic or extrinsic alterations in an animal model of rotator cuff tendinosis. *Am J Sports Med*. 1998;26:801–807.
- Fuchs B, Weishaupt D, Zanetti M, et al. Fatty degeneration of the muscles of the rotator cuff: assessment by computed tomography versus magnetic resonance imaging. *J Shoulder Elbow Surg*. 1999;8:599–605.
- Galatz LM, Ball CM, Teefey SA, et al. The outcome and repair integrity of completely arthroscopically repaired large and massive rotator cuff tears. *J Bone Joint Surg Am*. 2004;86A:219–224.
- Gartsman GM, Khan M, Hammerman SM. Arthroscopic repair of full-thickness tears of the rotator cuff. *J Bone Joint Surg Am*. 1998;80:832–840.
- Gartsman GM, O'Connor DP. Arthroscopic rotator cuff repair with and without arthroscopic subacromial decompression: a prospective, randomized study of one-year outcomes. *J Shoulder Elbow Surg*. 2004;13:424–426.
- Goldberg BA, Lippitt SB, Matsen FA III. Improvement in comfort and

- function after cuff repair without acromioplasty. *Clin Orthop Relat Res*. 2001;390:142–150.
- Kim SH, Ha KI, Park JH, et al. Arthroscopic versus mini-open salvage repair of the rotator cuff tear: outcome analysis at 2 to 6 years' follow-up. *Arthroscopy*. 2003;19:746–754.
- Lau KY. Pneumomediastinum caused by subcutaneous emphysema in the shoulder. A rare complication of arthroscopy. *Chest*. 1993;103:1606–1607.
- Lee HC, Dewan N, Crosby L. Subcutaneous emphysema, pneumomediastinum, and potentially life-threatening tension pneumothorax. Pulmonary complications from arthroscopic shoulder decompression. *Chest*. 1992;101:1265–1267.
- Lehman C, Cuomo F, Kummer FJ, et al. The incidence of full thickness rotator cuff tears in a large cadaveric population. *Bull Hosp Jt Dis*. 1995;54(1):30–31.
- Lo IK, Burkhart SS. Double-row arthroscopic rotator cuff repair: re-establishing the footprint of the rotator cuff. *Arthroscopy*. 2003;19:1035–1042.
- Loutzenheiser TD, Harryman DT II, Yung SW, et al. Optimizing arthroscopic knots. *Arthroscopy*. 1995;11:199–206.
- Potter HG, B. S. Magnetic imaging of the shoulder: a tailored approach. *Techniques Shoulder Elbow Surg*. 2005;6(1):43–56.
- Schibany N, Zehetgruber H, Kainberger F, et al. Rotator cuff tears in asymptomatic individuals: a clinical and ultrasonographic screening study. *Eur J Radiol*. 2004;51(3):263–268.
- Tempelhof S, Rupp S, Seil R. Age-related prevalence of rotator cuff tears in asymptomatic shoulders. *J Shoulder Elbow Surg*. 1999;8(4):296–299.
- Wiener SN, Seitz WH Jr. Sonography of the shoulder in patients with tears of the rotator cuff: accuracy and value for selecting surgical options. *AJR Am J Roentgenol*. 1993;160:103–107; discussion 109–110.
- Wilson F, Hinov V, Adams G. Arthroscopic repair of full-thickness tears of the rotator cuff: 2- to 14-year follow-up. *Arthroscopy*. 2002;18:136–144.
- Yamaguchi K, Tetro AM, Blam O, et al. Natural history of asymptomatic rotator cuff tears: a longitudinal analysis of asymptomatic tears detected sonographically. *J Shoulder Elbow Surg*. 2001;10(3):199–203.

**Au: Please clarify author's name.**