

# Histological study on the effects of microablative fractional CO<sub>2</sub> laser on atrophic vaginal tissue: an ex vivo study

Stefano Salvatore, MD,<sup>1</sup> Umberto Leone Roberti Maggiore, MD,<sup>1</sup> Stavros Athanasiou, MD,<sup>2</sup> Massimo Origoni, MD,<sup>1</sup> Massimo Candiani, MD,<sup>1</sup> Alberto Calligaro, MD,<sup>3</sup> and Nicola Zerbinati, MD<sup>4</sup>

## Abstract

**Objective:** Microablative fractional CO<sub>2</sub> laser has been proven to determine tissue remodeling with neoformation of collagen and elastic fibers on atrophic skin. The aim of our study is to evaluate the effects of microablative fractional CO<sub>2</sub> laser on postmenopausal women with vulvovaginal atrophy using an ex vivo model.

**Methods:** This is a prospective ex vivo cohort trial. Consecutive postmenopausal women with vulvovaginal atrophy managed with pelvic organ prolapse surgical operation were enrolled. After fascial plication, the redundant vaginal edge on one side was treated with CO<sub>2</sub> laser (SmartXide2; DEKA Laser, Florence, Italy). Five different CO<sub>2</sub> laser setup protocols were tested. The contralateral part of the vaginal wall was always used as control. Excessive vagina was trimmed and sent for histological evaluation to compare treated and nontreated tissues. Microscopic and ultrastructural aspects of the collagenic and elastic components of the matrix were studied, and a specific image analysis with computerized morphometry was performed. We also considered the fine cytological aspects of connective tissue proper cells, particularly fibroblasts.

**Results:** During the study period, five women were enrolled, and 10 vaginal specimens were finally retrieved. Four different settings of CO<sub>2</sub> laser were compared. Protocols were tested twice each to confirm histological findings. Treatment protocols were compared according to histological findings, particularly in maximal depth and connective changes achieved. All procedures were uneventful for participants.

**Conclusions:** This study shows that microablative fractional CO<sub>2</sub> laser can produce a remodeling of vaginal connective tissue without causing damage to surrounding tissue.

**Key Words:** Aging – Microablative fractional CO<sub>2</sub> laser – Menopause – Pelvic organ prolapse – Vulvovaginal atrophy.

The aging process is genetically determined and environmentally modulated. Estrogen deficiency occurring after menopause causes a series of modifications in many different areas of the female body, including the pelvic floor; in fact, estrogen receptors have been identified in the genital urinary tract and lower urinary tract.<sup>1</sup> Menopause can therefore lead to functional genital or urinary symptoms impacting women's quality of life. It is debatable to which extent modifications and symptoms occurring after menopause are related to estrogen deficiency or to the aging process per se.

Received August 27, 2014; revised and accepted October 28, 2014.

From the <sup>1</sup>Obstetrics and Gynecology Unit, Vita-Salute San Raffaele University and IRCCS San Raffaele Hospital, Milan, Italy; <sup>2</sup>Urogynecology Unit, First Department of Obstetrics and Gynecology, National and Kapodistrian University of Athens, Athens, Greece; <sup>3</sup>Department of Experimental Medicine, Histology, and Embryology, University of Pavia, Pavia, Italy; and <sup>4</sup>Department of Dermatology, University of Insubria, Varese, Italy.

Funding/support: None.

Financial disclosure/conflicts of interest: S.S., A.C., and N.Z. have had financial relations (expert testimonies and lectures) with DEKA Laser. The other authors report no potential conflicts of interest.

Address correspondence to: Umberto Leone Roberti Maggiore, MD, Obstetrics and Gynecology Unit, Vita-Salute San Raffaele University and IRCCS San Raffaele Hospital, Via Olgettina 58-60, Milan 20132, Italy. E-mail: ulrm@me.com

Vulvovaginal atrophy (VVA) involves histological, morphological, and clinical changes such as alteration in collagen type I fibrils-to-collagen type III fibrils ratio with loss of their trabecular disposition (collagen fibrils become flattened); decreased quantity of elastic fibers; reduced vascularization; and thinning and flattening of the vaginal epithelium, which can superficially turn into a keratinized layer.<sup>2</sup> As a consequence, the vaginal canal becomes shorter and narrower, and the vaginal epithelium becomes paler and more likely to develop petechiae. Women with VVA commonly complain of vaginal dryness, burning, irritation or itching, and dyspareunia.<sup>3</sup>

Local estrogens represent the first-line therapy for VVA. However, women's compliance with and preference for this treatment are poor<sup>4</sup>; alternatives and palliative solutions, such as moisturizing or lubricant local creams or gels, are commonly proposed.<sup>5</sup>

In recent years, microablative fractional CO<sub>2</sub> laser has become a popular, efficient, precise, and safe system, particularly for dermatologists and plastic surgeons. CO<sub>2</sub> laser has many applications, including treatment of skin lesions (ie, seborrheic keratosis, syringomas, and xanthelasma around the eye), warts, and toenail diseases, as well as antiaging function.

Microablative fractional CO<sub>2</sub> laser has already been used on atrophic skin showing the regenerative properties of scar tissue,<sup>6-11</sup> with significant histological changes in connective

components that are the same as those observed in the vaginal canal. The action mechanism of microablative fractional CO<sub>2</sub> laser occurs through a microablative action that stimulates tissue remodeling. Such process involves interaction with heat shock proteins 43, 47, and 70,<sup>12,13</sup> which induce, as demonstrated in the skin,<sup>14</sup> a local increase in different cytokines, specifically transforming growth factor- $\beta$  (stimulating matrix proteins such as collagen), basic fibroblast growth factor (stimulating angiogenic activity with endothelial cell migration and proliferation), epidermal growth factor (stimulating re-epithelization), platelet-derived growth factor (stimulating fibroblasts to produce extracellular matrix components), and vascular endothelial growth factor (regulating vasculogenesis and angiogenesis)—activating fibroblasts to produce new collagen, other components of the extracellular matrix (proteoglycans, glycosaminoglycans, and other molecules), and new vessels, with specific effects on epithelial tissue.

In this study, we intend to investigate the effects of different settings of microablative fractional CO<sub>2</sub> laser on the vaginal canal using an ex vivo model. Proof of concept and feasibility study are necessary before a clinical evaluation of CO<sub>2</sub> laser as potential treatment of VVA can be started.

## METHODS

For this study, we recruited consecutive postmenopausal and nonestrogenized women with signs of VVA who were referred to our urogynecological clinic for prolapse repair. Before entry into the study, each participant was evaluated for prolapse severity according to the International Continence Society Pelvic Organ Prolapse Quantitation system.<sup>15</sup> Only women with symptomatic stage II or higher anterior vaginal wall prolapse, with or without descent of other vaginal compartments, were considered for inclusion.

Institutional Review Board approval was obtained before the start of the study, and each participant signed a written informed consent form.

Each woman was subjected to anterior repair using a native tissue approach. In each participant, after fascial plication, one side of the redundant vaginal wall flap was treated with microablative fractional CO<sub>2</sub> laser (SmartXide2; DEKA Laser) using different machine settings (Table). We finally tested five different protocols, always maintaining the same dermal optical thermolysis (DOT) power (30 W) and dwell time (1,000  $\mu$ s) but varying DOT spacing (1,000 or 2,000  $\mu$ m) and smart stack function (1-3). The contralateral part of the vaginal wall was always used as control. Excessive vagina was

trimmed and immediately sent for histological evaluation to compare treated and nontreated tissues.

To assess which of the five protocols had the best efficacy profile, we sent all biopsies to the Department of Experimental Medicine, Histology, and Embryology, University of Pavia (Pavia, Italy) for histological evaluation. Biopsy specimens were fixed (in all five cases within 10 min of laser treatment) by direct immersion of mucosal samples in a 4% paraformaldehyde/phosphate buffer solution for 24 hours and processed for light microscopy through dehydration, embedding in paraffin, and sectioning. Sections were stained with hematoxylin and eosin to evaluate both the modifications of the connective extracellular matrix and the cellular components of the vaginal lamina propria.

Specimens were partially processed for evaluation under an electron microscope. For this purpose, fixation was performed by immersion in 2.5% glutaraldehyde (EM-grade)—4% paraformaldehyde in 0.1 M sodium cacodylate buffer solution (pH 7.3) for 6 hours at 4°C. Samples were postfixed for 2 hours in 1.33% osmium tetroxide in 0.1 M s-collidine buffer, dehydrated on graded ethanol scale, and finally embedded in epoxy resin (Epon 812). Semithin (0.2  $\mu$ m) and ultrathin (40-60 nm) sections were obtained with the ultramicrotome Reichert Ultracut S using a diamond knife: semithin sections were stained with toluidine blue, and ultrathin sections were stained with uranyl acetate and lead citrate. Observations and electron micrographs were made using a Zeiss EM 10 transmission electron microscope operating at 80 kV with an objective aperture of 30/60  $\mu$ m; images were recorded on Kodak 4489 Electron Image film and finally digitized with a Epson Perfection V750 Pro scanner at 1,200 dpi.

Qualitative analysis of the microscopic and ultrastructural aspects of the collagenic and elastic components of the matrix was performed. A specific image analysis with computerized morphometry was performed to demonstrate the specific action of CO<sub>2</sub> laser and possibly to correlate the modifications of the ultrastructural pattern with specific molecular modifications. We also considered the fine cytological aspects of connective tissue proper cells, particularly fibroblasts, under the conditions of the specific laser stimulation.

The same process was adopted for both CO<sub>2</sub> laser-treated and untreated vaginal samples (controls).

## RESULTS

For this study, we recruited five women with a median age of 63 years (range, 57-71 y). They were all referred for anterior vaginal prolapse repair (according to the International Continence Society Pelvic Organ Prolapse Quantitation system): two participants at stages IIa and IIc, and three participants at stages IIIa and IIc. None of the participants were taking any form of estrogen therapy. All women were subjected to vaginal hysterectomy, McCall culdoplasty, and anterior repair with fascial plication. All surgical procedures were completely uneventful and performed by the same surgeon (S.S.).

**TABLE . Laser parameters tested under five different protocols**

Protocol	DOT power	DOT dwell ( $\mu$ s)	DOT spacing ( $\mu$ m)	Smart stack
1	30	1,000	1,000	1
2	30	1,000	1,000	2
3	30	1,000	1,000	3
4	30	1,000	2,000	1
5	30	1,000	2,000	2

DOT, dermal optical thermolysis.

In all cases, the control side of the trimmed vagina confirmed an atrophic state showing a flattened epithelium, loss of papillae, and absence of activated fibroblasts in the lamina propria (Fig. 1A). The five different protocols previously illustrated were associated with varying degrees of changes in the epithelium and lamina propria in relation to mild ablative effects, fibroblasts activation, modifications of collagen and elastic fibers, and mucopolysaccharides in the lamina propria (Fig. 1B-F). On qualitative analysis, the protocol with the most evident effects was protocol 3 (30 W of DOT power, 1,000  $\mu$ s of DOT dwell, 1,000  $\mu$ m of DOT spacing, and smart stack 3), as shown in Figure 1D, where the more pronounced ablative effects and the presence of activated fibroblasts in the lamina propria are evident. These results were confirmed in all five participants.

Figure 2A, B, C shows some of the characteristic morphological features observed with protocol 3: many fibroblasts are observable, surrounded by compact bundles of renewing collagen fibers well distinguishable from the amorphous matrix (light microscopy, toluidine blue staining; Fig. 2A). Under an electron microscope, fine collagen microfibrils are clearly observable, with fine molecular filaments (arrows) in close relationship with collagen microfibrils in the course of fibrillogenesis (Fig. 2B). Figure 2C shows the typical ultrastructural features of an activated fibroblast, represented by a rich rough endoplasmic reticulum constituted by flattened cisternae with many electron-dense ribosomes attached on the cytoplasmic face of its membranes. Much dilation of cisternae with attached ribosomes,

containing a medium electron-dense material, was also observable. This material seems to be formed by a fine filamentous material realistically representing molecular precursors of the fibrillar components of the extracellular matrix, which have been synthesized most recently and are ready to be transferred to the Golgi apparatus for concentration, glycosylation, and extracellular release.

These morphological features—a highly represented rough endoplasmic reticulum with dilated cisternae and a well-developed Golgi apparatus—are related to a specific functional activation of fibroblasts with production of fibrillar components and glycoproteins, proteoglycans, and other molecules of the extracellular matrix.

## DISCUSSION

This study demonstrated the safe parameters (30 W of DOT power, 1,000  $\mu$ s of DOT dwell, 1,000  $\mu$ m of DOT spacing, and smart stack 3) for microablative fractional CO<sub>2</sub> laser for the treatment of the vaginal mucosa. Furthermore, the use of microablative fractional CO<sub>2</sub> laser on the vaginal mucosa with these parameters was immediately associated with initial tissue remodeling (ie, activation of fibroblasts and neocollagenesis), which leads to the foundation of its clinical application and allows us to contemplate promising results as previously described in many areas of the human body, such as the skin of the face, chest, and neck,<sup>9,10,16,17</sup> and in animal models,<sup>8,11</sup> including production of new collagen and other components of the extracellular matrix. The mechanism of such changes

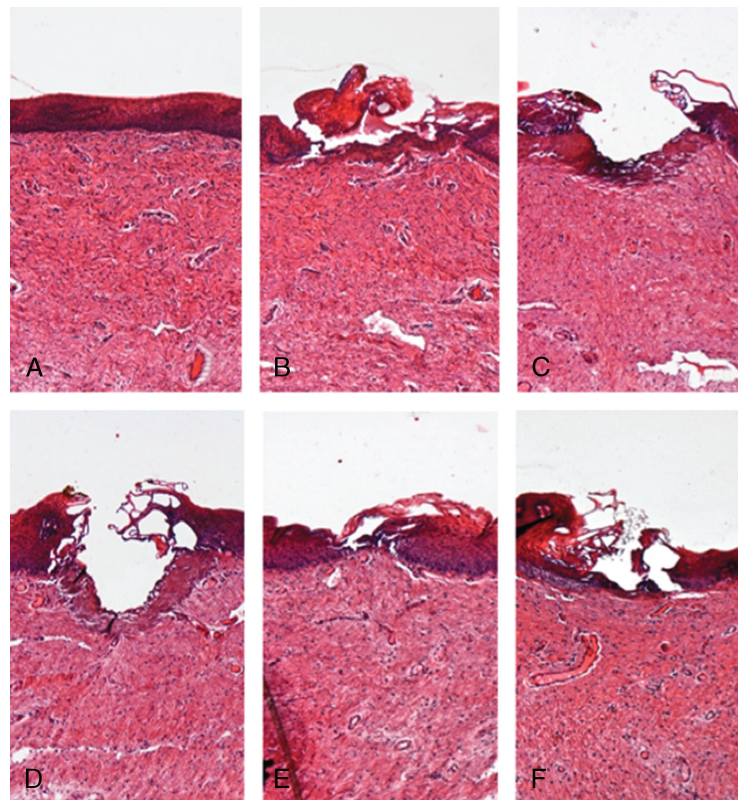
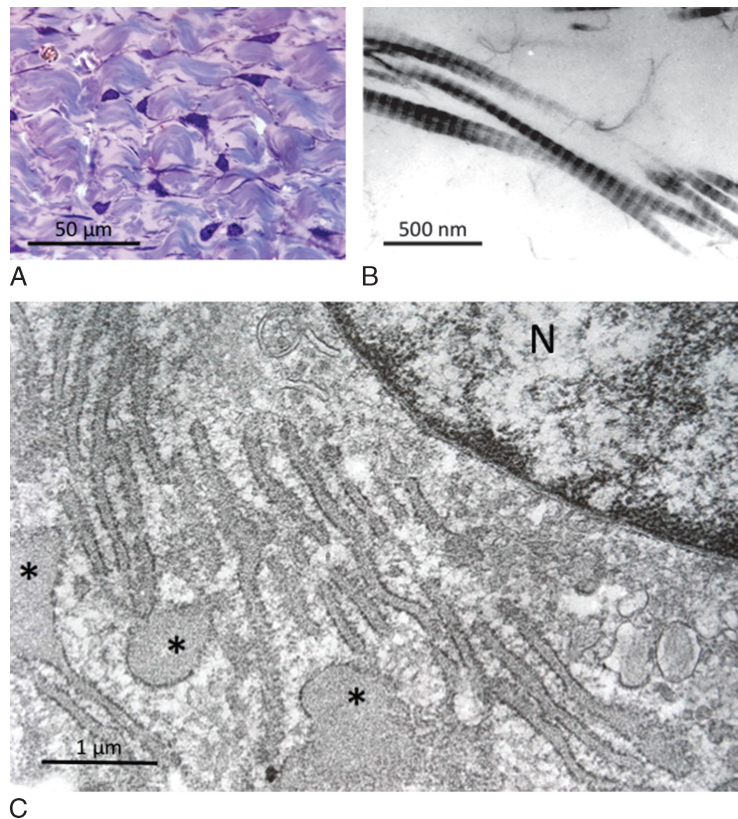


FIG. 1. Vaginal mucosa under a light microscope. (A) Atrophic control. (B-F) Treatment protocols 1, 2, 3, 4, and 5.



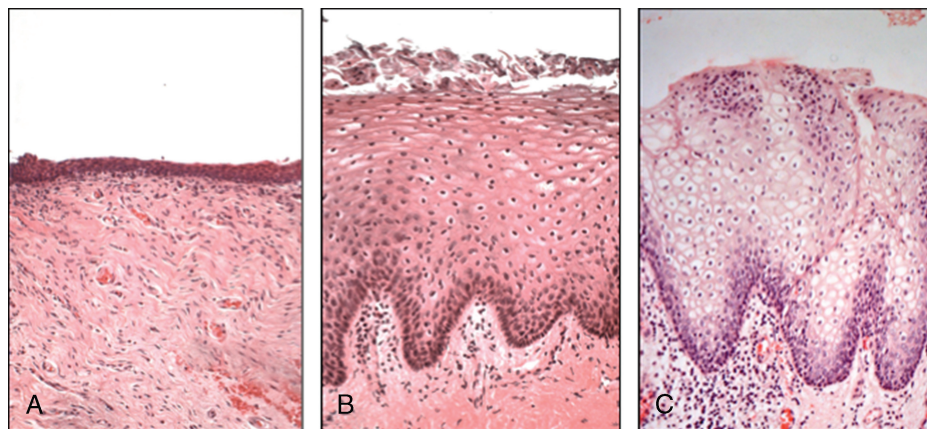


**FIG. 2.** (A) Fibroblasts surrounded by the extracellular matrix: compact bundles of collagen fibers are well distinguishable from the ground matrix (light microscopy, toluidine blue staining). (B) High-magnification electron microscopy of collagen microfibrils with characteristic banding, in close relationship with very thin filaments representing molecular components in the course of aggregation to form mature microfibrils (fibrillogenesis). (C) Part of a fibroblast under an electron microscope. The cytoplasm is filled with profiles of the rough endoplasmic reticulum, constituted by flattened cisternae transversally sectioned with a lot of ribosomes attached to membranes, and dilated vesicles continuous with membranes of the rough endoplasmic reticulum. Both these structures are filled with a finely filamentous material representing molecular precursors of collagen fibers. N, nucleus. \*Dilated vesicles.

caused by microablative fractional CO<sub>2</sub> laser involves a controlled heat shock response that stimulates the production of a small family of proteins—the heat shock proteins. Heat shock proteins 43, 47, and 70 (a protein subtype as chaperone of collagen, which is overexpressed after laser irradiation) could play a role in inducing the production of many growth factors.<sup>14</sup>

Transforming growth factor- $\beta$  is known to be a key element in inflammatory response and in the fibrogenic process, where fibroblasts produce collagen and, most generally, the extracellular matrix.

In this study, we have observed interesting histological and intracellular changes in the vaginal wall of postmenopausal



**FIG. 3.** Morphological findings from clinical practice. (A) Atrophic vaginal mucosa before fractional CO<sub>2</sub> laser treatment. (B) Vaginal mucosa of the same person 2 months after treatment. Note the lamina propria newly formed connective tissue with vessel-rich papillae, the thick stratified squamous epithelium, and normally shedding superficial cells. (C) Normal vaginal mucosa of a fertile-age woman (reported for comparison).

women irradiated with microablative fractional CO<sub>2</sub> laser. These modifications can be interpreted as tissue remodeling in a rejuvenating sense. Looking specifically at each single effect produced by microablative fractional CO<sub>2</sub> laser, the most evident are neocollagenesis and restoration of the trabecular architecture of the collagen itself, which resembles what appears in premenopausal women.

Vaginal laxity in postmenopausal women is related to changes in structure, with loss of collagen trabeculation and elasticity. New collagen formation, together with restoration of its trabecular spatial architecture attributable to microablative fractional CO<sub>2</sub> laser irradiation, might clinically be translated into reduced vaginal laxity, which is a common complaint among postmenopausal women.

Neovascularization associated with subepithelial papillae, together with production of a mucopolysaccharide substance (ground matrix), could also contribute to restoring the hydration of the whole extracellular matrix to premenopausal levels, to a more physiological vaginal pH, and to recreating the glycosaminoglycan film that constitutes a barrier to genital infection. All these tissue changes represent a real rejuvenating process of the vaginal wall that is also demonstrated at the ultrastructural level. Based on our ex vivo histological findings, clinical application of microablative fractional CO<sub>2</sub> laser on the atrophic vagina could determine a reverse process toward restoration to a premenopausal state. This is an intriguing and fascinating premise that has been recently demonstrated in clinical practice<sup>18</sup> (Fig. 3).

A limitation of the current study is the small number of participants included, which does not allow for replication of findings. However, the local Institutional Review Board approved the microablative fractional CO<sub>2</sub> laser study protocol for testing on a maximum of five participants.

Nevertheless, our histological results represent a sort of proof of concept that microablative fractional CO<sub>2</sub> laser can produce the same regenerating tissue effects on the vaginal wall as it does on the skin, with many dermatological applications.

Based on this background, we have completed two clinical prospective studies of the effects of microablative fractional CO<sub>2</sub> laser on VVA-related symptoms in postmenopausal women, which demonstrated that this technique is feasible, efficacious, and safe, and is related to a significant improvement in sexual function and sexual satisfaction among these participants at 12 weeks of follow-up.<sup>18,19</sup> Future studies should elucidate the long-term efficacy of microablative fractional CO<sub>2</sub> laser and whether repeated treatments are required to maintain the efficacy of this procedure.

## CONCLUSIONS

To the best of our knowledge, this study shows for the first time that microablative fractional CO<sub>2</sub> laser can produce a remodeling of vaginal connective tissue with consequent renewal of the vaginal mucosa.

## REFERENCES

1. Iosif CS, Batra S, Ek A, Astedt B. Oestrogens receptors in the human female lower urinary tract. *Am J Obstet Gynaecol* 1981;141:817-820.
2. Fadare O. Vaginal stromal sclerosis: a distinctive stromal change associated with vaginal atrophy. *Int J Gynecol Pathol* 2011;30:295-300.
3. Samsioe G. Urogenital aging—a hidden problem. *Am J Obstet Gynecol* 1998;178:S245-S249.
4. Nappi RE, Kokot-Kierepa M. Women's voices in the menopause: results from an international survey on vaginal atrophy. *Maturitas* 2010; 67:233-238.
5. The North American Menopause Society. Management of symptomatic vulvovaginal atrophy: 2013 position statement of The North American Menopause Society. *Menopause* 2013;20:888-902.
6. Sasaki GH, Travis HM, Tucker B. Fractional CO<sub>2</sub> laser resurfacing of photoaged facial and non facial skin: histologic and clinical results and side effects. *J Cosmet Laser Ther* 2009;11:190-201.
7. Weiss ET, Chapas A, Brightman L, et al. Successful treatment of atrophic postoperative and traumatic scarring with carbon dioxide ablative fractional resurfacing. *Arch Dermatol* 2010;146:133-140.
8. Berlin AL, Hussain M, Phelps R, Goldberg DJ. A prospective study of fractional scanned nonsequential carbon dioxide laser resurfacing: a clinical and histopathologic evaluation. *Dermatol Surg* 2009;35:222-228.
9. Tierney EP, Hanke CW. Fractionated carbon dioxide laser treatment of photoaging: prospective study in 45 patients and review of the literature. *Dermatol Surg* 2011;37:1279-1290.
10. Tierney EP, Hanke CW. Ablative fractionated CO<sub>2</sub> laser resurfacing for the neck: prospective study and review of the literature. *J Drugs Dermatol* 2009;8:723-731.
11. Lee CJ, Park JH, Ciesielski TE, Thomson JG, Persing JA. Retinoids, 585-nm laser, and carbon dioxide laser: a numeric comparison of neocollagen formation in photoaged hairless mouse skin. *Aesthetic Plast Surg* 2008;32: 894-901.
12. Dafforn TR, Della M, Miller AD. The molecular interactions of heat shock protein 47 (Hsp47) and their implications for collagen biosynthesis. *J Biol Chem* 2001;276:49310-49319.
13. Capon A, Mordon S. Can thermal lasers promote skin wound healing? *Am J Clin Dermatol* 2003;4:1-12.
14. Prignano F, Campolmi P, Bonan P, et al. Fractional CO<sub>2</sub> laser: a novel therapeutic device upon photobiomodulation of tissue remodelling and cytokine pathway of tissue repair. *Dermatol Ther* 2009;22(suppl 1): S8-S15.
15. Bump RC, Mattiasson A, Bø K, et al. The standardization of terminology of female pelvic organ prolapse and pelvic floor dysfunction. *Am J Obstet Gynecol* 1996;175:10-17.
16. Ong MW, Bashir SJ. Fractional laser resurfacing for acne scars: a review. *Br J Dermatol* 2012;166:1160-1169.
17. Peterson JD, Goldman MP. Rejuvenation of the aging chest: a review and our experience. *Dermatol Surg* 2011;37:555-571.
18. Salvatore S, Nappi RE, Zerbinati N, et al. A 12-week treatment with fractional CO<sub>2</sub> laser for vulvovaginal atrophy: a pilot study. *Climacteric* 2014;17:363-369.
19. Salvatore S, Nappi RE, Parma M, et al. Sexual function after fractional microablative CO<sub>2</sub> laser in women with vulvovaginal atrophy [e-pub]. *Climacteric* 2014.