Enhancing Periodontal Health Through Regenerative Approaches

Periodontal Soft Tissue Non–Root Coverage Procedures: Practical Applications From the AAP Regeneration Workshop

Vanchit John,* Laureen Langer,† Giulio Rasperini,‡ David M. Kim,§ Rodrigo Neiva,‖ Henry Greenwell,¶ Serge Dibart,# Mariano Sanz,** and E. Todd Scheyer††

Focused Clinical Question: What are the indications and clinical applications for gingival augmentation procedures, and what factors guide the choice among treatment options in specific situations?

Summary: Although there is still controversy regarding whether there needs to be a minimum amount of attached gingiva to maintain the stability of the gingival margin, prospective and retrospective studies have shown that, in the presence of suboptimal plaque control and clinical inflammation, attachment loss and gingival recession (GR) may result unless a minimum amount of keratinized tissue (KT) and attached gingiva are present. Treatment of mucogingival deformities requires gingival augmentation procedures that address both a functional and esthetic component for the patient. Although free gingival grafts (FGGs) are considered the gold standard for treatment of GR defects to obtain root coverage, augmentation of KT and attached gingiva may be accomplished by FGG or other autogenous grafting options, including the free connective tissue graft, the lateral pedicle graft, and the double papilla technique. In addition, the modified apically repositioned flap can be considered in some instances. Alternatives to autogenous graft tissue include acellular dermal matrix, extracellular matrix membrane, bilayer collagen matrix, and living cellular construct.

Conclusions: Understanding the clinical importance of the presence of a minimum amount of attached gingiva in patients with suboptimal hygiene is an important first step in addressing the condition. Patient education to address plaque control and counseling to quit smoking in patients who are smokers help enhance the success of these mucogingival surgical procedures. An analysis of patient-specific factors will help with the appropriate choice of surgical procedures aimed at augmenting the dimension of KT/attached gingival tissue. Evidence supporting the treatment decisions described in this practical application is summarized in the companion papers from the American Academy of Periodontology Regeneration Workshop (Kim and Neiva, *J Periodontol* 2015;86(Suppl.):S56-S72; Scheyer et al., *J Periodontol* 2015;86(Suppl.):S73-S76). *Clin Adv Periodontics* 2015;5:11-20.

Key Words: Dental plaque; gingiva; gingival recession; inflammation; periodontal attachment loss.

See related systematic review and consensus report in the Journal of Periodontology *(February 2015, Vol. 86, No. 2s) at www.joponline.org*.

* *Department of Periodontics and Allied Programs, School of Dentistry, Indiana University, Indianapolis, IN.*

† *Private practice, New York, NY.*

‡ *Department of Biomedical, Surgical, and Dental Sciences; Unit of Periodontology; Institute for Inpatient Treatment and Scientific Studies Cà Granda Foundation; University of Milan; Milan, Italy.*

§ *Department of Oral Medicine, Infection, and Immunity; Division of Periodontology; Harvard School of Dental Medicine; Boston, MA.*

‖ *Department of Periodontology, University of Florida College of Dentistry, Gainesville, FL.*

¶ *Graduate Periodontics, University of Louisville, Louisville, KY.*

Department of Periodontology, School of Dental Medicine, Boston University, Boston, MA.

** *Faculty of Dentistry, Complutense University, Madrid, Spain.*

†† *Private practice, Houston, TX.*

Submitted July 31, 2014; accepted for publication November 12, 2014

doi: 10.1902/cap.2015.140051

Background

Mucogingival deformities around teeth are common clinical findings. These conditions can progress under suboptimal plaque control, especially when associated with subgingival restorative margins, orthodontic tooth movement, or patient-induced mechanical trauma.[1-3] In these instances, gingival augmentation procedures are used to improve periodontal health, which can enhance the long-term prognosis of teeth. Gingival augmentation procedures, which were first introduced in the 1960s,[4,5] have had a good history of success in clinical practice. However, most of the articles published have not considered patient-reported outcomes and esthetics as part of the overall treatment success assessment. Although autogenous tissue grafting has been considered the "gold standard" to address mucogingival deformities, the use of alternative treatment modalities has assumed a greater role in clinical practice. In general, when alternative treatment modalities were used that did not require harvesting palatal tissue,

patients reported more satisfaction and less discomfort after treatment.[6] This has led to increased use of treatment options other than free gingival grafts (FGGs). However, long-term follow-up with these alternative therapies is limited.

Indications to Increase the Dimension of Keratinized Tissue (KT) Around Natural Teeth

Indications for gingival augmentation procedures around natural teeth generally include (Fig. 1):[7] 1) placement of a restoration with an intracrevicular margin; 2) impingement of major or minor connectors of removable partial dentures; and 3) use of an overdenture, in which there is an absence of gingiva associated with retained teeth. In addition, the following may also guide the use of gingival augmentation procedures: 1) presence of a narrow band of unattached KT or thin gingival biotype; 2) persistence of gingival inflammation along the marginal gingiva; 3) presence of gingival recession (GR) extending beyond the mucogingival junction with evidence of interproximal bone loss;[8] 4) high frenal attachment associated with GR; 5) evidence of progressive GR; 6) preprosthetic surgery; and 7) preorthodontic surgery.

Decision Process

The evidence supporting treatment decisions described below is summarized in the related American Academy of Periodontology Regeneration Workshop systematic review[9] and consensus report.[10] The goal of treatment of GR sites must be clearly defined before making recommendations to the patient. Treatment outcomes include a gain in the dimension of KT, obtaining root coverage, or both.

FIGURE 1 Presence of a narrow band of mobile unattached KT with a history of progressive GR.

This specific practical application is focused on gingival augmentation to enhance KT and attached gingiva and is unrelated to indications for root coverage.

When selecting treatment options, the most predictable surgical technique and the one that is likely to be most well tolerated by the patient should be selected after a detailed evaluation of the factors listed in Figure 2.

Patient-Specific Factors

In general, the success of most dental procedures is highly dependent on long-term maintenance of good oral hygiene by the patient. The presence of poor plaque control has been documented as one of the factors associated with less than optimal outcomes after periodontal surgical procedures. Prospective and retrospective studies have shown that in the presence of both suboptimal plaque control and clinical inflammation, attachment loss (AL), and GR may result, unless there is a minimum amount of 2 mm of KT with 1 mm of attached gingiva.[11-14] Lang and Löe[15] showed that tooth surfaces with <2 mm of keratinized gingiva exhibited clinical inflammation and varying amounts of gingival exudate.

Another patient-associated factor that affects treatment outcomes is smoking. Smoking has been reported to be one of the important reasons for failure after mucogingival surgery. Miller[16] reported a100% correlation between failure to obtain root coverage and heavy smoking. Heavy smoking was defined as smoking in excess of 10 cigarettes per day.

Additionally, the presence of modifiable factors on the healing process, such as uncontrolled diabetes mellitus (DM), can affect the outcome of the surgical procedure. Wound healing, which is a fundamental process in humans, is negatively affected in patients with DM and other systemic health conditions.[17]

Patient compliance with their maintenance and recall visits has a significant influence on the success of surgical procedures. Kennedy et al.[18] reported that those who discontinued their periodontal maintenance program showed additional GR on the non-grafted sites compared with the grafted sites. Accordingly, patient education should be a fundamental step in preparation for any surgical procedure.

In general, the rationales for performing gingival augmentation procedures around natural teeth include the following: 1) to facilitate improved plaque control; 2) to improve patient comfort; 3) to increase the zone of attached gingiva in conjunction with restorative, orthodontic, or prosthetic dentistry; and/or 4) to help prevent progressive GR.[19]

Mucogingival surgical treatment to increase the dimension of KT around teeth usually involves teeth that present with either a Miller Class III or IV GR defect.[8]

After assessing patient-specific factors at the systemic and local site levels, the decision regarding treatment approaches to increase KT in a specific site is based primarily on a small number of site and tissue factors, including: 1) the periodontal biotype; 2) the esthetic or non-esthetic location of the defect; and 3) whether single or multiple GR defects are involved.

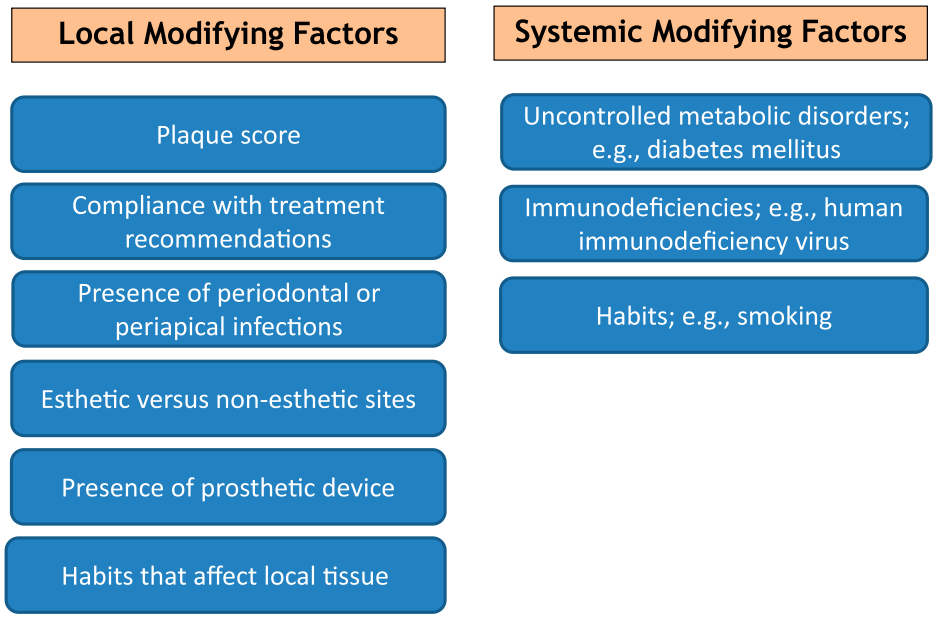

FIGURE 2 Factors influencing patient selection and treatment decisions.

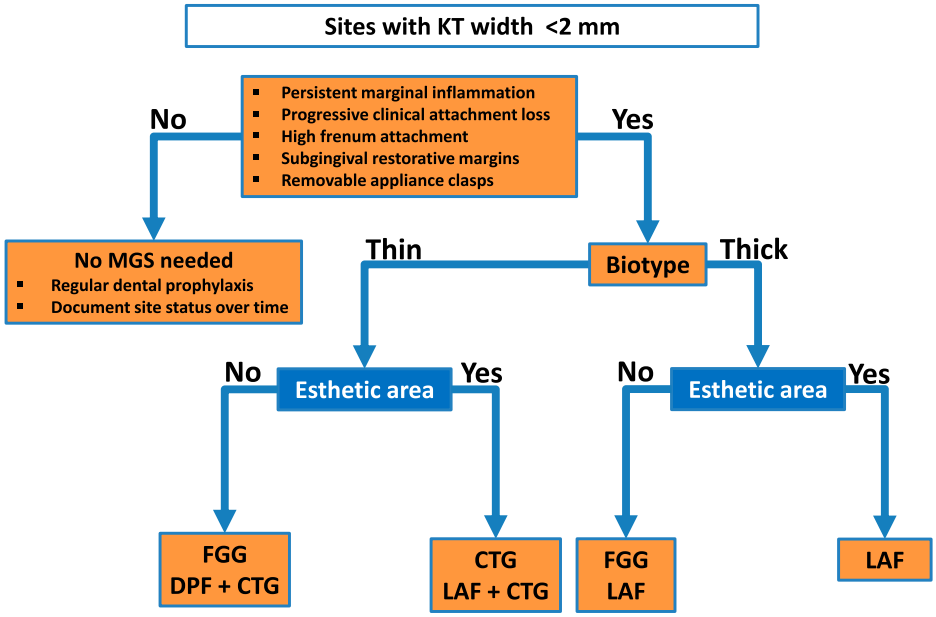

FIGURE 3 Treatment approaches to increase KT. Note that when multiple sites of GRs are present that may require harvesting several autogenous grafts, alternative options for treatment include: 1) MARF; 2) ECM; 3) BCM; and 4) LCC. MGS = mucogingival surgery; DPF = double papilla flap; LAF = laterally advanced flap.

A treatment algorithm as depicted in Figure 3 may be useful in planning the appropriate procedure for patients.

Clinical Scenarios

Sullivan and Atkins in 1968[4,5] first described the healing patterns associated with autogenous FGGs. Since that time, autogenous gingival grafts have been the method of choice in situations in which there is an indication for gingival augmentation.

The use of FGG has been shown to predictably increase the width of KT. It should be noted that the average contraction of FGGs ranges from 25% to 40% in the vertical dimension. This should be factored into the assessment of the size of the graft to be obtained and the length and width of the recipient site.

The FGG procedure is mostly indicated in non-esthetic areas because the grafted tissue often does not blend seamlessly with the surrounding tissues. The reported range of increased KT is 3.1 to 5.6 mm.[20]

Examples of clinical situations in which an FGG is an ideal surgical procedure to help increase the zone of keratinized gingiva are shown in Clinical Scenarios 1 through 4 below. FGGs are considered to be excellent treatment options when treating the mandibular anterior region.

All patients in the following clinical scenarios were provided oral explanation of the planned procedure. Every patient reviewed and signed an informed consent document. Videos 1, 2, 3, 4, and 5 depict a surgical procedure of the FGG performed (courtesy of Dr. Gustavo Avila-Ortiz, Department of Periodontics, University of Iowa, Iowa City,

FIGURE 4 Clinical Scenario 1. FGG. **4a** Shallow vestibule with midline frenum pull and 1 to 2 mm of keratinized gingiva on the mandibular incisors. The four incisors have GR of 1 to 3 mm. The area was treated with an autogenous FGG from teeth #23 through #26. **4b** Follow-up 27 years after the autogenous FGG. The tissue remains stable and uninflamed with no progression of the GR or loss of the increased dimension of the KT.

FIGURE 5 Clinical Scenario 2. FGG after orthognathic surgery. **5a** Thin biotype and GR with multiple frenula in the anterior mandible after orthognathic surgery. The band of keratinized gingiva was minimal because the GR was almost to the mucogingival junction. FGG was performed on the four incisors to expand the dimension of KT, avoiding the area of the remaining screws. **5b** Four-year follow-up. Note the presence of an increased band of keratinized gingiva. The original GR has decreased by 1 to 2 mm.

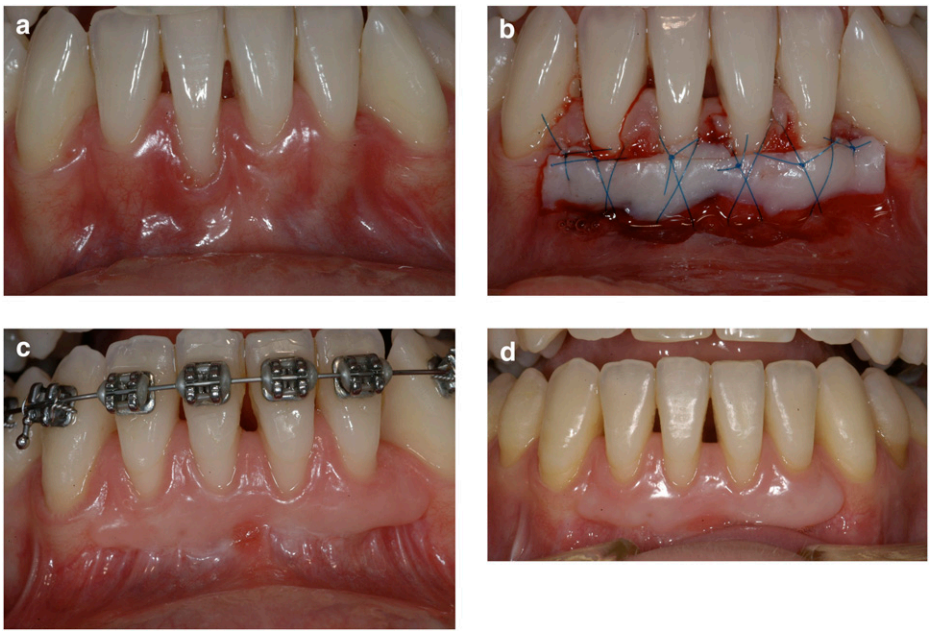

FIGURE 6 Clinical Scenario 3. FGG before orthodontic treatment. **6a** Patient with a thin biotype and lack of KT needed orthodontic treatment in which the mandibular incisors were to be tipped in a buccal direction. FGG was planned. **6b** FGG was sutured onto the periosteum without an attempt to achieve root coverage. **6c** After a period of healing of 4 months, the orthodontic treatment was started. **6d** Healing of the graft 5 years after surgery.

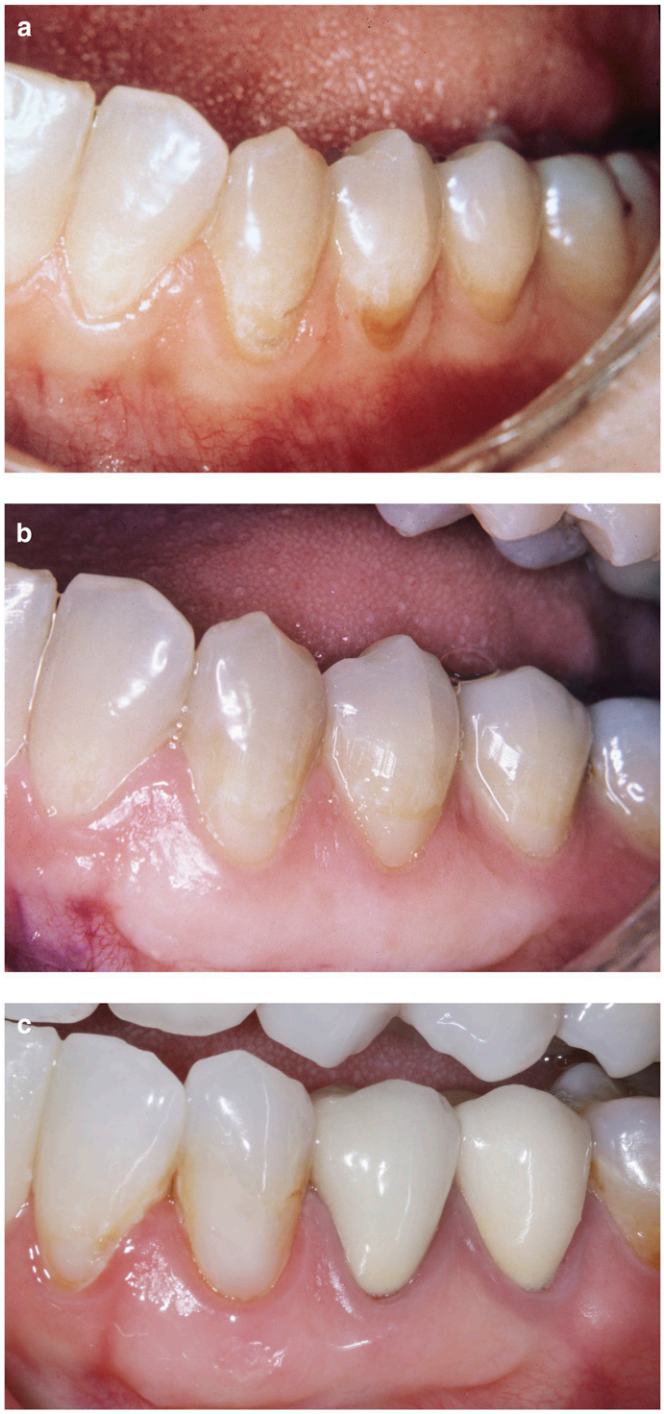

FIGURE 7 Clinical Scenario 4. FGG and restorative treatment. **7a** Multiple GRs approaching within 1 mm of the mucogingival junction on the canine and first premolar. The enamel exhibited white-spot lesions and discolored and softened cervical areas. FGG was performed before placement of the bonded restorations. A mucogingival flap was raised at the recipient site to expose the periosteum and the inter-radicular CT to provide a bleeding bed for the FGG. The roots were planed and treated with tetracycline paste. The donor site for the graft was the right palate from the second premolar to the second molar to avoid the palatal rugae. **7b** At the 10-year follow-up, the bonded restorations were still intact, and the widened band of keratinized gingiva remained stable. **7c** At the 24-year follow-up, the original bonding had been replaced by new bonding on the canine and crowns on the premolars. The tissue around FGG-treated teeth appeared healthy. The marginal gingiva of the non-treated second premolar exhibited some cyanosis.

Iowa). The patient in the videos is different from those presented in Clinical Scenarios 1 through 4.

Clinical Scenario 1

A patient presented with a shallow vestibule with evidence of marginal gingival inflammation (Fig. 4a). FGG was planned to correct the presenting GR and to serve to prevent future GR. A follow-up 27 years later shows evidence of healthy gingival KT (Fig. 4b).

Clinical Scenario 2

A patient presented for a consultation after orthognathic surgery (Fig. 5a). GR was noted in the mandibular anterior region, and the patient expressed concern with the appearance of her mandibular incisor teeth. FGG was performed to increase the zone of keratinized gingiva (Fig. 5b).

Clinical Scenario 3

A patient presented with a thin gingival biotype (Fig. 6a). She was scheduled to have orthodontic treatment. FGG was planned before orthodontic treatment to help increase the zone of keratinized gingiva (Figs. 6b through 6d).

Clinical Scenario 4

A patient presented with areas of GR that initially had bonded restorations placed (Fig. 7a). FGG was subsequently planned to increase the zone of keratinized gingiva (Figs. 7b and 7c). FGG was chosen because of its predictability.

Clinical Scenario 5

A patient presented with the complaint of tooth hypersensitivity and GR in the mandibular anterior region (Fig. 8a). The patient was interested in treatment options available to help correct these areas of GR. A free connective tissue graft (CTG) was chosen as the treatment because of the potential for a more ideal color match with the surrounding tissues (Figs. 8b through 8d).

The free CTG was described by Donn in 1978.[21] It was proposed as an alternative to the FGG. The amount of graft shrinkage has been reported to be 45% to 70%. The healed CTG usually blends with surrounding tissues better than FGG. In one study, the reported increase in KT after graft shrinkage was 5.25 mm.[22]

Clinical Scenario 6

A patient presented with minimal attached gingiva on the buccal aspect of teeth in the maxillary right quadrant (Fig. 9a). The patient was concerned about having any tissue grafting done. Accordingly, the idea of the modified apically repositioned flap (MARF) was discussed. The patient was interested in having the procedure performed (Figs. 9b and 9c).

The MARF surgical technique, which was described in 1999,[23] is an alternative surgical procedure that does not involve the placement of a graft. MARF consists of a single

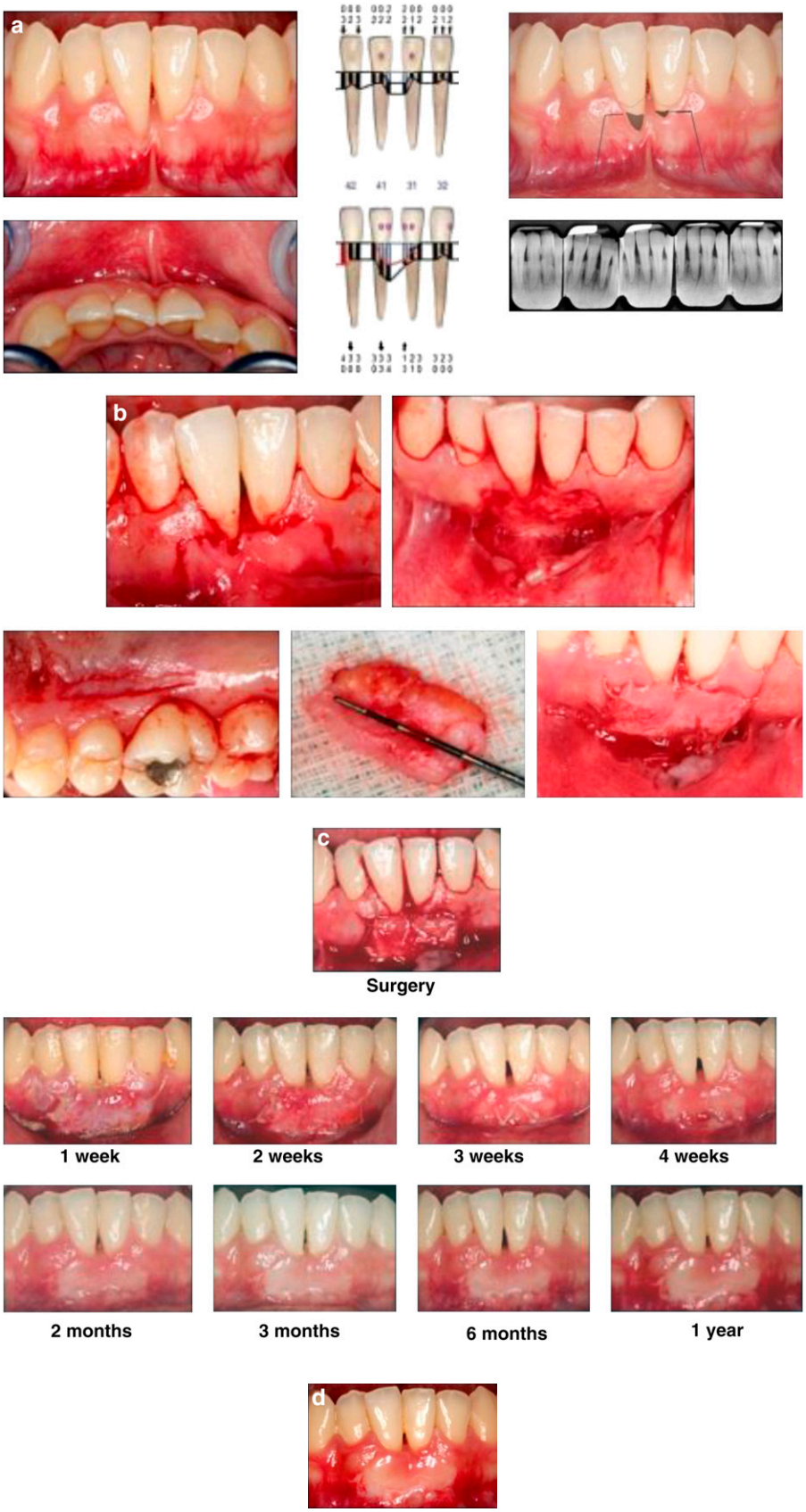

FIGURE 8 Clinical Scenario 5. Free CTG. **8a** A patient presented with Miller Class III GRs on teeth #24 and #25. The gingival margin of both teeth presented with a lack of KT and the presence of a high frenum pull. **8b** The mucogingival deformity was treated using a free CTG. **8c** In the sequence of healing events, it was noted that the epithelialization of the grafted area occurred between weeks 2 and 3. Note the maturation of the tissue between the visit at 2 months and the visit at 1 year. **8d** One year after treatment. Note the broad band of keratinized gingiva that has formed.

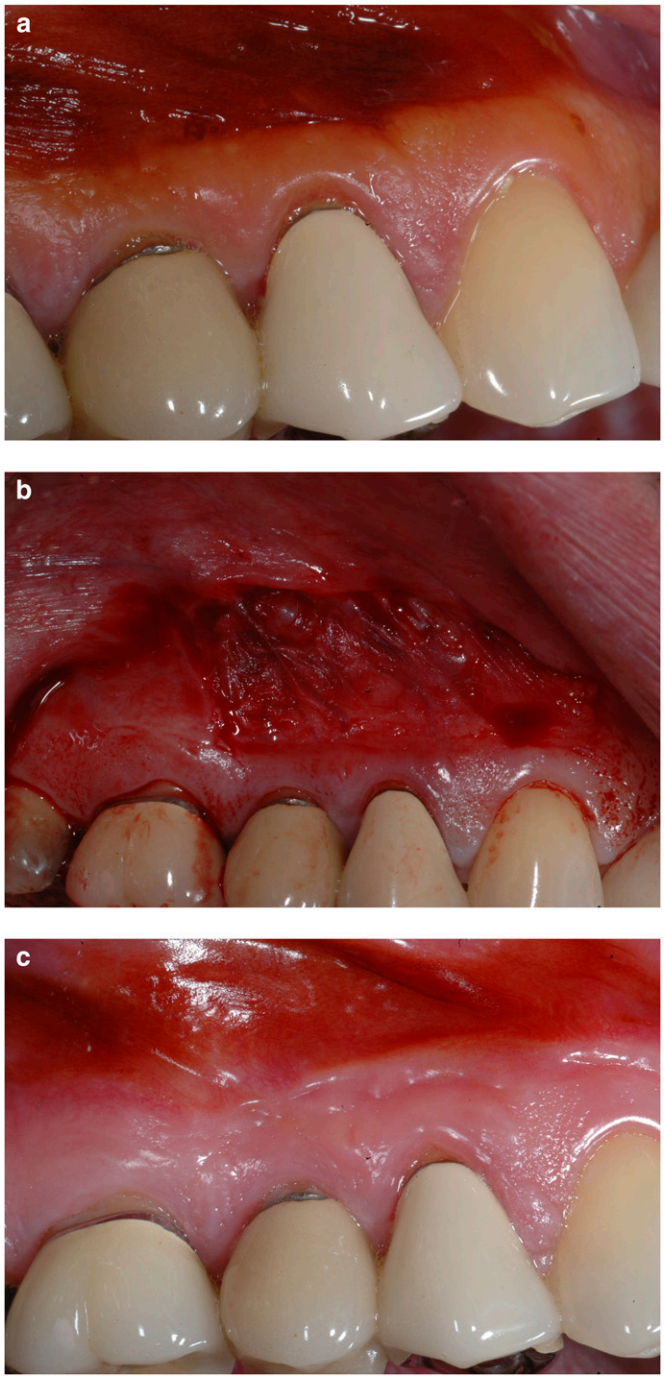

FIGURE 9 Clinical Scenario 6. MARF. **9a** A patient presented with minimal attached gingiva on the buccal aspect of tooth #5. **9b** MARF. **9c** A 6-month view stained with Schiller iodine to delineate the mucogingival junction.

horizontal incision within KT, elevation of a split-thickness flap, and suturing of the flap to the periosteum in an apical position. Previous studies reported that the amount of KT increased from a baseline mean of 2.14 ± 0.78 and 2.20 ± 0.38 mm to approximately double (4.25 ± 1.03 and 4.28 ± 0.87 mm).[23-25]

Tissue Matrices as Alternatives to Autogenous Graft Tissue for Gingival Augmentation

Alternative treatment options to autogenous graft tissue have included the use of acellular dermal matrix (ADM), extracellular matrix membrane (ECM), bilayer collagen matrix (BCM), and living cellular construct (LCC). Evidence supporting the efficacy of these alternatives is limited in most cases to a few studies of <1 year follow-up. Examples of clinical use of BCM and LCC are shown in Clinical Scenarios 7 through 9 below.

Clinical Scenario 7

A patient presented with no attached gingiva on multiple mandibular teeth with a history of progressive GR that was most severe facial to tooth #28 (Fig. 10a). BCM was selected as the treatment approach because of the involvement of multiple adjacent teeth and the desire for an esthetic outcome with blending of color and contour with surrounding tissues (Figs. 10b through 10f).

The BCM is a xenogeneic material of porcine origin. It is composed of pure Type I and III collagen. Several clinical trials have been conducted using this material. It has been reported that the tissue contour, color, and texture of the BCM-treated sites blended well with the adjacent soft tissues compared with sites that had autogenous gingival grafts used. Patient-reported outcomes were also evaluated with this technique, showing preference for this alternative therapy when compared with FGG.[26-29] Limited evidence is available on the long-term clinical response to BCM.[30]

Clinical Scenario 8

A patient presented with esthetic concerns about pigmented areas on maxillary anterior facial gingiva (Fig. 11a). A BCM approach was used (Figs. 11b through 11f).

Clinical Scenario 9

A patient presented with minimal attached gingiva on the buccal aspect of tooth #28 (Fig. 12a). A treatment approach with LCC was used (Figs. 12b through 12d).

LCC is composed of living allogenic human fibroblasts and keratinocytes, bovine collagen, and human extracellular proteins. It produces growth factors and cytokines, which are thought to influence a patient's own cells to differentiate into site-appropriate tissue. It was reported that LCC can predictably generate a clinically significant zone of KT around teeth. In addition, histologic findings showed that LCC-treated sites resembled gingiva rather than alveolar mucosa.[31-34] This product is not currently available commercially.

ADM and ECM

Clinical case examples are not shown for two additional alternative treatment approaches: ADM and ECM. ADM is an allograft tissue recovered from donor skin. Several published studies[35-38] have reported on the efficacy of ADM in gingival augmentation procedures. The use of ADM eliminates the need for a secondary surgical site. When Harris[36] compared the efficacy of FGG, CTG, and ADM in increasing the width of KT, it was found that all three surgical procedures were able to provide equivalent amounts of KT. It was also reported that color matching of ADM with the surrounding gingival tissue was very acceptable.

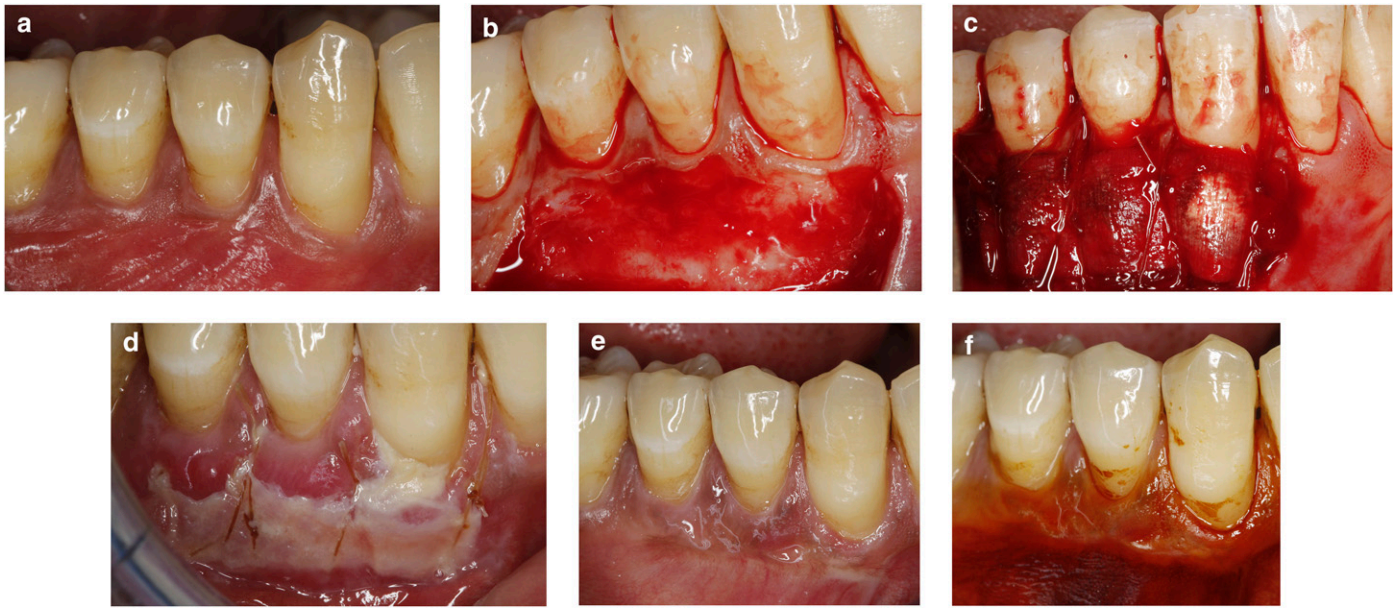

FIGURE 10 Clinical Scenario 7. BCM. **10a** A patient presented with no attached gingiva and a history of progressive GR that was most severe facial to tooth #28. **10b** A partial-thickness dissection was performed to maintain the KT at the gingival margin. Note that this procedure was not designed for root coverage. **10c** The BCM was stabilized with a resorbable plain gut 5-0 suture. **10d** A 1-week postoperative view of the site. **10e** After suture removal and removal of epithelial slough. **10f** A 6-month follow-up view displaying a functional zone of attached gingiva. Note the gingival pigmentation native to the host tissues.

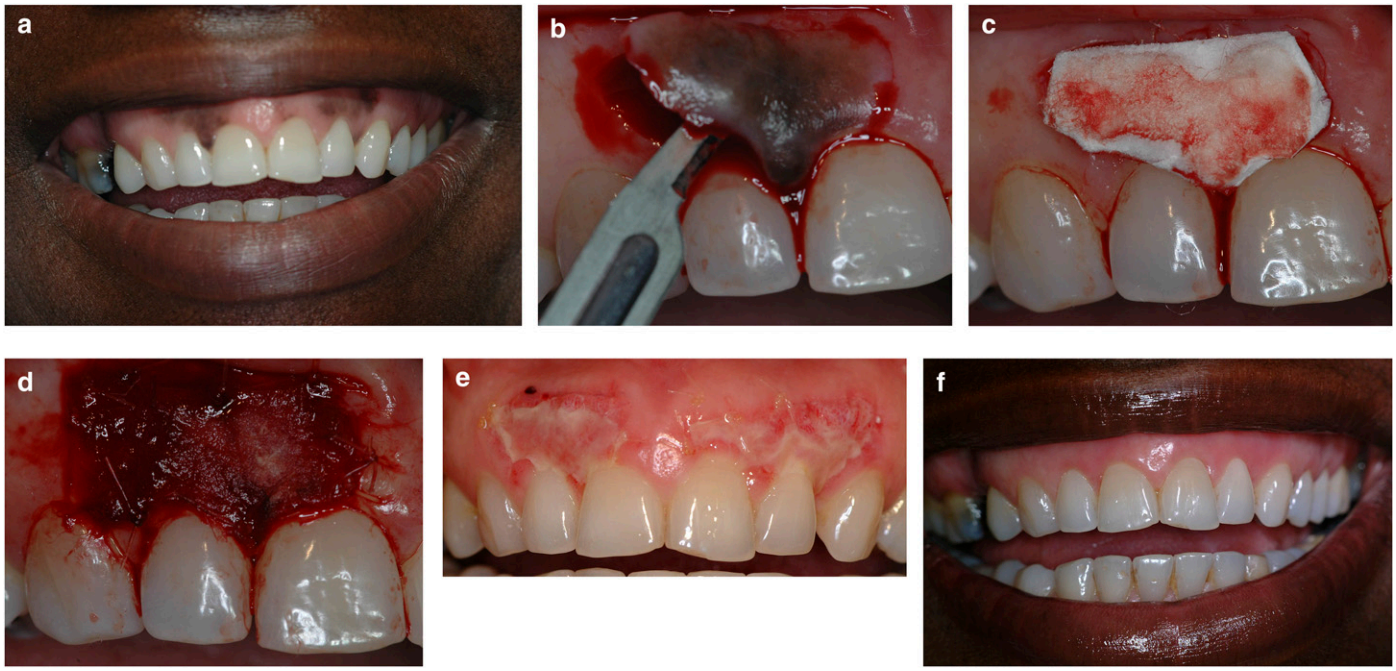

FIGURE 11 Clinical Scenario 8. Management of gingival pigmentation with BCM. **11a** Frontal view of gingival pigmentation that was bothersome to the patient. **11b** Split-thickness dissection of the pigmented tissue that was then excised. **11c** The BCM trimmed and placed into the surgically created defect. **11d** The BCM sutured into place with 5-0 plain gut sutures. **11e** One-week postoperative view. **11f** Frontal view at 6 months with favorable outcome.

ECM obtained from the submucosa of the small intestine of pigs has been evaluated for its safety, feasibility, and efficacy for providing tissue augmentation. In a randomized controlled split-mouth study with six patients presenting with <2 mm of attached gingiva bilaterally on the facial aspect of the mandibular posterior teeth, the use of autogenous gingival graft was compared with the ECM. A better color match and tissue blend were noted for the ECM-treated sites, and the histologic evaluations for both treated sites revealed mature CT covered by keratinized epithelium.[39] The surgical technique for ECM can be seen in Video 6.

Conclusions

Gingival augmentation procedures may be used successfully to manage chronic inflammation and the risk for progressive AL in sites with mucogingival deformities related to oral hygiene or prosthetic factors.

Key factors that guide the selection of treatment approaches include: 1) patient's plaque control; 2) overall compliance with

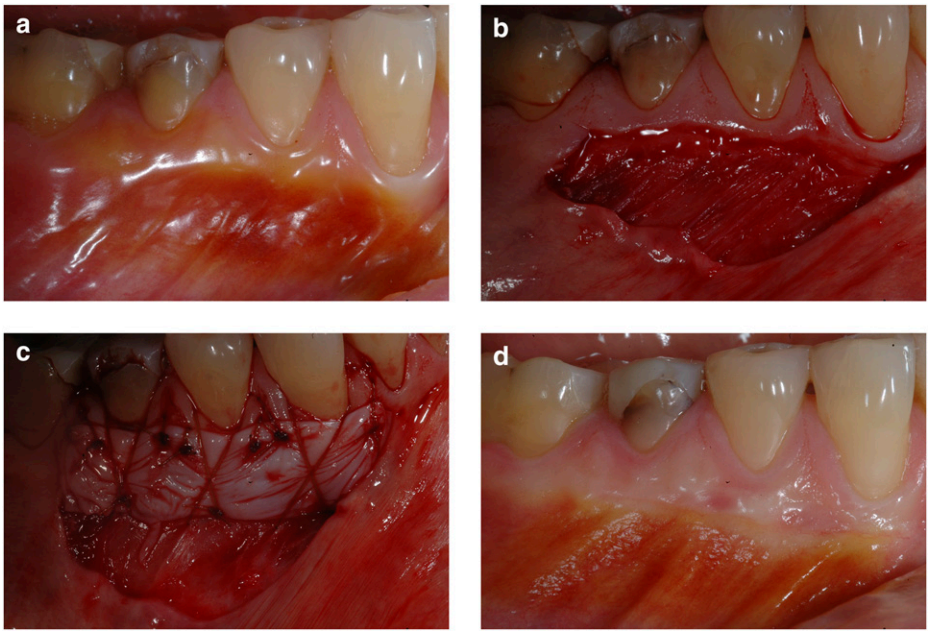

FIGURE 12 Clinical Scenario 9. LCC. **12a** A patient presented with minimal attached gingiva on the buccal aspect of tooth #28. **12b** Partial-thickness recipient bed preparation. **12c** The LCC was adapted and stabilized with 5.0 chromic sutures. **12d** Six-month view stained with Schiller iodine to delineate the mucogingival junction.

treatment recommendations; 3) presence of periodontal disease; 4) habits such as smoking; and 5) presence of systemic diseases that may modify treatment outcomes. Accordingly, the preparation of patients for mucogingival surgical procedures must include both education on oral hygiene techniques and counseling on smoking cessation.

In addition, single versus multiple sites of GR may influence the decision on using autogenous tissue or alternative treatment options. However, patients should be educated on the limitations of the alternative therapy and the lack of long-term data that would support stability of these procedures. Analyzing each clinical situation and providing the patients with the best treatment options should be the goal of the practitioner. ■

Acknowledgments

The authors thank Dr. Gustavo Avila-Ortiz, Department of Periodontics, University of Iowa, Iowa City, Iowa, for Videos 1 through 5. Dr. Rasperini has received grants and honoraria from Geistlich Pharma (Wolhusen, Switzerland) and Institute Straumann (Basel, Switzerland). Dr. Kim has received research grants and honoraria from Osteohealth (Shirley, New York), Keystone Dental (Burlington, Massachusetts), and Geistlich Pharma. Dr. Neiva has received research grants and honoraria from Organogenesis (Canton, Massachusetts), Zimmer Dental (Carlsbad, California), and OraPharma (Horsham, Pennsylvania). Dr. Greenwell has received grants and honoraria from BioHorizons (Birmingham, Alabama). Dr. Sanz has received research grants and honoraria from Biomet 3i (Palm Beach Gardens, Florida), Sunstar Americas (Chicago, Illinois), Nobel Biocare (Zürich, Switzerland), W. L. Gore & Associates (Flagstaff, Arizona), Geistlich Pharma, Institute Straumann, Organogenesis, and Zimmer Dental. Dr. Scheyer has received research grants and honoraria from Organogenesis, Geistlich Pharma, Institute Straumann, and Keystone Dental. Drs. John, Langer, and Dibart report no conflicts of interest related to this study. The 2014 Regeneration Workshop was hosted by the American Academy of Periodontology (AAP) and supported in part by the AAP Foundation, Geistlich Pharma North America, Colgate-Palmolive, and the Osteology Foundation.

CORRESPONDENCE:
Dr. Vanchit John, Indiana University School of Dentistry, Periodontics and Allied Dental Programs, 1121 West Michigan St., Indianapolis, IN 46202. E-mail: vjohn@iu.edu.

References

1. Gargiulo AW, Wentz FM, Orban B. Dimensions and relations of the dentogingival junction in humans. *J Periodontol* 1961;32:261-267.
2. Ericsson I, Lindhe J. Recession in sites with inadequate width of the keratinized gingiva. An experimental study in the dog. *J Clin Periodontol* 1984;11:95-103.
3. Nevins M. Attached gingiva — Mucogingival therapy and restorative dentistry. *Int J Periodontics Restorative Dent* 1986;6(4):9-27.
4. Sullivan HC, Atkins JH. Free autogenous gingival grafts. I. Principles of successful grafting. *Periodontics* 1968;6:121-129.
5. Sullivan HC, Atkins JH. Free autogenous gingival grafts. 3. Utilization of grafts in the treatment of gingival recession. *Periodontics* 1968;6:152-160.
6. McGuire MK, Scheyer ET, Nunn ME, Lavin PT. A pilot study to evaluate a tissue-engineered bilayered cell therapy as an alternative to tissue from the palate. *J Periodontol* 2008;79:1847-1856.
7. Nevins M, Becker W, Kornman K. Proceedings of the World Workshop in Clinical Periodontics. Chicago: American Academy of Periodontology;1989:VII-1-VII-21.
8. Miller PD Jr. A classification of marginal tissue recession. *Int J Periodontics Restorative Dent* 1985;5(2):8-13.
9. Kim DM, Neiva R. Periodontal soft tissue non–root coverage procedures: A systematic review from the AAP Regeneration Workshop. *J Periodontol* 2015;86(Suppl. 2):S56-S72.
10. Scheyer ET, Sanz M, Dibart S, et al. Periodontal soft tissue non–root coverage procedures: A consensus report from the AAP Regeneration Workshop. *J Periodontol* 2015;86(Suppl. 2):S73-S76.
11. Kosyfaki P, del Pilar Pinilla Martín M, Strub JR. Relationship between crowns and the periodontium: A literature update. *Quintessence Int* 2010;41:109-126.
12. Waerhaug J. Tissue reactions around artificial crowns. *J Periodontol* 1953;54:172-185.
13. Silness J. Periodontal conditions in patients treated with dental bridges. 2. The influence of full and partial crowns on plaque accumulation, development of gingivitis and pocket formation. *J Periodontal Res* 1970; 5:219-224.
14. Nevins M, Skurow HM. The intracrevicular restorative margin, the biologic width, and the maintenance of the gingival margin. *Int J Periodontics Restorative Dent* 1984;4(3):30-49.
15. Lang NP, Löe H. The relationship between the width of keratinized gingiva and gingival health. *J Periodontol* 1972;43:623-627.
16. Miller PD Jr. Root coverage using the free soft tissue autograft following citric acid application. Part III. A successful and predictable procedure in areas of deep-wide recession. *Int J Periodontics Restorative Dent* 1985; 5(2):14-37.
17. Iacopino AM. Diabetic periodontitis: Possible lipid-induced defect in tissue repair through alteration of macrophage phenotype and function. *Oral Dis* 1995;1:214-229.
18. Kennedy JE, Bird WC, Palcanis KG, Dorfman HS. A longitudinal evaluation of varying widths of attached gingiva. *J Clin Periodontol* 1985;12:667-675.
19. Lindhe J, Marynard G Jr., Miller PD, et al. Consensus report. Mucogingival therapy. *Ann Periodontol* 1996;1:702-706.
20. James WC, McFall WT Jr. Placement of free gingival grafts on denuded alveolar bone. Part I: Clinical evaluations. *J Periodontol* 1978;49:283-290.
21. Donn BJ Jr. The free connective tissue autograft: A clinical and histologic wound healing study in humans. *J Periodontol* 1978;49:253-260.
22. Orsini M, Orsini G, Benlloch D, Aranda JJ, Lázaro P, Sanz M. Esthetic and dimensional evaluation of free connective tissue grafts in prosthetically treated patients: A 1-year clinical study. *J Periodontol* 2004;75: 470-477.
23. Carnio J, Miller PD Jr. Increasing the amount of attached gingiva using a modified apically repositioned flap. *J Periodontol* 1999;70:1110-1117.
24. Carnio J, Camargo PM. The modified apically repositioned flap to increase the dimensions of attached gingiva: The single incision technique for multiple adjacent teeth. *Int J Periodontics Restorative Dent* 2006;26:265-269.
25. Carnio J, Camargo PM, Passanezi E. Increasing the apico-coronal dimension of attached gingiva using the modified apically repositioned flap technique: A case series with a 6-month follow-up. *J Periodontol* 2007;78:1825-1830.
26. Sanz M, Lorenzo R, Aranda JJ, Martin C, Orsini M. Clinical evaluation of a new collagen matrix (Mucograft prototype) to enhance the width of keratinized tissue in patients with fixed prosthetic restorations: A randomized prospective clinical trial. *J Clin Periodontol* 2009;36:868-876.
27. Nevins M, Nevins ML, Kim SW, Schupbach P, Kim DM. The use of mucograft collagen matrix to augment the zone of keratinized tissue around teeth: A pilot study. *Int J Periodontics Restorative Dent* 2011;31: 367-373.
28. McGuire MK, Scheyer ET. Randomized, controlled clinical trial to evaluate a xenogeneic collagen matrix as an alternative to free gingival grafting for oral soft tissue augmentation. *J Periodontol* 2014;85:1333-1341.
29. McGuire MK, Scheyer ET, Gwaltney C. Commentary: Incorporating patient-reported outcomes in periodontal clinical trials. *J Periodontol* 2014;85:1313-1319.
30. Cochran DL, Cobb CM, Bashutski JD, et al. Emerging regenerative approaches for periodontal reconstruction: A consensus report from the AAP Regeneration Workshop. *J Periodontol* 2015;86(Suppl. 2): S153-S156.
31. McGuire MK, Scheyer ET, Nevins ML, et al. Living cellular construct for increasing the width of keratinized gingiva: Results from a randomized, within-patient, controlled trial. *J Periodontol* 2011;82:1414-1423.
32. Nevins ML. Tissue-engineered bilayered cell therapy for the treatment of oral mucosal defects: A case series. *Int J Periodontics Restorative Dent* 2010;30:31-39.
33. Morelli T, Neiva R, Nevins ML, et al. Angiogenic biomarkers and healing of living cellular constructs. *J Dent Res* 2011;90:456-462.
34. Scheyer ET, Nevins ML, Neiva R, et al. Generation of site-appropriate tissue by a living cellular sheet in the treatment of mucogingival defects. *J Periodontol* 2014;85:e57-e64.
35. Scarano A, Barros RR, Iezzi G, Piattelli A, Novaes AB Jr. Acellular dermal matrix graft for gingival augmentation: A preliminary clinical, histologic, and ultrastructural evaluation. *J Periodontol* 2009;80:253-259.
36. Harris RJ. Clinical evaluation of 3 techniques to augment keratinized tissue without root coverage. *J Periodontol* 2001;72:932-938.
37. Wei PC, Laurell L, Lingen MW, Geivelis M. Acellular dermal matrix allografts to achieve increased attached gingiva. Part 2. A histological comparative study. *J Periodontol* 2002;73:257-265.
38. Gapski R, Parks CA, Wang HL. Acellular dermal matrix for mucogingival surgery: A meta-analysis. *J Periodontol* 2005;76:1814-1822.
39. Nevins M, Nevins ML, Camelo M, Camelo JM, Schupbach P, Kim DM. The clinical efficacy of DynaMatrix extracellular membrane in augmenting keratinized tissue. *Int J Periodontics Restorative Dent* 2010;30:151-161.