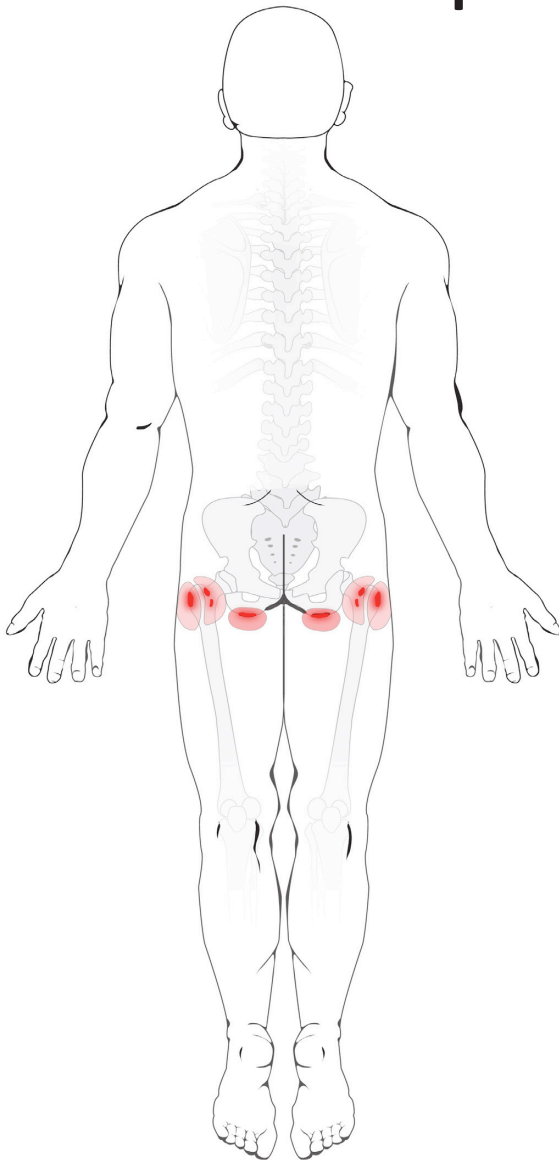


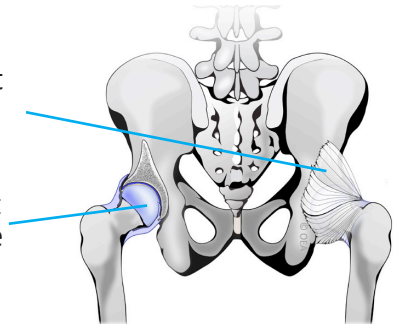
Hip Bursitis



Normal Anatomy

Hip Joint Capsule

Hip Joint Cartilage

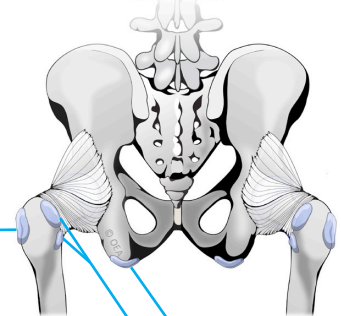


Normal Hip Bursae

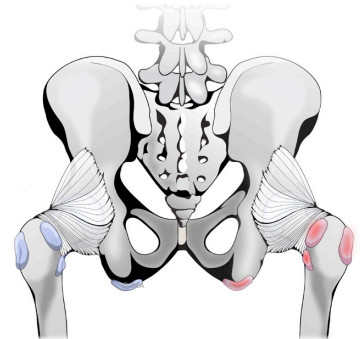
Trochanteric Bursa

Gluteal Bursae

Ischial Bursa



Inflamed Hip Bursae



ROCK NAVARKAL, M.D., J.D.

Double Board Certified • Fellowship Trained
Pain Medicine • Sports Medicine • Electrodiagnostic Medicine



Rocky Mountain
Spine & Sports Medicine

Cherry Creek Office
Cherry Creek Plaza II
650 S. Cherry St., Suite 1015
Denver, CO 80246

Phone: 303-377-7777
Fax: 303-377-7775
Email: rock@denverpainmd.com
Website: www.denverpainmd.com