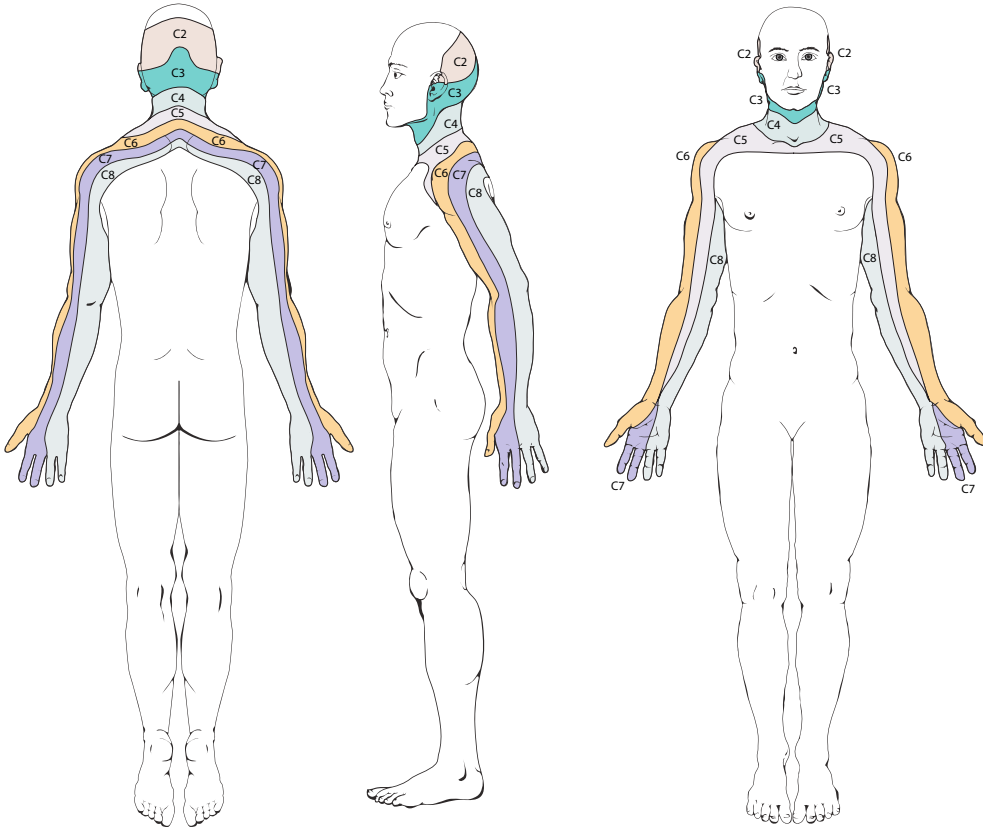
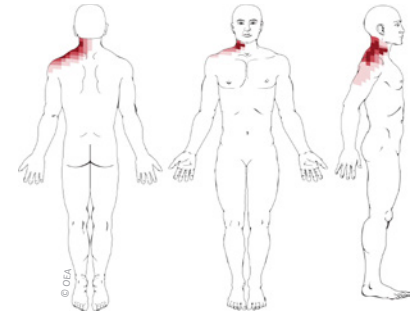


Cervical Radicular Pain Patterns

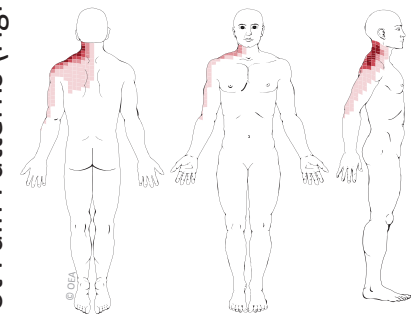


Cervical Dermatomes: Nerve Root Numbness Patterns (above)

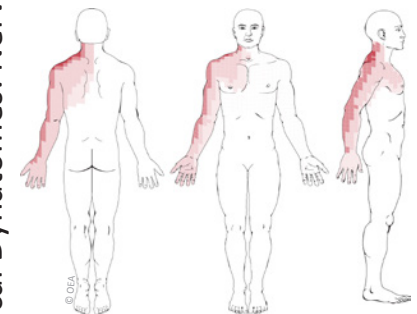
Based on: Slipman CW et al. Symptom provocation of fluoroscopically guided cervical nerve root stimulation. Are dynatomal maps identical to dermatomal maps? *Spine*. 1998;23:2235-42.



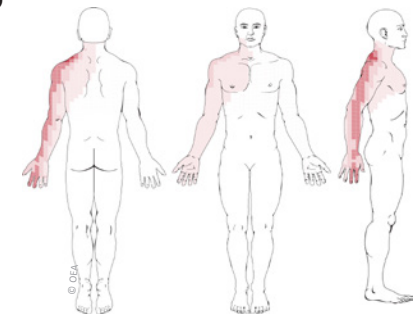
C4 Nerve Root Pain Pattern



C5 Nerve Root Pain Pattern

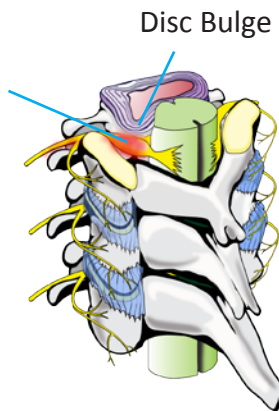


C6 Nerve Root Pain Pattern



C7 Nerve Root Pain Pattern

Cervical Dynatomes: Nerve Root Pain Patterns (right)



ROCK NAVARKAL, M.D., J.D.
 Double Board Certified • Fellowship Trained
 Pain Medicine • Sports Medicine • Electrodiagnostic Medicine



Cherry Creek Office
 Cherry Creek Plaza II
 650 S. Cherry St., Suite 1015
 Denver, CO 80246

Phone: 303-377-7777
 Fax: 303-377-7775
 Email: rock@denverpainmd.com
 Website: www.denverpainmd.com