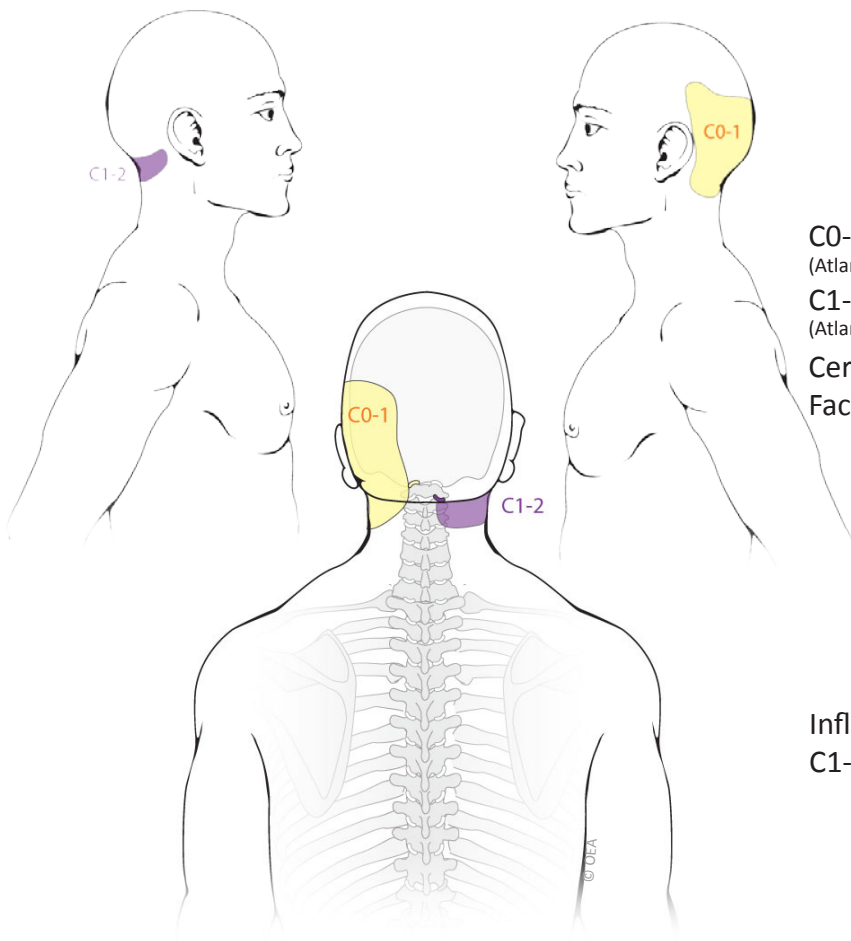
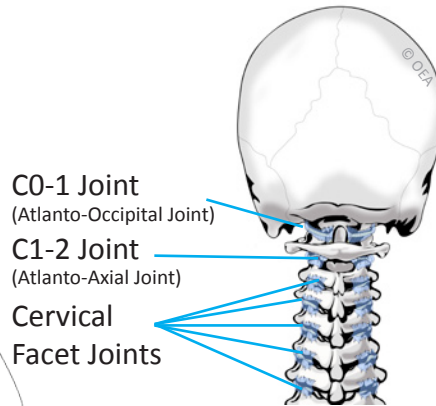


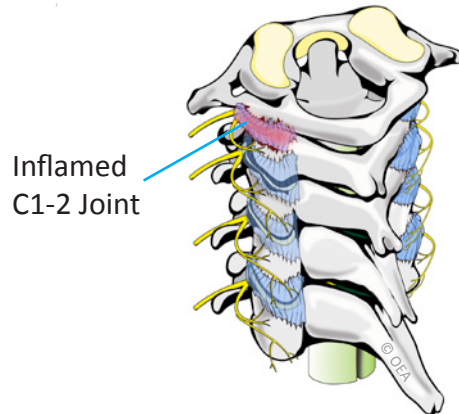
C0-1 and C1-2 Joint Pain Patterns



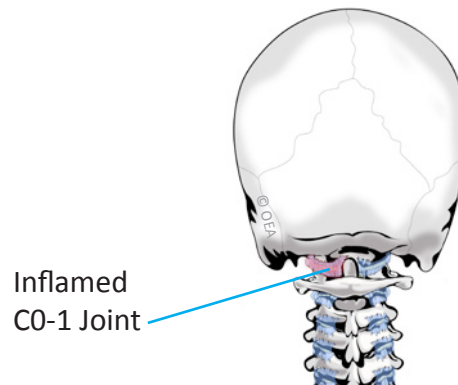
Normal Anatomy



C1-2 Synovitis



C0-1 Synovitis



Based on: Dreyfuss P, Michaelsen M, Fletcher D. Atlanto-occipital and lateral atlanto-axial joint pain patterns. *Spine*. 1994; 19(10):1125-31.

ROCK NAVARKAL, M.D., J.D.

Double Board Certified • Fellowship Trained
Pain Medicine • Sports Medicine • Electrodiagnostic Medicine



Cherry Creek Office
Cherry Creek Plaza II
650 S. Cherry St., Suite 1015
Denver, CO 80246

Phone: 303-377-7777
Fax: 303-377-7775
Email: rock@denverpainmd.com
Website: www.denverpainmd.com