Osteochondral Reconstruction of the Capitellum

Brent J. Morris, MD[a,*], Casey J. Kiser, MD[a], Hussein A. Elkousy, MD[a], J. Michael Bennett, MD[b], Thomas L. Mehlhoff, MD[a]

KEYWORDS

• Osteochondritis dissecans • Capitellum • Osteochondral reconstruction • OATS

KEY POINTS

- Osteochondritis dissecans of the capitellum is a localized inflammatory condition in adolescent patients who participate in repetitive overhead sports and upper extremity weightbearing activities.
- Lesions can be described as stable or unstable depending on the stability of the articular surface, with stable lesions being susceptible to nonoperative treatment and unstable lesions necessitating surgical intervention.
- Various surgical interventions have been described including drilling of the lesion, fragment excision with drilling, fragment fixation, reconstruction with autograft plug, autologous chondrocyte implantation, and closing wedge osteotomy.
- The posterior anconeus muscle splitting approach to elbow with reconstruction of the lesion using an autograft plug from the ipsilateral knee is our preferred treatment for an unstable lesion failing nonoperative treatment.

INTRODUCTION

Osteochondritis dissecans (OCD) of the capitellum, first described by König in 1888,[1] is an idiopathic, localized inflammatory pathologic condition affecting the subchondral bone and overlying cartilage in the capitellum. The exact cause is unknown; however, this injury is most commonly attributed to repetitive microtrauma from valgus compression-type injuries of the immature capitellar articular cartilage causing vascular insufficiency. Ultimately, localized necrosis and subchondral bone changes can occur, with cartilage fragmentation after loss of mechanical support.[2,3] Loss of articular cartilage from the donor site and mechanical wear from the loose body can lead to early arthritic changes. Genetic predisposition to this injury may be possible; however, this is as yet unconfirmed.

CAUSE

- Largely unknown, multiple theories
- Repetitive mechanical trauma
- Disruption of blood supply to small areas of the bone
- Disruption of enchondral ossification

OCD of the capitellum is a fairly uncommon condition with an incidence of 2.2 per 100,000 in adolescent patients.[4] It is most often seen in patients aged 12 to 16 years who participate

[a] Fondren Orthopaedic Group, TERFSES Shoulder and Elbow Fellowship, Texas Orthopedic Hospital, 7401 South Main Street, Houston, TX 77030, USA; [b] Fondren Orthopaedic Group, 7401 South Main Street, Houston, TX 77030, USA

* Corresponding author.

E-mail address: brent.joseph.morris@gmail.com

Orthop Clin N Am ■ (2019) ■–■

https://doi.org/10.1016/j.ocl.2019.08.004

in repetitive overhead sports and upper extremity weightbearing activities, with baseball and football players, as well as gymnasts, being the most commonly affected patients.[4] Often, this is seen in the dominant extremity and has a higher prevalence in boys with a boy:girl ratio of 6.4:1.[4]

Most often these patients present with insidious, activity-related elbow pain on the lateral aspect of the elbow in the dominant arm.[5] Common complaints include mechanical symptoms and or loss of full extension.[5] The patient may complain of catching or locking symptoms in advanced disease with loose bodies. On physical examination, the patient typically has lateral elbow tenderness to palpation, a small effusion, and mild loss of extension, as well crepitus or catching with range of motion in advanced disease.

SYMPTOMS

- Elbow pain with activity, relieved with rest
- Loss of motion, especially loss of full extension
- Swelling
- Mechanical symptoms such as grinding, catching, locking, and clicking

PHYSICAL EXAMINATION FINDINGS

- Tenderness laterally
- Loss of extension
- Swelling

IMAGING

Patients who present with clinical examination findings and subjective history consistent with that of an OCD lesion should initially have an anteroposterior (AP) and lateral radiograph of the elbow to evaluate for any irregular ossification or bony defects (Fig. 1). In addition, a 45° AP flexion view[6] can be helpful. Contralateral elbow radiographs can be valuable for comparative imaging. In more advanced disease, a crater of rarefaction in the capitellum may be present and usually has a sclerotic rim of subchondral bone adjacent to the articular surface.[7] Advanced imaging is often indicated to better identify and classify the lesion. We prefer both a computerized tomography (CT) and an MRI scan in these cases. A CT scan is essential in defining the bony anatomy underlying the cartilage defect and to look for loose bodies, whereas an MRI is ideal to assess the extent of the osteochondritis and determine if a lesion is unstable (Fig. 2). We also perform an AP or

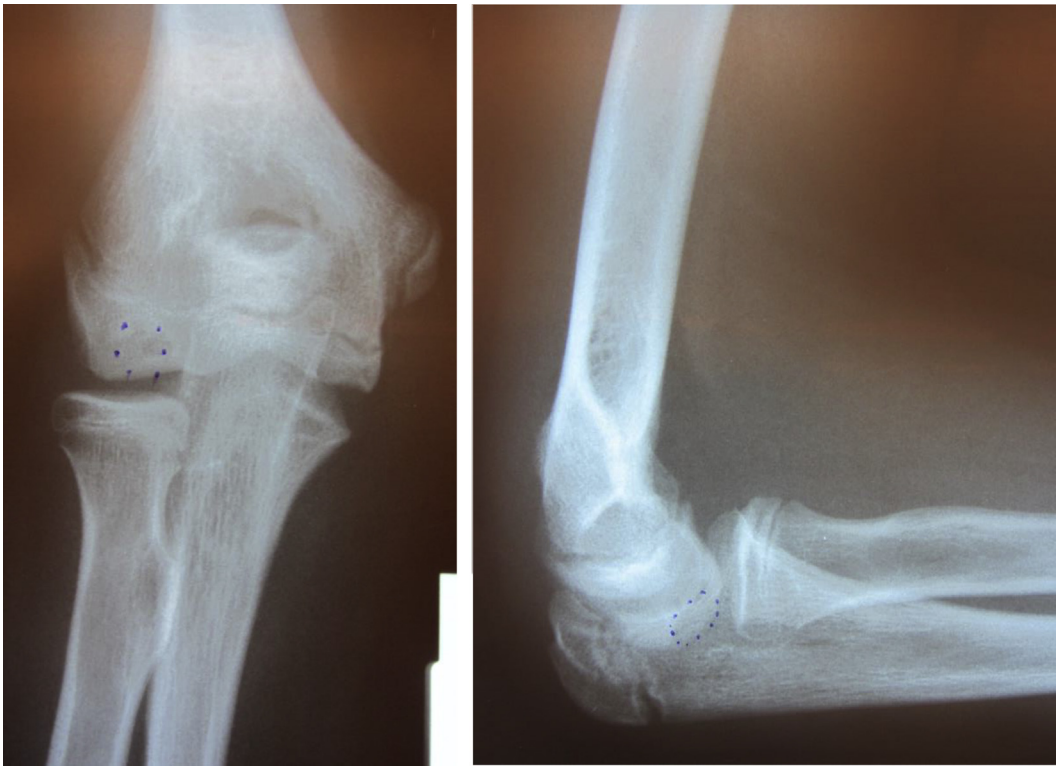

Fig. 1. AP and lateral radiographs of the elbow with the osteochrondral defect of the capitellum outlined.

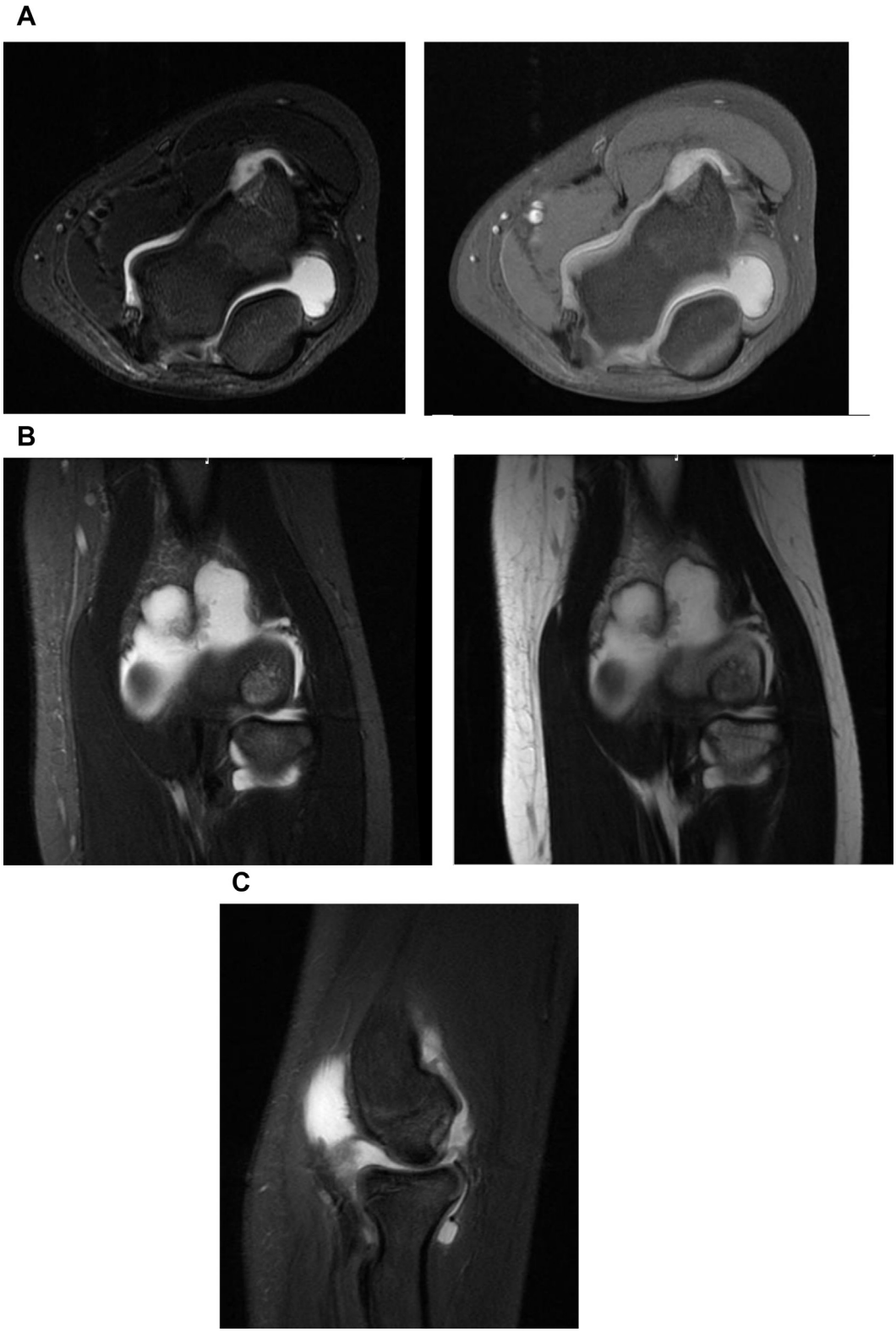

Fig. 2. (*A*) T1 and T2 MRI axial images showing a large unstable osteochondral defect of the capitellum. (*B*) T1 and T2 MRI coronal images showing a large unstable osteochondral defect of the capitellum. (*C*) T2 MRI axial image showing a large unstable osteochondral defect of the capitellum.

tunnel view and lateral radiograph of the ipsilateral knee (Fig. 3) to assess the distal femoral physis and rule out any bony abnormalities in anticipation of autograft harvest from the non-weightbearing portion of the lateral trochlea of the femur.

Plain radiographs
- AP
- Lateral
- 45° AP flexion view[6]
- Contralateral elbow views for comparison
- AP and lateral of the ipsilateral knee

MRI
CT

CHARACTERIZING THE OSTEOCHONDRITIS DISSECANS LESION

Although there are multiple classifications of OCD lesions of the elbow, the Takahara classification is most commonly used.[6] Stable capitellar OCD lesions were defined in patients with open physes, low-grade radiographic changes, and maintained range of motion of the elbow. These patients responded to nonoperative measures in the reported series.[6] Unstable capitellar OCD lesions were defined in patients with closed physes, higher-grade radiographic changes, and restriction of elbow motion greater than 20°. The patients in the series responded better to surgery.[6] Unfortunately, no capitellar OCD classification system has been shown to accurately predict healing or direct appropriate treatment.

- Stable lesion—articular cartilage intact
  - Open growth plates
  - Normal elbow motion without mechanical elbow symptoms
  - Radiographic lucency without fragmentation or loose body visualized on plain films
  - MRI reveals intact articular cartilage
- Unstable lesion "in situ"—unstable cartilage flap
- Unstable lesion "displaced"—loose body
  - Mechanical symptoms
  - Restricted elbow motion greater than 20°
  - Closing or closed physis
  - Failed nonoperative management

TREATMENT

The treatment approach for this uncommon problem ranges from nonoperative treatment in stable lesions to various surgical treatment options. Many surgical treatment options have been described including microfracture, loose

Fig. 3. AP and lateral radiograph of the knee. It is necessary to assess the distal femoral physis and rule out any bony abnormalities in anticipation of autograft harvest from the non-weightbearing portion of the lateral trochlea of the femur.

body removal, abrasion chondroplasty, lesion fixation, isolated osteochondral allograft transplantation surgery (OATS), autologous chondrocyte implantation, lateral condyle closing wedge osteotomy and OATS for larger, unstable lesions. Our preferred surgical treatment option for unstable OCD lesions of the capitellum is a novel surgical technique with osteochondral autologous transplantation surgery using an autograft from the ipsilateral knee.

Stable OCD lesion
- Rest
- Cessation of the repetitive stress across the elbow
- Stretching and strengthening exercises
- Return to activities when pain free and radiographs confirm a healed lesion

Unstable OCD lesion
- Surgical intervention
  - Drilling of the lesion
  - Fragment removal with or without curettage or drilling of the residual defect
  - Fragment fixation by a variety of methods
  - Reconstruction with osteochondral autograft (knee)—our preferred technique
  - Autologous chondrocyte implantation
  - Closing wedge osteotomy of the lateral condyle

INDICATIONS/CONTRAINDICATIONS

The primary indication for surgical intervention for an OCD of the capitellum reconstruction with an OATS procedure includes larger unstable lesions of the capitellum (usually 8–12 mm). Contraindications for surgical treatment of OCD lesions of the capitellum include stable lesions, traumatic cartilage shear injuries, and Panner disease. Panner disease is osteochondrosis of the capitellum that occurs primarily in young boys under 10 years and can often be confused with OCD of the capitellum. Panner disease is a self-limiting condition that is treated nonoperatively. Atypically large size may be a relative contraindication for our particular autograft procedure because the largest bone harvester is 10 mm. Atypically large OCD lesions can be potentially treated with a combination of 2 autograft plugs; however, this is not our preferred treatment option given concern for possible inconsistent healing when using 2 plugs. Our preferred treatment method for larger defects (>10 mm in diameter) is to apply the autograft to the area of most concern within the lesion.

Indications

Unstable Lesions
Lesions not responding to conservative measures

Contraindications

Stable lesions
Panner disease (osteochondrosis of the capitellum)
Traumatic cartilage shear injuries
Size too large (>10 mm) is a relative contraindication for autograft, given that 10 mm is the largest bone harvester/autograft plug size, but placement of the graft in the area of most concern is a viable treatment option.

Surgical technique/procedure

Preoperative planning. Preoperative planning must include performance of all relevant imaging, including radiographs (elbow and ipsilateral knee), CT, and MRI as noted above once the patient has been deemed a surgical candidate for capitellar OATS. Coordination is key to the intraoperative plan between the elbow specialist and the knee specialist for knee autograft harvesting.

Preparation and patient positioning. The patient is placed in the supine position with an arm table (Fig. 4). The ipsilateral leg is left exposed. The patient is anesthetized with general anesthesia. No peripheral nerve blocks are performed. A nonsterile tourniquet is placed on both the upper and lower extremity. The entire arm and leg are prepped and draped (Fig. 5). The procedure can be performed

Fig. 4. The patient is placed in the supine position with an arm table and the ipsilateral leg left exposed.

Fig. 5. The entire arm and leg are prepped and draped. Nonsterile tourniquets are placed on both the upper and lower extremities.

Fig. 7. Skin incision is made with the elbow in full flexion.

simultaneously with a second surgeon for autograft harvest from the knee once proper sizing of the capitellar OCD lesion has been determined. Alternatively, in the absence of a knee surgeon for autograft harvest from the knee, the surgeon can start with exposure of elbow and transition to the knee for harvest once proper sizing of the lesion has been determined.

Surgical approach elbow and host site preparation. The upper extremity tourniquet is insufflated at 200 mm Hg. Our technique is a posterior anconeus muscle-splitting approach, originally described by Iwasaki and colleagues.[8] A 4.5-cm oblique incision is used at the posterior aspect of the flexed operative elbow from the ulnar shaft to the lateral epicondyle using the ulnar shaft, lateral epicondyle, and ulnar tip as the 3 key bony landmarks (Fig. 6). The skin is incised while the elbow is in full flexion (Fig. 7). Subcutaneous tissue is divided to expose the fascia of the anconeus muscle. The fascia is incised longitudinally. The anconeus is spread to expose the posterior capsule (Fig. 8), which is incised longitudinally to enter the joint (Fig. 9). The joint is examined for any synovitis, which is sharply resected if present. At this point the articular cartilage over the capitellum is visualized and closely scrutinized. The unstable flap of articular cartilage is sharply resected to expose the lesion (Fig. 10). The margins of the lesion are sharply debrided to ensure only normal cartilage remains. The lesion is then sized using sizing guides to determine the best match for the defect (Fig. 11). Core decompression of the lesion is begun at this point first by inserting the matching harvester sizing cylinder (Fig. 12). The proper-sized cannulated sizing cylinder is placed into the defect and the guide pin is inserted through the sizing cylinder. The sizing

Fig. 6. A 4.5-cm oblique incision is used at the posterior aspect of the flexed operative elbow from the ulnar shaft to the lateral epicondyle, using the ulnar shaft, lateral epicondyle, and ulnar tip as the 3 key bony landmarks.

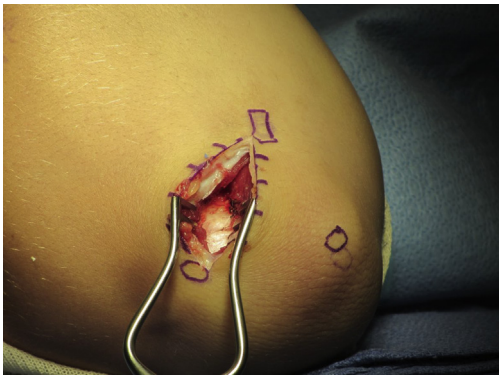

Fig. 8. The approach starts with dividing the subcutaneous tissue to expose the fascia of the anconeus muscle. The fascia is incised longitudinally. The anconeus is spread to expose the posterior capsule.

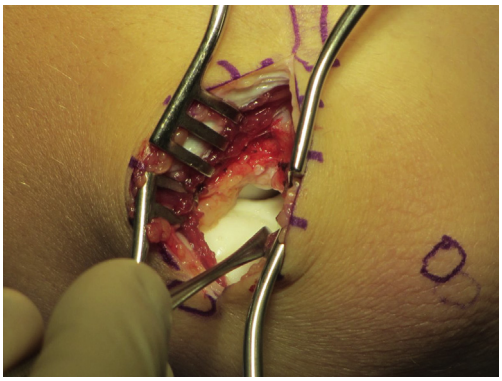

Fig. 9. The posterior capsule is incised longitudinally to enter the joint. A freer is marking the unstable cartilage lesion.

cylinder ensures that the guide pin is centered within the defect and perpendicular to the defect (Fig. 13). This is confirmed with visual inspection. Attention is then turned to autograft harvest from the knee.

Elbow Approach and Host Site Preparation

1. A 4.5-cm oblique incision with the elbow in full flexion
2. Expose the anconeus fascia and incise longitudinally
3. Elbow joint capsule is exposed and incised longitudinally to enter the joint
4. Sharply debride any synovitis, remove loose bodies, and excise the unstable flap
5. Determine the size of the defect with the sizing guide
6. Place a guide pin for core decompression using the proper-sized cannulated sizing cylinder and visually confirm the guide pin is centered with the lesion

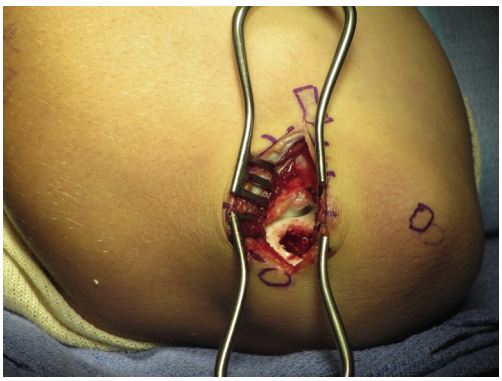

Fig. 10. The unstable flap of articular cartilage is sharply resected to expose the capitellar OCD lesion. The margins of the OCD lesion are sharply debrided to ensure that only normal cartilage remains.

Fig. 11. The capitellar OCD lesion is sized using sizing guides to determine the best match for the defect.

Fig. 12. Core decompression of the lesion is completed at this point first by inserting the matching harvester sizing cylinder. The proper-sized cannulated sizing cylinder is placed into the defect and the guide pin is inserted through the sizing cylinder.

Fig. 13. The sizing cylinder ensures that the guide pin is centered within the defect and perpendicular to the defect.

Fig. 14. The graft harvest is performed through a 5-cm longitudinal incision made on the lateral aspect of the patella.

Surgical approach ipsilateral knee and autograft harvesting. Attention is then turned to autograft harvest from the ipsilateral knee. The lower extremity tourniquet is insufflated at 300 mm Hg and a 5-cm longitudinal incision is made on the lateral aspect of the patella (Fig. 14). Dissection is performed down to the superficial retinaculum, which is then split perpendicular to its fibers. The deep retinaculum is then identified and split. The capsule is identified and sharply split vertically to expose the lateral trochlea. At this point the OATS harvester is placed proximal to the sulcus terminalis in the non-weightbearing articular surface of the lateral trochlea of the knee and the graft is subsequently harvested. The diameter of the plug is based on the size of the capitellar lesion; however, the depth depends on the proximity of the graft harvest site to the physis. The typical harvest depth is around 10–12 mm; however, this may be modified if the location of the harvest is near the physis. The harvest site is then remeasured and an allograft plug, oversized by 1 mm in diameter, is used to fill the defect (Fig. 15) and impacted into place ensuring the graft is flush with the surrounding articular surface.

1. Approach to the non-weightbearing portion of the lateral trochlea of the ipsilateral knee
2. Graft harvester is used to extract the autograft of the proper size and to a depth that safely avoids the physis
3. A size-matched allograft plug is placed to backfill the knee harvest site

Fig. 15. An allograft plug is used to backfill the donor site defect ensuring that the graft is placed flush with the surrounding articular surface.

Core decompression and autograft insertion. Attention is turned back to the capitellum. The cannulated reamer corresponding to the diameter of the defect is then passed over the previously placed guide pin, removing dead bone with a core decompression to a depth typically around 10–12 mm; however, this is altered based on the autograft depth harvested from the knee (Fig. 16). The sizing cylinder is placed into the reamed defect to confirm the depth of the defect. The core decompression site is closely examined to ensure that healthy cancellous bone remains and that there is healthy surrounding articular cartilage.

The autograft plug is then brought to the elbow and fashioned with a rongeur to address any high or low areas and to match the proper depth. The autograft plug is oriented with the high side to the lateral direction to match the native anatomy. The harvester is then positioned at the site of the core decompression site and the graft is advanced into the previously reamed channel (Fig. 17). The graft is initially left 2–3 mm proud (Fig. 18) after being deployed from the harvester, and then final tapping of the graft is performed with the sizers to ensure

Fig. 17. The autograft plug is oriented with the high side to the lateral direction to match the native anatomy. The harvester is then positioned at the site of the core decompression site and the graft is advanced into the previously reamed channel.

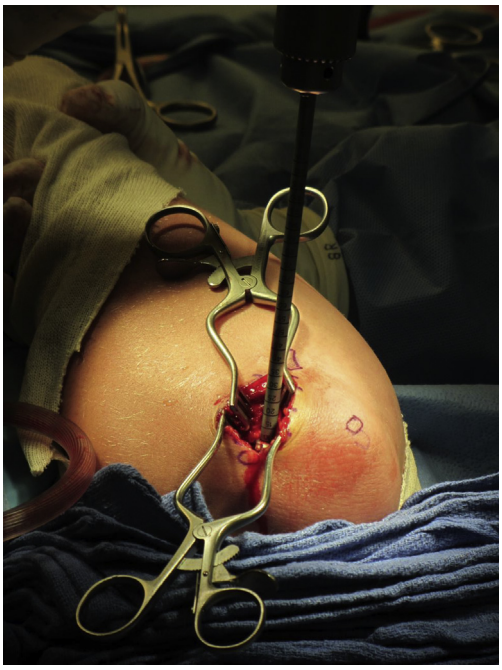

Fig. 16. The cannulated reamer corresponding to the size of the defect is passed over the guide pin, removing dead bone with a core decompression to a depth typically around 10–12 mm depending on the size of the autograft plug harvested from the knee.

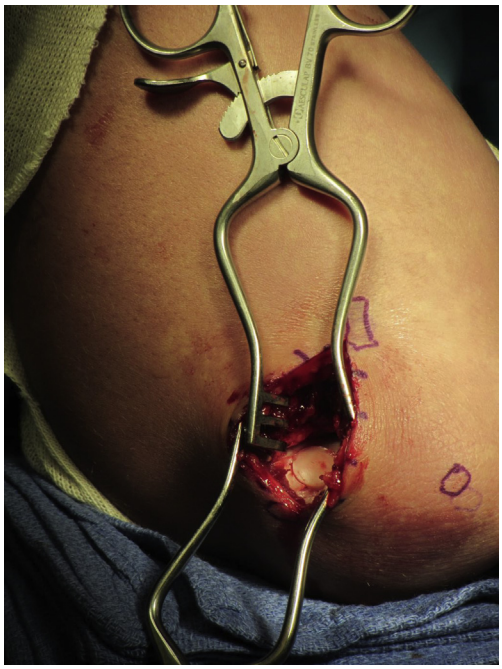

Fig. 18. The graft is initially left 2–3 mm proud after being deployed from the harvester.

Fig. 19. Final tapping of the graft is performed with the sizers to ensure a perfect match with the articular cartilage of the capitellum.

a perfect match with the articular cartilage of the capitellum (Figs. 19 and 20). Range of motion is assessed after final graft seating to ensure full flexion, extension, pronation, and supination without mechanical impingement on the graft.

1. Autograft plug is fashioned with rongeur and depth is noted
2. Ream over the guide pin with the size-matched cannulated reamer to the proper depth and remove the guide pin
3. Graft is deployed into the core decompression site by advancing the graft with the harvester and initially leave 2–3 mm proud
4. Final insertion of the graft using sizer as an impactor
5. Ensure the graft is perfectly flush with the articular surface
6. Confirm elbow range of motion and no mechanical impingement on the graft

Fig. 20. Final autograft implant flush with surrounding articular surface.

Surgical wound closure

Both surgical wounds are thoroughly irrigated. The elbow capsule is closed with interrupted nonabsorbable 3-0 suture with the knots buried. The anconeus muscle is allowed to fall back into position and the overlying fascia is closed with interrupted nonabsorbable 3-0 sutures with the knots buried (Fig. 21). The overlying skin is closed with a deep absorbable 4-0 suture and a subcutaneous absorbable 5-0 subcuticular running suture, followed by interrupted 6-0 nylon sutures for the skin. The wound is dressed and the patient is placed in a well-padded posterior slab splint in 90° of flexion and neutral rotation.

The knee closure begins with the deep portion of the retinaculum being only partially closed to prevent lateral patellar compression syndrome. The superficial retinaculum is also left open. The deep skin layer is closed with an

Fig. 21. The elbow capsule is closed with an interrupted nonabsorbable 3-0 suture with the knots buried. The anconeus muscle is allowed to fall back into position and the overlying fascia is closed with interrupted nonabsorbable 3-0 sutures with the knots buried.

absorbable suture with the superficial skin closed with a running subcuticular absorbable suture. A soft sterile dressing is applied. No bracing or splint is used for the knee.

COMPLICATIONS

- Infection
- Graft failure
- Nerve symptoms
- Contracture
- Recurrent loose bodies
- Donor site pain
- Recurrent mechanical pain

Complications following this procedure are rare, but those to consider include infection, graft failure, nerve symptoms, contracture, recurrent loose bodies, donor site pain, and recurrence of mechanical symptoms. Fortunately, complications in our patient series have been rare. One patient did experience painless crepitus at the radiocapitellar joint despite excellent radiographic appearance, otherwise no other complications have been reported to date in our small series.

Elbow Postoperative Care

At 1 week postoperatively the elbow splint is removed and a removable splint is placed at 90°, and the patient is allowed to begin a gentle range of motion protocol at home. At 2 weeks postoperatively, the nylon sutures are removed and the patient is placed in a range of motion elbow brace with continued focus on range of motion for 6 weeks and allowing full elbow range of motion in the brace. At 8 weeks postoperatively, elbow radiographs are obtained to ensure healing of the graft, and elbow strengthening can start 12 weeks postoperatively. The patient is progressed in their activity to tolerance, but specifically restricted from doing push-ups and resisted elbow extension. Return to sport is typically allowed at the 6-month postoperative time frame.

Knee Postoperative Care

Regarding the knee, the postoperative protocol includes initially allowing the patient to be weightbearing as tolerated. The authors encourage the patient to do home exercises including quadriceps sets and heel slides. After the first postoperative knee appointment at the 2-week mark, the patient is allowed to begin using a stationary bike and progress to low-impact activities for 6 to 8 weeks postoperatively. We allow the patient to gradually transition to running, jumping, and high-impact activities at around the 3-month postoperative mark.

Outcomes

Preliminary data from our center following OATS autograft from the ipsilateral knee for an unstable OCD lesion of the capitellum include 16 adolescent athletes (14 boys and 2 girls) with an average age of 14.2 years (12–16 years) and 1-year minimum follow-up. Autograft plug sizes were 6,[2] 8,[7] and 10 mm.[7] Thirteen patients had excellent results using a modified Timmerman and Andrews scoring system,[9] 2 patients had a good result, and 1 patient had a fair result (painless radiocapitellar crepitus as noted above). Range of motion improved in all patients with symmetric range of motion noted in all patients at final follow-up. There were no intraoperative elbow or knee complications in our series. Two patients did have further elbow surgery unrelated to their OATS procedure. One patient had an elbow arthroscopy 4 years after OATS for recurrent elbow joint synovitis, and one patient had an ulnar collateral ligament reconstruction 4 years after OATS. There were no other postoperative elbow complications. There were *no* reported complications secondary to the ipsilateral knee harvest site. There were no revision surgeries secondary to graft malpositioning, dislocation, or recurrent OCD lesions.

SUMMARY

OCD lesions of the capitellum are uncommon, but can occur in adolescents, especially athletes in overhead sports. Our preferred surgical technique for the treatment of unstable OCD lesions of the capitellum is osteochondral autologous transplantation surgery using autograft from the ipsilateral knee. The authors prefer a supine position and a posterior anconeus muscle splitting approach with the elbow in flexion to address the capitellar OCD lesion. We have been pleased with our series of patients using this approach with minimal complications and excellent early outcomes.

REFERENCES

1. Churchill R, Munoz K, Ahmad C. Osteochondritis dissecans of the elbow. Curr Rev Musculoskelet Med 2016;9(2):232–9.
2. Douglas G, Rang M. The role of trauma in the pathogenesis of the osteochondrosis. Clin Orthop Relat Res 1981;158:28–32.
3. Takahara M, Ogino T, Takagi M, et al. Natural progression of the osteochondritis dissecans of the humeral capitellum: initial observations. Radiology 2000;216:207–12.

4. Kessler J, Jacobs J, Cannamela P, et al. Demographics and epidemiology of osteochondritis dissecans of the elbow among children and adolescents. Orthop J Sports Med 2018;6(12). 2325967118815846.
5. McManama G, Michel L, Berry MV, et al. The surgical treatment of osteochondritis of the capitellum. Am J Sports Med 1985;13(1):11–21.
6. Takahara M, Mura N, Sasaki J, et al. Classification, treatment, and outcome of osteochondritis dissecans of the humeral capitellum. J Bone Joint Surg Am 2007;89(6):1205–14.
7. Shaughnessy WJ. Osteochondritis dissecans. In: Morrey BF, Sanchez-Sotelo J, Morrey ME, editors. Morrey's the elbow and its disorders. 5th edition. Philadelphia: Elsevier; 2018. p. 341–8.
8. Iwasaki N, Kato H, Ishikawa J, et al. Autologous osteochondral mosaicplasty for osteochondritis dissecans of the elbow in teenage athletes. J Bone Joint Surg Am 2009;91(10):2359–66.
9. Timmerman LA, Andrews JR. Arthroscopic treatment of posttraumatic elbow pain and stiffness. Am J Sports Med 1994;22:230–5.