

PATIENT HISTORY

60-year-old female presented with many problems, including a deep osseous defect on the mesial of #11 canine and mesial of tooth #3. She had full mouth osseous surgery 15 – 20 years previously and swore that she would never have surgery again. Patient reported poor health, but no significant major concerns, was on medications to control high blood pressure and cholesterol.

TISSUE CONDITION

Perio pocketing found throughout, BOP throughout, spongy tissues – all gingival tissues were inflamed. She had significant occlusal trauma with heavy fremitus. Mobility was evident on most teeth.

TREATMENT APPROACH

The LANAP[®] protocol was performed on Feb. 11, 2011. Thorough occlusal adjustment was done to eliminate heavy centric and lateral forces. Patient was seen for follow-up on 2/26/11 & 3/11/11 to refine occlusal pressures. On 4/1/11, further occlusal adjustment and delivery of dual arch deprogrammers to stabilize her bite.

RESULTS

Patient reported no pain or swelling as the result of the LANAP[®] procedure. Two years later found significant bone regeneration visible on X-ray. Patient's mouth was found to be immaculate; her home care had dramatically improved because she was now motivated. Previous dentists never addressed her occlusal discrepancies. Broad osseous defect on mesial of #11 appears to have significant bone fill. A significant regeneration on the mesial of #3 was noted.



ABOUT THE AUTHOR: ALVIN DANENBERG, DDS

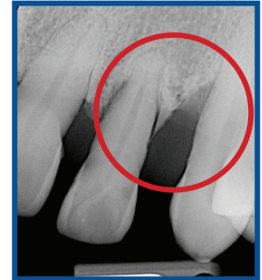Dr. Dan, as his patients call him, has been a periodontist for over four decades. He divides his career into two periods: before and after the laser, coupled with the dynamics of ancestral nutrition. The laser-based

LANAP[®] protocol and the importance of ancestral nutrition, he believes, are revolutionizing the treatment of gum disease. His Power Nutrition Program, based on evolutionary nutrition, assists patients in eliminating unhealthy lifestyle routines and poor food choices by replacing them with healthy ones. The body needs nutrient-dense foods and healthy gut bacteria to create amazing results. Poor nutrition and unhealthy gut bacteria lead to various medical and dental diseases and imbalances.

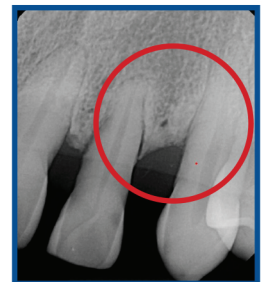SEE MORE
LANAP RESULTS



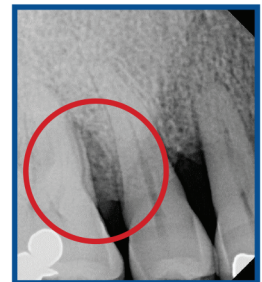SCAN
QR CODE



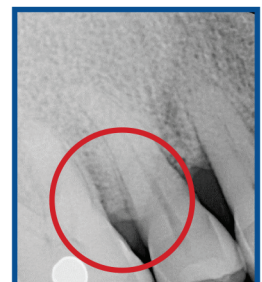
Pre-Op: #11
Mesial Probe Depths
10, 10



2 Years Post-Op:
Probing Depths
3, 3



Pre-Op:
10, 10



2 Years Post-Op:
4, 3