

# Diagnosis of Atlantoaxial Instability Requires Clinical Suspicion to Drive the Radiological Investigation

Fraser C Henderson Sr.<sup>1,2\*</sup> and Fraser C Henderson Jr.<sup>3</sup>

<sup>1</sup>Doctors Community Hospital, Lanham, MD, USA

<sup>2</sup>The Metropolitan Neurosurgery Group, LLC, Chevy Chase, MD, USA

<sup>3</sup>Medical University of South Carolina, Charleston, SC, USA

## Introduction

Atlantoaxial instability (AAI) occurs as a result of trauma, congenital conditions such as os odontoideum, neoplasm, infection and degenerative connective tissue disorders such as rheumatoid arthritis, genetic conditions such as HOX-D3 and Down syndrome, and heritable connective tissue disorders, emblematic of which are the Ehlers Danlos syndromes (EDS). Prototypical of disorders in which AAI is diagnosed, is rheumatoid arthritis (RA). Prior to the development of effective disease-modifying pharmacotherapies, 88% of RA patients exhibited radiographic evidence of C1-C2 involvement, in whom 49% were symptomatic and 20% myelopathic; ultimately, 10% may have suffered atlantoaxial dislocation and death [1-3].

In their report on pediatric patients undergoing C1-C2 transarticular screw fixation Gluf and Brockmeyer noted approximately one third of the cases of AAI resulted from trauma, one third from os odontoideum, and one third from congenital conditions such as Down syndrome, Stihl disease, dwarfism, Morquio syndrome, Klippel-Feil and others. Three patients were thought to have chronic instability, most likely to have resulted from ligamentous laxity, possibly EDS [4,5].

The diagnosis of AAI is not difficult in the presence of an abnormal ADI (Figure 1), but may be elusive in those cases where the transverse ligament is intact, and where there is incompetence of one or both the alar ligaments. In these cases, the diagnosis may require dynamic imaging and concordant clinical findings.

## Etiology of Atlantoaxial Instability

Traumatic flexion of the neck may result in injury to the transverse odontoid ligaments and alar ligaments. An atlanto-dental interval (ADI) over 3 mm suggests possible instability in adults; an ADI exceeding 5 mm suggests instability in children. An ADI of 7 mm suggests rupture or incompetence of the transverse ligament, and/or of the cruciate ligament, and an ADI of 10 mm suggests loss or incompetence of the alar ligaments as well [6]. However, if the transverse ligament is intact, the ADI is normal despite the presence of alar ligament incompetence.

A proclivity to ligamentous incompetence renders the atlantoaxial joint at higher risk for instability. The atlantoaxial junction (AAJ) is the most mobile joint of the body. Held together by ligaments that allow a great degree of freedom of rotation, the AAJ is responsible for 50% of all neck rotation, 5° of lateral tilt, and 10° to 20° of flexion/extension [7]. It is not surprising therefore, that connective tissue disorders, such as Down syndrome and EDS, are more frequently visited by AAI. Motor delay [8,9], headache associated with "connective tissue pathological relaxation" and quadriparesis are attributed to ligamentous laxity and instability at the atlanto-occipital and atlantoaxial joints [10,11]. While the epidemiology of AAI in EDS-hypermobile type is unknown, AAI was seen in two thirds of patients with EDS-Vascular type [11]. A high risk of AAI is apparent in other connective tissue disorders, including 11% of Down syndrome patients [12].

The AAJ mechanical properties are determined by ligamentous structures [13,14], most prominent of which are the transverse and alar ligaments [15]. The alar ligaments limit axial rotation and lateral

bending to the contralateral side, are often injured in motor vehicle collisions, and could be implicated in whiplash-associated disorders [15]. Failure of the alar ligament allows a 30% increased rotation to the opposite side [16]. The atlantoaxial joint is ill-equipped to handle the required multi-axial movements in the presence of ligamentous laxity or disruption [17]. Weakness of the muscles and ligaments, hormonal changes, infection, immunological problems, and congenital dysmorphism may contribute to the overall mechanical dysfunction at the C1-C2 motion segment.

Hypermobility of the AAJ is common in children, and up to 45° of rotation may be observed in each direction. However, in the adult there is substantially less than 40° of rotation [17-20]: at 35° of rotation of C1 upon C2 there is stretching and kinking of the contralateral vertebral artery [20]; at 45°, both vertebral arteries become occluded [21].

## Diagnostic Findings

Diagnosis of AAI is based upon careful history, a detailed neurological exam and imaging of the upper cervical spine. The most common clinical features are neck pain and suboccipital headache, with the caveats that headache is present in 50% of patients with EDS [22], and that moderate pain is a common occurrence for most EDS patients. There may be symptoms referable to the vertebral artery blood flow, including visual changes, as well as headache associated with the vertebral artery itself. Syncopal and presyncopal events are frequent. Other symptoms include dizziness, nausea, sometimes facial pain, dysphagia, choking, and respiratory issues. There is usually improvement with a neck brace. Examination often demonstrates tenderness over C1-C2, altered mechanics of neck rotation, hyperreflexia, dysdiadochokinesia, hypoesthesia to pinprick. Weakness is not a constant feature of AAI [4,23-27].

Radiological features may show atlanto-dental interval (ADI) >2.5 mm in an adult, or 5 mm in a child, on lateral flexion x-rays (Figure 1) or rotation of C1 upon C2 >41° [4,28] (Figure 2). Excessive rotation occurs opposite to the side of an incompetent alar ligament. Alar ligament incompetence is the most frequent cause of AAI in the population of patients with hypermobility connective tissue disorders [4]. Thus diagnosis of AAI in EDS, or related connective tissue disorders, is best made with supine computerized tomography (CT), from occiput to C2, with full neck rotation (90° if possible) to left and to right. (Figure 2) The difficulty of recognizing rotary instability on standard x-ray, CT and MRI images has resulted in failure to diagnose [29].

\*Corresponding author: Fraser Cummins Henderson Sr., M.D., 8401 Connecticut Avenue, Suite 220, Chevy Chase, MD 20815, USA, Tel: 301-654-9390; Fax: 301-654-9394; E-mail: [Henderson@FraserHendersonMD.com](mailto:Henderson@FraserHendersonMD.com)

Received March 25, 2017; Accepted March 30, 2017; Published April 01, 2017

Citation: Henderson Sr. FC, Henderson Jr. FC (2017) Diagnosis of Atlantoaxial Instability Requires Clinical Suspicion to Drive the Radiological Investigation. J Spine 6: 364. doi: [10.4172/2165-7939.1000364](https://doi.org/10.4172/2165-7939.1000364)

Copyright: © 2017 Henderson Sr. FC, et al. This is an open-access article distributed under the terms of the Creative Commons Attribution License, which permits unrestricted use, distribution, and reproduction in any medium, provided the original author and source are credited.

In the hypermobility disorders, there may be abnormal facet overlap on full neck rotation <20% [30,31] (Figure 3); lateral translation of the facet joints: translation in aggregate >7 mm on coronal imaging as seen on open mouth odontoid views. Open mouth odontoid views are very effective in identifying AAI [32] (Figure 4).

Dvorak showed in cadavers that the mean axial rotation between the axis and the second cervical vertebra was 31.1°, increasing to 35° after contralateral rupture of the alar ligament; CT imaging thus demonstrated increased angular rotation of 4° to the side opposite the alar ligament injury [16].

The diagnosis of AAI can sometimes be seen on three dimensional CT, where there may be a clear demonstration of subluxation [31]. Increased ligament signal intensity on high-resolution proton density-weighted MRI may be seen, with the caveats that alar ligaments of asymptomatic patients may show high signal intensity, and that there is variable inter-examiner reliability of MRI evaluation [33]. Other radiological indications of AAI include compromise of the vertebral arteries based upon abnormal mechanics at the C1-C2 junction; anomalous joints; retro-odontoid pannus [23,27,34] (Table 1).

### Criteria for Surgery

The decision to proceed to surgery rests upon the presence of severe neck or suboccipital pain, the presence of cervical medullary syndrome or syncopal (or pre-syncopal) episodes, demonstrable neurological findings and radiological evidence of instability or compression of the neuraxis.

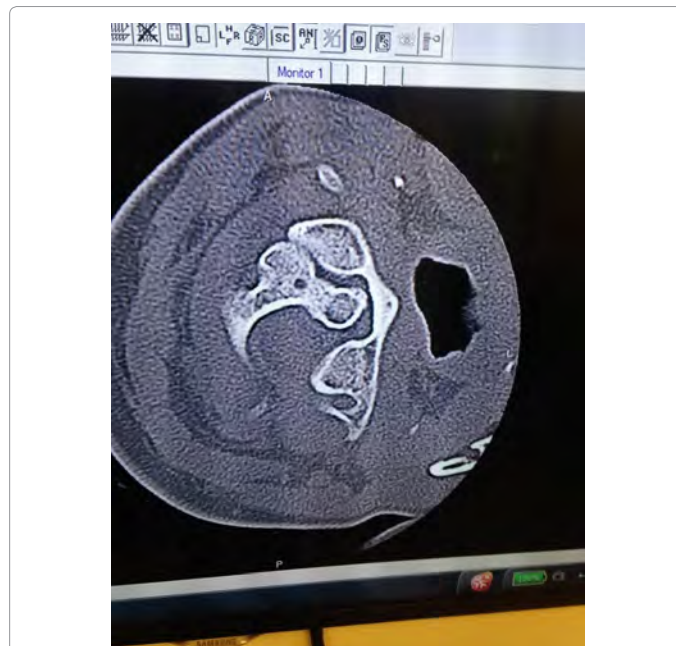

Figure 3: Axial CT scan through C1-C2 showing loss of facet overlap on full neck rotation, consistent with AAI.

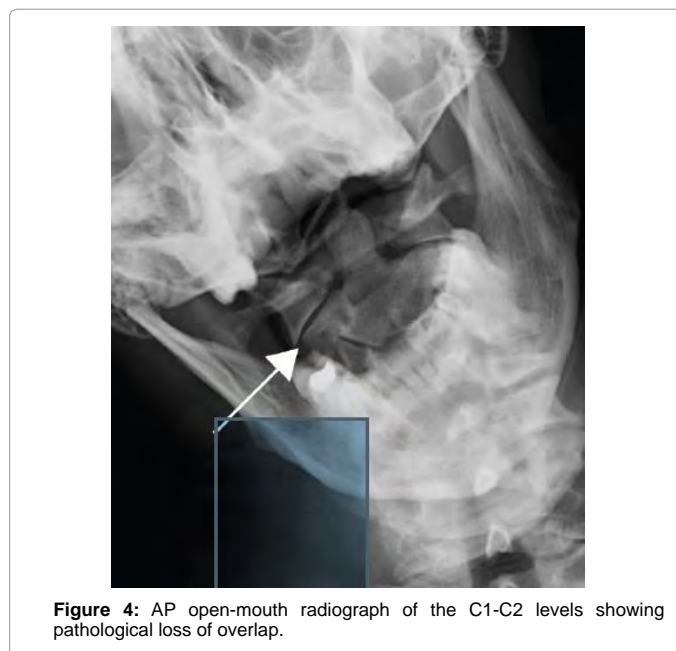


Figure 4: AP open-mouth radiograph of the C1-C2 levels showing pathological loss of overlap.

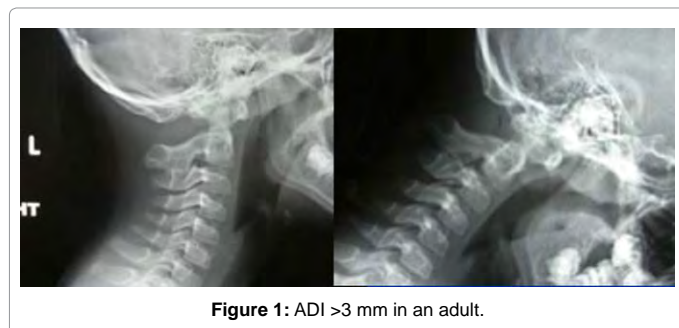


Figure 1: ADI >3 mm in an adult.

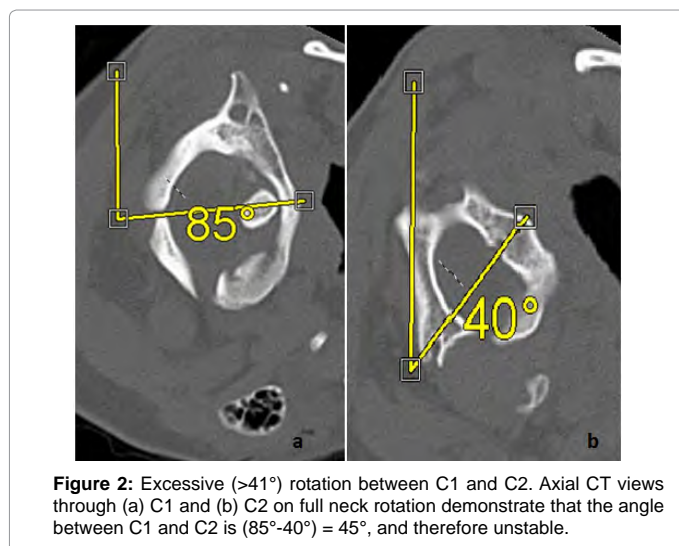


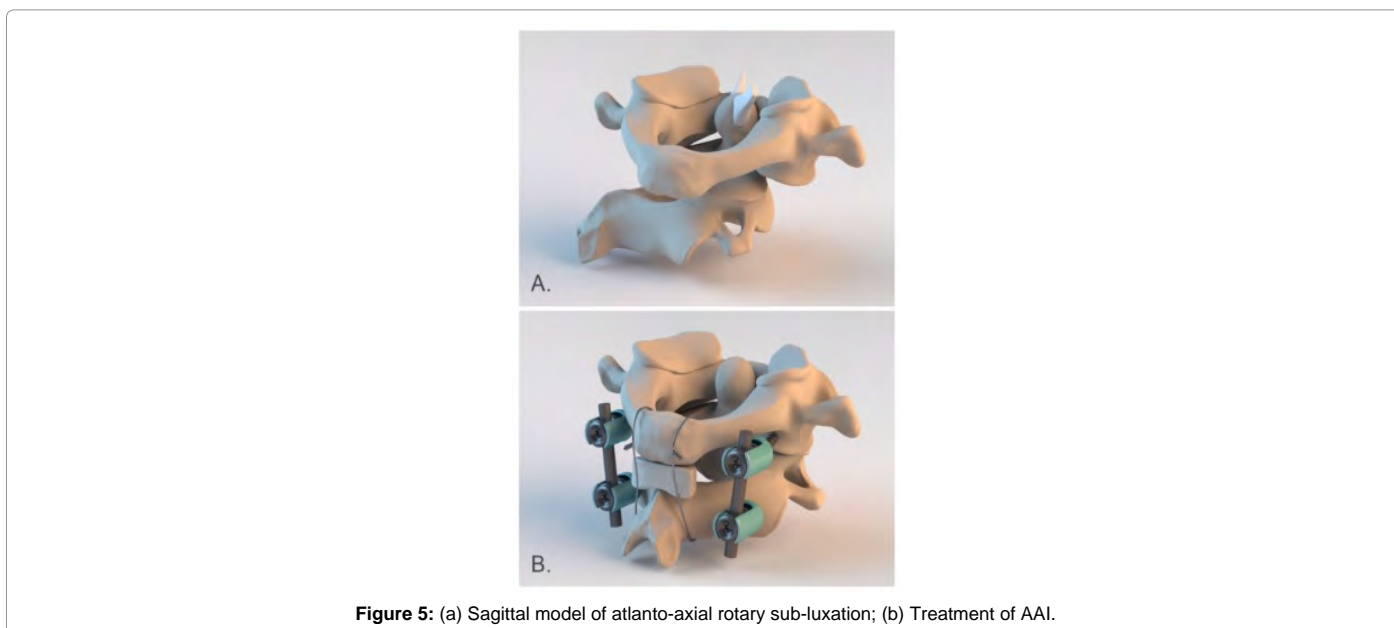
Figure 2: Excessive (>41°) rotation between C1 and C2. Axial CT views through (a) C1 and (b) C2 on full neck rotation demonstrate that the angle between C1 and C2 is (85°-40°) = 45°, and therefore unstable.

### Treatment

For milder form of instability, the patient should be considered for treatment with neck brace, physical therapy and avoidance of activities that provoke exacerbation of the AAI symptoms. If the non-operative treatment fails, fusion-stabilization at C1-C2 is required. Failure of any of the components of the atlantoaxial ligament complex requires dorsal surgical fusion [35]. This is most often accomplished with posterior screw constructs, transarticular screw fixation [24], or C1-C2 lateral mass/pedicle screws and interposed graft [4,25,26] (Figure 5). Aberrant vertebral artery anatomy may preclude the desired screw placement in 18% to 23% of patients [36,37], and the surgery may be complicated in EDS by small bone architecture.

ADI (Atlanto-dental interval) >3 mm in an adult, or 5 mm in a child, on lateral flexion x-rays.
Lateral translation of the facet joints: translation in aggregate >7 mm on coronal imaging as seen on open mouth odontoid views. Open mouth odontoid views are very effective in identifying AAI [32].
Rotation of C1 upon C2, >41° [4,28] (Figure 1).
Facet overlap on full neck rotation <20% [30,31] (Figure 2).
Greater than 8° difference between the left and right axial rotation, on axial CT with full neck rotation [37].
Three-dimensional CT demonstrating subluxation (Figure 3).
Increased ligament signal intensity on high-resolution proton density-weighted MRI, with the caveats that alar ligaments of asymptomatic patients may show high signal intensity and that there is variable inter-examiner reliability of MRI evaluation [33].
Compromise of the vertebral arteries based upon abnormal mechanics at the C1-C2 junction.
Anomalous joints.
Retro-odontoid pannus [23,27,34].

**Table 1:** Radiological findings of AAI.



**Figure 5:** (a) Sagittal model of atlanto-axial rotary sub-luxation; (b) Treatment of AAI.

Occiput to C1/C2 fusion should be considered in the presence of craniocervical instability, basilar invagination or complex Chiari malformation.

## Conclusion

AAI results from trauma, congenital conditions, neoplasm, infection, degenerative connective tissue disorders, genetic conditions such as the HOX-D3 or Down syndrome, and heritable connective tissue disorders, emblematic of which are the Ehlers Danlos syndromes. AAI in the hypermobility disorders usually requires dynamic imaging to demonstrate ligamentous incompetence. Radiological findings which are concordant with clinical findings should prompt consideration of surgery.

## References

- Fehlings M, Cooper P, Errico T (1992) Rheumatoid arthritis of the cervical spine. In: *Neurosurgical topics: Degenerative disease of the cervical spine*. Rolling Meadows, IL, American Association of Neurological Surgeons 125-139.
- Weissman BN, Aliabadi P, Weinfeld MS, Thomas WH, Sosman JL (1982) Prognostic features of atlantoaxial subluxation in rheumatoid arthritis patients. *Radiology* 144: 745-751.
- Mikulowski P, Wollheim FA, Rotmil P, Olsen I (1975) Sudden death in rheumatoid arthritis with atlanto-axial dislocation. *Acta Med Scand* 198: 445-451.
- Henderson FC, Austin C, Benzel E, Bolognese P, Ellenbogen R, et al. (2017)

Neurological and spinal manifestations of the Ehlers–Danlos syndromes. *Am J Med Genet C Semin Med Genet* 175: 195-211.

- Gluf WM, Brockmeyer DL (2005) Atlantoaxial transarticular screw fixation: A review of surgical indications, fusion rate, complications, and lessons learned in 67 pediatric patients. *J Neurosurg Spine* 2: 164-169.
- Fielding JW, Cochran G, Lawsing JF, Hohl M (1974) Tears of the transverse ligament of the atlas. A clinical and biomechanical study. *J Bone Joint Surg Am* 56(8): 1683-1691.
- White AA, Panjabi MM (1990) *Clinical biomechanics of the spine* (2nd edn), JB Lippincott Company, Philadelphia.
- Kirby A, Davies R (2007) Developmental coordination disorder and joint hypermobility syndrome—overlapping disorders? Implications for research and clinical practice. *Child Care Health Dev* 33: 513-519.
- Jelsma LD, Geuze RH, Klerks MH, Niemeijer AS, Smits-Engelsman BC (2013) The relationship between joint mobility and motor performance in children with and without the diagnosis of developmental coordination disorder. *BMC Pediatrics* 13: 1.
- Nagashima C, Tsuji R, Kubota S, Tajima K (1981) Atlanto-axial, atlanto-occipital dislocations, developmental cervical canal stenosis in the ehlers-danlos syndrome (author's transl). *No Shinkei Geka* 9: 601-608.
- Halko GJ, Cobb R, Abeles M (1995) Patients with type IV ehlers-danlos syndrome may be predisposed to atlantoaxial subluxation. *J Rheumatol* 22: 2152-2155.
- El-Khoury M, Mourão MA, Tobo A, Battistella LR, Herrero CFP, et al. (2014) Prevalence of atlanto-occipital and atlantoaxial instability in adults with down syndrome. *World Neurosurgery* 82: 215-218.

13. Steinmetz MP, Mroz TE, Benzel EC (2010) Craniovertebral junction: Biomechanical considerations. *Neurosurgery* 66: 7-12.
14. Wolfla CE (2006) Anatomical, biomechanical, and practical considerations in posterior occipito-cervical instrumentation. *Spine J* 6: 225S-232S.
15. Tubbs RS, Hallock JD, Radcliff V, Naftel RP (2011) Ligaments of the craniocervical junction: A review. *Journal of Neurosurgery: Spine* 14: 697-709.
16. Dvorak J, Panjabi M, Gerber M, Wichmann W (1987) CT-functional diagnostics of the rotatory instability of upper cervical spine: An experimental study on cadavers. *Spine* 12: 197-205.
17. Martin M, Bruner H, Maiman D (2010) Anatomic and biomechanical considerations of the craniocervical junction. *Neurosurgery* 66: 2-6.
18. Zhang H, Bai J (2007) Development and validation of a finite element model of the occipito-atlantoaxial complex under physiologic loads. *Spine* 32: 968-974.
19. Panjabi M, Dvorak J, Crisco JJ, Oda T, Wang P, et al. (1991) Effects of alar ligament transection on upper cervical spine rotation. *J Orthop Res* 9: 584-593.
20. Selecki BR (1969) The effects of rotation of the atlas on the axis: Experimental work. *Med J Aust* 1: 1012-1015.
21. Menezes AH, Traynelis VC (2008) Anatomy and biomechanics of normal craniocervical junction (a) and biomechanics of stabilization (b). *Child's Nervous System* 24: 1091-1100.
22. Sacheti A, Szemere J, Bernstein B, Tafas T, Schechter N, et al. (1997) Chronic pain is a manifestation of the Ehlers-Danlos syndrome. *J Pain Symptom Manage* 14: 88-93.
23. Isono M, Ishii K, Kamida T, Fujiki M, Goda M, et al. (2001) Retro-odontoid soft tissue mass associated with atlantoaxial sub-luxation in an elderly patient: A case report. *Surg Neurol* 55: 223-227.
24. Dickman C, Sonntag V (1998) Posterior C1-C2 transarticular screw fixation for atlantoaxial arthrodesis. *Neurosurgery* 43: 275-280.
25. Goel A, Desai KI, Muzumdar DP (2002) Atlantoaxial fixation using plate and screw method: A report of 160 treated patients. *Neurosurgery* 51: 1351-1356.
26. Aryan HE, Newman CB, Nottmeier EW, Acosta FL Jr, Wang VY, et al. (2008) Stabilization of the atlantoaxial complex via C-1 lateral mass and C-2 pedicle screw fixation in a multicenter clinical experience in 102 patients: Modification of the Harms and Goel techniques. *J Neurosurg Spine* 8: 222-229.
27. Goel A, Phalke U, Cacciola F, Muzumdar D (2004) Atlantoaxial instability and retroodontoid mass—Two case reports. *Neurol Med Chir (Tokyo)* 44: 603-606.
28. Koby M (2014) The discordant report – pathological radiological findings: A peripartetic review of salient features of neuropathology in the setting of an erstwhile standard 'normal' radiological assessment. In: *Co-Morbidities that Complicate the Treatment and Outcomes of Chiari Malformation*. Lulu. 50.
29. Kothari P, Freeman B, Grevitt M, Kerlake R (2000) Injury to the spinal cord without radiological abnormality (SCIWORA) in adults. *J Bone Joint Surg Br* 82: 1034-1037.
30. Fielding JW, Hawkins RJ (1977) Atlanto-axial rotatory fixation. (fixed rotatory subluxation of the atlanto-axial joint). *J Bone Joint Surg Am* 59: 37-44.
31. Fielding JW, Stillwell WT, Chynn K, Spyropoulos E (1978) Use of computed tomography for the diagnosis of atlanto-axial rotatory fixation. A case report. *JBJS Case Connector* 8: 1102-1104.
32. Taniguchi D, Tokunaga D, Hase H (2008) Evaluation of lateral instability of the atlanto-axial joint in rheumatoid arthritis using dynamic open-mouth view radiographs. *Clin Rheumatol* 27: 851-857.
33. Willauschus WG, Kladny B, Beyer WF, Gluckert K, Arnold H, et al. (1995) Lesions of the alar ligaments. *In vivo* and *in vitro* studies with magnetic resonance imaging. *Spine* 20: 2493-2498.
34. Jun B (1999) Complete reduction of retro-odontoid soft tissue mass in OS odontoidum following the posterior C1-C2 transarticular screw fixation. *Spine* 24: 1961.
35. Menendez JA, Wright NM (2007) Techniques of posterior C1-C2 stabilization. *Neurosurgery* 60: S103-11.
36. Madawi A, Casey A, Solanki G, Tuite G, Veres R, et al. (1997) Radiological and anatomical evaluation of the atlanto-axial transarticular screw fixation technique. *J Neurosurg* 86: 961-968.
37. Dvorak J, Hayek J, Zehnder R (1987) CT-functional diagnostics of the rotatory instability of the upper cervical spine. Part-2. An evaluation on healthy adults and patients with suspected instability. *Spine* 12: 726-731.

**Citation:** Henderson Sr. FC, Henderson Jr. FC (2017) Diagnosis of Atlantoaxial Instability Requires Clinical Suspicion to Drive the Radiological Investigation. *J Spine* 6: 364. doi: [10.4172/2165-7939.1000364](https://doi.org/10.4172/2165-7939.1000364)

### OMICS International: Open Access Publication Benefits & Features

#### Unique features:

- Increased global visibility of articles through worldwide distribution and indexing
- Showcasing recent research output in a timely and updated manner
- Special issues on the current trends of scientific research

#### Special features:

- 700+ Open Access Journals
- 50,000+ editorial team
- Rapid review process
- Quality and quick editorial, review and publication processing
- Indexing at major indexing services
- Sharing Option: Social Networking Enabled
- Authors, Reviewers and Editors rewarded with online Scientific Credits
- Better discount for your subsequent articles

Submit your manuscript at: <http://www.omicsonline.org/submission/>