




Contents lists available at ScienceDirect

## The Journal of Foot &amp; Ankle Surgery

journal homepage: [www.jfas.org](http://www.jfas.org)

ACFAS Clinical Consensus Statement

## American College of Foot and Ankle Surgeons Clinical Consensus Statement: Diagnosis and Treatment of Adult Acquired Infracalcaneal Heel Pain

Harry P. Schneider, DPM<sup>1,2,3</sup>, John Baca, DPM<sup>4</sup>, Brian Carpenter, DPM<sup>5,6</sup>, Paul Dayton, DPM<sup>7,8</sup>, Adam E. Fleischer, DPM, MPH<sup>9,10</sup>, Brett D. Sachs, DPM<sup>11,12</sup>

<sup>1</sup>Chairperson, Heel Pain Clinical Consensus Statement, Chicago, IL<sup>2</sup>Assistant Professor of Surgery, Harvard Medical School, Cambridge, MA<sup>3</sup>Residency Program Director, Cambridge Health Alliance, Cambridge, MA<sup>4</sup>Private Practice, Dallas Podiatry Works, Dallas, TX<sup>5</sup>Professor, Department of Orthopedics, The University of North Texas Health Science Center, Fort Worth, TX<sup>6</sup>Private Practice, Paradise, TX<sup>7</sup>Assistant Professor, College of Podiatric Medicine and Surgery, Des Moines, IA<sup>8</sup>Residency Program Director, UnityPoint Health, Fort Dodge, IA<sup>9</sup>Associate Professor, Dr. William M. Scholl College of Podiatric Medicine at Rosalind Franklin University of Medicine and Science, North Chicago, IL<sup>10</sup>Director of Research, Weil Foot and Ankle Institute, Chicago, IL<sup>11</sup>Private Practice, Rocky Mountain Foot & Ankle Center, Wheat Ridge, CO<sup>12</sup>Faculty, Highlands-Presbyterian/St. Luke's Podiatric Medicine and Surgery Residency Program, Denver, CO

## ARTICLE INFO

Level of Clinical Evidence: 5

Keywords:

ACFAS  
consensus  
heel pain  
infracalcaneal  
plantar fasciitis

## ABSTRACT

Adult acquired inferior calcaneal heel pain is a common pathology seen in a foot and ankle practice. A literature review and expert panel discussion of the most common findings and treatment options are presented. Various diagnostic and treatment modalities are available to the practitioner. It is prudent to combine appropriate history and physical examination findings with patient-specific treatment modalities for optimum success. We present the most common diagnostic tools and treatment options, followed by a discussion of the appropriateness of each based on the published data and experience of the expert panel.

© 2017 by the American College of Foot and Ankle Surgeons. All rights reserved.

## Executive Summary

The following document represents the findings of the adult acquired infracalcaneal heel pain consensus panel sponsored by the American College of Foot and Ankle Surgeons. The 6-member panel used a modified Delphi method to reach a clinical consensus regarding the diagnostic and treatment methods based on the best available evidence in the literature, combined with clinical experience and best patient practice.

The panel determined that the following statements are appropriate:

**Financial Disclosure:** The development of this consensus statement was funded by The American College of Foot and Ankle Surgeons, Chicago, IL.

**Conflict of Interest:** Revance Therapeutics sponsored A. Fleischer's research on botulinum toxin injection for plantar fasciitis.

Address correspondence to: Harry P. Schneider, DPM, Clinical Consensus Statements, American College of Foot and Ankle Surgeons, 8725 West Higgins Road, Suite 555, Chicago, IL 60631-2724.

E-mail address: [h Schneider@cha.harvard.edu](mailto:h Schneider@cha.harvard.edu) (H. Schneider).

1. Plantar fasciitis is diagnosed, in most cases, by the history and physical examination findings alone.
2. Routine use of radiographs is not necessary for the diagnosis of nontraumatic plantar fasciitis.
3. The presence of a calcaneal spur will not generally alter the treatment course.
4. Advanced imaging, such as magnetic resonance imaging and ultrasonography, is not necessary for the diagnosis or guidance of treatment of nontraumatic plantar fasciitis.
5. In most cases, infracalcaneal heel pain is a soft tissue-based disorder and calcaneal spurring is most likely not a causative factor.
6. Appropriate treatment of plantar fasciitis requires sufficient understanding of the patient's chronicity of symptoms.
7. Biomechanical support is safe and effective in the treatment of plantar fasciitis.
8. Stretching is safe and effective in the treatment of plantar fasciitis.
9. Corticosteroid injections are safe and effective in the treatment of plantar fasciitis.

10. Extracorporeal shockwave therapy (ESWT) is safe and effective in the treatment of plantar fasciitis.
11. Plantar fasciotomy (opened and endoscopic) is a safe and effective option for chronic, refractory plantar fasciitis.
12. Gastrocnemius release is a safe and effective option for chronic, refractory plantar fasciitis when clinically significant equinus is present.

The panel determined that the following statements were uncertain—neither appropriate nor inappropriate.

1. Nonsteroidal antiinflammatory drugs (NSAIDs) are safe and effective in the treatment of the pain associated with acute plantar fasciitis.
2. Diagnostic ultrasonography is an important adjuvant tool in the diagnosis and treatment of nontraumatic plantar fasciitis.
3. Other injection techniques (e.g., amniotic tissue, platelet-rich plasma, botulinum toxin, needling, and prolotherapy) are safe and effective in the treatment of plantar fasciitis.
4. Other surgical techniques (e.g., ultrasonic debridement using a microtip device, cryosurgery, and bipolar radiofrequency ablation) are safe and effective options for chronic, refractory plantar fasciitis.

This document was created to serve as a clinical consensus statement (CCS) from the American College of Foot and Ankle Surgeons (ACFAS) and serves as an update to the ACFAS's 2010 Heel Pain Clinical Practice Guideline (1). It is important to appreciate that consensus statements do not represent “clinical practice guidelines,” “formal evidence reviews,” “recommendations,” or “evidence-based guidelines.” Rather, a CCS reflects information synthesized by an organized group of content experts from the best available evidence. It can also contain opinions, uncertainties, and minority viewpoints. In contrast to clinical practice guidelines, which are based primarily on high-level evidence, clinical consensus statements are more applicable to situations where evidence is limited or lacking, yet there are still opportunities to reduce uncertainty and improve quality of care. A CCS should open the door to discussion on a topic, in contrast to attempting to provide definitive answers. Adherence to consensus statements will not ensure successful treatment in every clinical situation, and the physician should make the ultimate decision using all available clinical information and circumstances with respect to the appropriate treatment of an individual patient. Given the inevitable changes in the state of scientific information and technology, periodic review and revision will be necessary.

### Anatomy of the Plantar Fascia

The plantar fascia is synonymous with the plantar aponeurosis of the foot and provides a mechanical linkage between the calcaneus and the toes. It is composed of densely compacted collagen fibers that are mainly oriented in a longitudinal direction, although some fibers run in a transverse and oblique direction (2). The plantar fascia arises mainly from the medial calcaneal tuberosity and attaches distally, through several slips, to the plantar forefoot and the medial and lateral intermuscular septa. Anatomically, it can be divided into the medial, lateral, and central components (3).

The medial band is anatomically thin and virtually nonexistent at its proximal level. Similarly, the lateral band varies in its structure from relatively thick to nonexistent in 12% of individuals (4,5). When present, the lateral band provides a partial origin for the abductor digiti minimi muscle. The lateral band then bifurcates into the medial and lateral crura at the cuboid level. The stronger lateral crux inserts into the base of the fifth metatarsal. The medial crux merges distally with the central

band of the plantar fascia before coursing deep and inserting into the plantar plate of either the third, fourth, or fifth metatarsophalangeal joint (3).

The central band is triangular in shape and originates from the plantar medial process of the calcaneal tuberosity. The central band serves as the partial origin of the flexor digitorum brevis as it conforms to the plantar surface of the calcaneus. Ranging from 12 to 29 mm wide at its origin, the central plantar fascial band separates at the midmetatarsal level into 5 longitudinal bands (6). Each band then divides distally to the metatarsal heads to form deep and superficial tracts. The central superficial tracts insert onto the skin and contribute to the formation of the mooring and natatory ligaments (5). The 5 deep tracts separate to form medial and lateral sagittal septa, which contribute to the medial and lateral digital flexor, flexor tendon sheath, interosseous fascia, fascia of the transverse head of the adductor hallucis, deep transverse metatarsal ligament, and base of the proximal phalanges by way of the plantar plate and collateral ligaments (3).

The plantar calcaneal spur is a bony outgrowth of the calcaneal tuberosity that occurs, with some regularity, even in the general population (7). The association of the plantar calcaneal spur and plantar fascia is highly variable. The plantar calcaneal spur can be joined with all, part, or none of the plantar fascia. Tanz (8) first showed that the plantar calcaneal spur many times arises from the intrinsic muscles rather than from the plantar fascia itself. This finding was later corroborated by Forman and Green (9) and others. The plantar calcaneal spur is covered with a fibrous connective tissue layer, which is highly innervated and vascularized (7,10,11).

### Histologic Properties of the Plantar Fascia

The plantar fascia is histologically different from both tendon and ligament and is typically described as a dense connective tissue (12). Similar to tendons and ligaments, the plantar fascia is composed primarily of elongated fibrocytes. These fibrocytes are responsible for the production of collagen and are arranged in longitudinal rows. They have short cell processes that surround the collagen fibers and form gap junctions with other fibrocytes from adjacent rows (3). Because of this gap junction network, Benjamin (13) proposed that fibrocytes form a 3-dimensional communicating network that might be capable of sensing and responding to load changes in the plantar fascia by modifying the shape of the cytoskeleton. Because the plantar fascia has more fibroblasts than do tendons, it is believed to have an even greater sensory capacity than tendon and might act as an active sensory structure by changing its composition to passively transmit force (3).

Rather than having an indirect periosteal attachment, the proximal attachment of the plantar fascia on the calcaneus is distinctly fibrocartilaginous (14). Histologically, fibrocartilaginous entheses have 4 zones of tissue: first is dense fibrous tissue of the collagenous midsubstance, which is replaced successively by uncalcified fibrocartilage, calcified fibrocartilage, and, finally, bone. The extent of calcification within the fibrocartilaginous region and the degree of osseous interdigitation is important in resisting shear forces and might reflect the tensile strength of the entheses. With calcified and uncalcified fibrocartilaginous zones, direct attachments can help to dissipate stress evenly and provide a gradual transition from hard to soft tissue (3). Similar to the plantar fascial insertion, fibrocartilage appears to be located specifically at sites subjected to bending, shear, or compressive forces, or a combination thereof. High concentrations of proteoglycans and glycosaminoglycans within fibrocartilage entheses suggest an important role in the redistribution of compressive or bending forces (3). Therefore, the material properties, or modulus of elasticity, of the plantar fascia and its insertion fall between those of tendon and ligament (3,15).

Immunohistochemical analysis has shown that almost all the tissue of the plantar fascia is formed of type I collagen (15). The plantar fascia is also well innervated, with both free and encapsulated nerve endings, such as Pacini and Ruffini corpuscles (13,15). These nerve endings are particularly abundant where the plantar fascia joins with the fasciae of the abductor hallucis and abductor digiti minimi muscles and where the flexor muscles insert. These abundant innervations suggest that the plantar fascia plays a role in proprioception, aiding in the stabilization and control of foot movements (13,15).

### Some Definitions: Fasciitis, Fasciosis, and Fasciopathy

Considerable variation is present in the published data surrounding the use of “fasciitis” versus “fasciosis” (similar to tendonitis versus tendinosis). Fasciitis is a term generally used to describe acute inflammation in and around the plantar fascia. In contrast, fasciosis is generally used to describe the noninflammatory degradation or degeneration of the plantar fascia, usually late in the disease process. Finally, fasciopathy has historically been used as a general term that includes both short-term inflammation (fasciitis) and long-term degeneration (fasciosis). In an attempt to simplify the terminology for the purposes of the present CCS, only the term “fasciitis” has been used in this document.

### Epidemiology of Plantar Fasciitis

Plantar fasciitis is one of the most common conditions encountered by foot and ankle surgeons and accounts for >1 million outpatient visits annually (16–21). It has been estimated that ~10% of the population in the United States will develop plantar fasciitis in their lifetime (22,23), and >2 million Americans experience symptoms of plantar fasciitis at any one time (19,24–26). Active individuals appear to develop plantar fasciitis at an even greater rate than the general population, with incidence rates ranging from 8% to 21% among athletes and runners (27–31). Each year, ~11% to 15% of professional healthcare visits to foot and ankle specialists are attributed to heel pain (17,32–36). Therefore, it is well recognized that the cost of diagnosing and treating plantar fasciitis creates a considerable economic burden on the U.S. healthcare system (37).

The incidence of plantar fasciitis typically peaks between 40 and 60 years of age in the general population but has been reported in patients aged 7 to 85 years (19,31,34,35). Although some data have suggested that advanced age is associated with the occurrence of plantar fasciitis, age probably has only a modest effect on its development. In a large retrospective cohort study, Matheson et al (38) examined overuse injuries in 1407 older and younger athletes and found that 71.4% of the patients presenting with plantar fasciitis were >50 years old. Similar studies using the general population also favored a slightly increased risk with advanced age (39).

Plantar fasciitis probably demonstrates a slight male predilection (30,31,40–42); however, the association between gender and plantar fasciitis has varied in the published data (24,34,43). Larger studies involving runners have typically found that males were slightly more likely to be affected than females (e.g., Taunton et al [30], 54% versus 46%; Taunton et al [31], 59% versus 41% [combined n = 2269]). In contrast, some smaller studies have reported a female predominance (e.g., Riddle et al [24], 66% versus 34%; Davis et al [43], 70% versus 30% [combined n = 182]). Because no clear explanation exists as to why gender would impart additional risk, it might be a matter of function rather than gender.

### Etiology of Plantar Fasciitis

Plantar fasciitis has traditionally been considered an overuse injury, with repetitive microtrauma and damage to the plantar fascia occur-

ring at a rate that exceeds the body's capacity to heal (12,20,36,44). Biomechanical abnormalities, increased body mass index (BMI), athletic and sedentary lifestyles, and a host of external (environmental) factors are believed to contribute.

Numerous studies have demonstrated a relationship between plantar fasciitis and an increased BMI or body weight (24,27,33,39,45,46). Although this correlation has been described in both athletic and nonathletic populations, a high BMI appears to confer the greatest risk in nonathletic individuals (46). In a recent meta-analysis by van Leeuwen et al (46), the BMI measurements from 21 studies of plantar fasciitis were included and summarized. They concluded that probably a modest increase exists in the risk of developing plantar fasciitis at a higher BMI (46). However, it is still not certain whether the BMI exhibits a threshold effect for plantar fasciitis or the risk continues to increase at higher BMI categories (i.e., a dose-response effect).

Both high levels of activity and high levels of inactivity appear to be associated with the development of plantar fasciitis. The association of plantar heel pain with athletes and, in particular, runners has been discussed extensively in reported studies (18,25,28,30,31,39,47). Plantar fasciitis is also a common cause of heel pain in the active military (48). Riddle et al (24) found that undertaking no regular exercise conferred a 3 to 4 times greater risk of plantar fasciitis (odds ratio 3.6, 95% confidence interval 1.6 to 8.2). In contrast, Rano et al (39) found that physical activity 3 times a week for >20 minutes was associated with a decreased risk of plantar fasciitis (odds ratio 0.33, 95% confidence interval 0.14 to 0.74).

Multiple other “extrinsic” or environmental risk factors have been proposed as a cause of plantar fasciitis. These include wearing improper or excessively worn shoes, running on unyielding surfaces and other training errors, increases or changes in activity (3,27,32,33,36,45), increased standing times on hard surfaces, spending most of the workday on the feet (24,49), an increased percentage of time spent walking at work, and the number of truck entrances and exits (33,49).

### Biomechanics of Plantar Fasciitis

Plantar fasciitis is primarily believed to result from mechanical overload and excessive strain within the plantar aponeurosis. It is also widely believed that biomechanical abnormalities are responsible for the excessive tensile strain that can occur within the fascia during static stance and gait (3). During the stance phase of gait, tension within the fascia gradually increases and is believed to reach peak values at the start of push-off (80% of stance) (50–54). The plantar fascia is particularly susceptible to high tensile loads during stance because it works to resist arch elongation (55). Also, as the heel begins to rise and during early push-off, the fascia is again subjected to increased tension, at least partially by Hicks' windlass mechanism—with dorsiflexion of the toes, the plantar fascia becomes increasingly wound around the metatarsal heads, thus shortening its effective length and increasing the tension in the fascia (56–58). Elevation of the heel in the late stance also produces loading of the Achilles tendon, which increases the bending moments at the midfoot and increases tension in the fascia as it works to resist collapse of the arch (55).

The biomechanical factors that can adversely affect the fascia work either by increasing its tension or by disrupting energy dissipation in the heel. An excessively pronated foot that places greater tensile loads on the fascia would be an example of the former and a high arched foot with decreased shock absorption an example of the latter.

Although biomechanical anomalies and mechanical overload remain the clinical doctrine that most providers adhere to, surprisingly little consistency was found in reported studies regarding which anomalies are most closely associated with plantar fasciitis. The clinical risk

factors that have the greatest support are an increased BMI and restricted ankle joint dorsiflexion range of motion, in particular, in the nonathletic population (46). An increased mechanical load due to a higher BMI seems a very plausible source of increased plantar fascial stress (46), and the association between the BMI and musculoskeletal symptoms in general is widely recognized (59). A tight or contracted Achilles tendon is also thought to produce greater tensile loads in the fascia through direct transmission of tension through the calcaneal trabecular system, as proposed by Arandes and Viladot (60) and/or by increasing its passive mechanical longitudinal tension as a method of counteracting the arch flattening effect of ankle dorsiflexion stiffness (61,62).

Perhaps the greatest reason investigators have failed to identify a common set of biomechanical risk factors across all studies is that 2 distinct patient populations appears to be affected by plantar fasciitis: (1) athletes/runners and (2) more sedentary individuals with a higher BMI. In athletic individuals, high arched feet and varus knee alignment (variables that limit shock absorption) appear to be more closely linked to the development of plantar fasciitis symptoms (63). In contrast, in sedentary populations, a higher BMI, pronated feet, and ankle equinus appear to result in a greater risk (24,33,46,64). Hamstring tightness (64,65) and both lower heel pad energy dissipation properties and lower maximum heel pad stiffness also appear to contribute to the development of plantar fasciitis (28,49,66,67).

Because most of our understanding of the biomechanical and clinical observations found in patients with plantar fasciitis have derived from case-control and cross-sectional studies, it is unclear whether these observations are causative or, rather, the result of plantar fasciitis. It is important that we strive to better understand the biomechanical factors contributing to plantar fasciitis, because this will help to improve our understanding of the etiology and help to move toward a consensus regarding the treatment options for plantar fasciitis.

## Materials and Methods

### Creation of the Panel

Members of the ACFAS have suggested that CCSs would be useful. Therefore, the ACFAS enacted an initiative to create such documents for foot and ankle surgeons. This initiative was originally conceived to report on a variety of topics and take the place of previous clinical practice guidelines. To move forward with this initiative, a formal consensus method process was undertaken. Experts in the field of foot and ankle surgery were sent an invitation by the ACFAS to participate on a panel to develop a CCS on the diagnosis and treatment of plantar heel pain. Care was taken to ensure that the panel members included an appropriate mix of practice experience, academic rank, and practice location and type. The 6-member panel completed disclosure forms and was tasked with providing opinions and suggestions on the diagnosis and treatment of proximal plantar fasciitis. The panel was led by 1 chairperson (H.P.S.) and assisted by ACFAS members and staff. Over several months, the panel members participated in e-mail dialogue, several conference calls, and a face-to-face meeting. The panel's stated goal was to examine the current data relating to the diagnosis and treatment of adult acquired, proximally based, plantar fasciitis. A literature search was undertaken to identify published studies. In addition, the panel reached a consensus on a series of questions relating to the diagnosis and treatment of plantar fasciitis.

### Formal Literature Review

Comprehensive reviews of the published data were then performed by the panel members and included searches of Medline, EMBASE, the Cochrane Database of Systematic Reviews, PubMed, Ovid, Google Scholar, Scopus, and manual searches of the references of the included articles. Although this was not a formal systematic review, each panel member conducted thorough literature searches using these databases in an attempt to answer specific questions on each topic. The data searches included at least all prospective clinical trials, retrospective clinical cohort analyses, and retrospective case series specifically involving the diagnosis and treatment of proximal plantar fasciitis and associated topics.

## Consensus

A modified Delphi method was used to attain consensus on several pertinent clinical questions by the members of the panel. A series of statement questions was developed by the panel chairperson (H.P.S.). These were sent to the rest of the panel to determine their relevancy, inclusion, and categorization. Once the questions were finalized, they were sent to all panel members to review and answer. The answers were based on the appropriateness of the statement question and were graded from 1 (extremely inappropriate) to 9 (extremely appropriate) using a Likert scale. Each panel member answered the questions anonymously, and the results were sent to the panel chair (H.P.S.) (Fig.). The answers were reviewed and, in the cases for which agreement was reached, the results were grouped from 1 to 3 (inappropriate), 4 to 6 (uncertain), or 7 to 9 (appropriate). For those questions for which agreement was not reached (i.e., more than one of the panelists' ratings were outside the 3-point region [1 to 3, 4 to 6, or 7 to 9] containing the median), the results were summarized, kept anonymous, and distributed back to the panel members, with the reasons for the varying judgments included. These items were left for review. At the face-to-face meeting, the questions were administered again in light of the explanations provided by the other panel members. The panel members were able to change the ratings based on group discussions. An attempt was made to reach consensus for all questions, although this was not a requirement. All panel members participated in creation of the CCS manuscript. The final draft was submitted to the ACFAS leadership for adoption.

## Discussion

### Diagnosis of Plantar Fasciitis

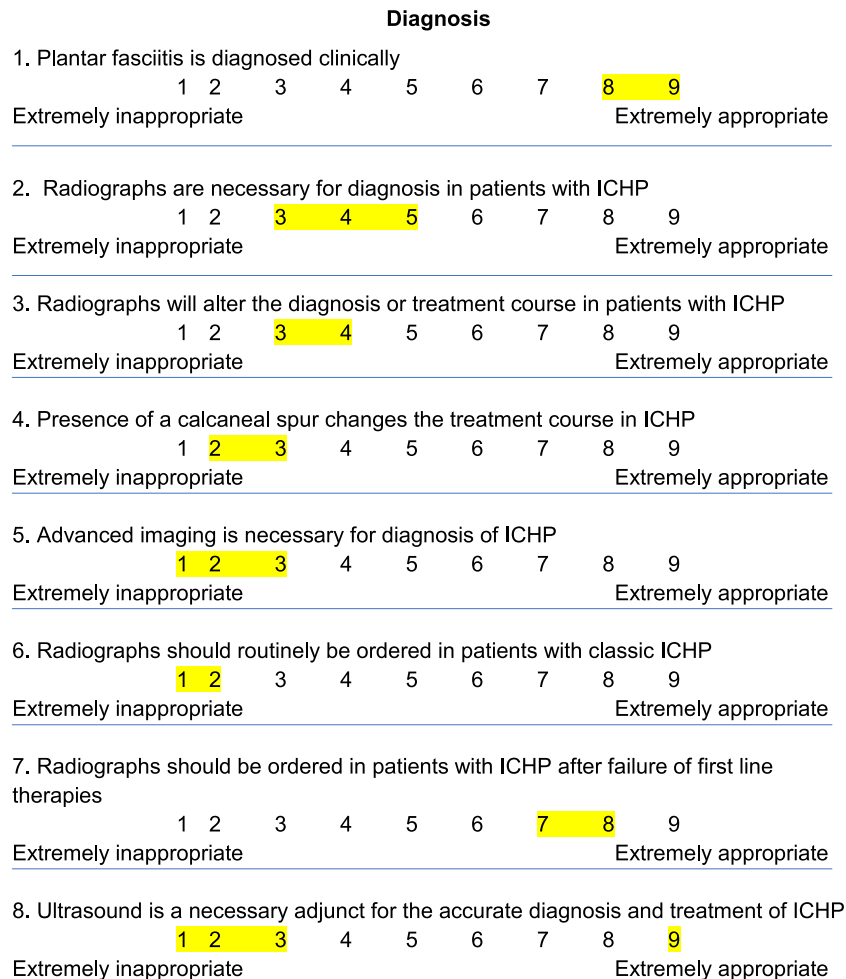
**Consensus Statement: The panel reached consensus that the statement "Plantar fasciitis is diagnosed, in most cases, by history and physical examination findings alone" was appropriate.**

One very typical complaint of patients with plantar fasciitis and inferior calcaneal bursitis is pain on the first few steps in the morning and after periods of inactivity. Generally, the pain from plantar fasciitis subsides to some degree with ambulation and mobilization. During standing and other activities of daily living, a progressive worsening of symptoms often occurs, with increased complaints of pain at the end of the day. Periodically, the pain will also be noted at rest owing to the tissue inflammation that results from repetitive tissue stress during daily activities. The severity of symptoms is often related to the hours of standing during daily activities and is many times altered by shoe gear. The most common location of pain for plantar fascia-originated symptoms is located at the plantar medial tubercle of the calcaneus at the plantar fascial insertion. Symptoms can extend along the course of the plantar fascia into the central arch; however, this has been a less prevalent finding. Also, lateral band and plantar lateral heel pain can be present but has been more variable. Generally, minimal clinical signs of inflammation such as swelling and erythema will be present. Pain with midfoot, hindfoot, and ankle range of motion is generally absent. Additionally, pain with medial lateral compression of the body of the calcaneus is not a component of plantar fascia-based symptoms and, if present, indicates the possibility of a stress fracture or other primarily bone pathology.

**Consensus Statement: The panel reached consensus that the statements "Routine use of radiographs is not necessary for the diagnosis of nontraumatic plantar fasciitis" and "The presence of a calcaneal spur does not generally alter the treatment course" were both appropriate.**

These 2 statements are particularly true in cases in which the history and physical examination findings are highly suggestive of plantar fasciitis. Radiographs can help rule out other causes of pain and should be ordered if a question of trauma, pain out of the ordinary, or recalcitrant pain that is not responding to appropriate conservative treatment is present. The role of imaging for the diagnosis of plantar heel pain has been variably recommended, and the value of plain film radiography has not been universally accepted. The question of whether imaging studies are necessary for the proper diagnosis and treatment lies in the significance of whether both soft tissue and bone





**Fig.** The questionnaire with the range of answers indicated by the consensus panel highlighted in yellow. ICHP, infracalcaneal heel pain.

changes are causative of the condition or simply associated findings. Levy et al (68) suggested that radiography was of limited value in the diagnosis and treatment of acute plantar fasciitis. In their review, they identified plantar calcaneal spurs in 59.5% of symptomatic patients and Achilles spurs in 46.5%. However, the identification of these findings led to changes in diagnosis and/or treatment in only 2% of the group (68). Reports of plantar spurs in asymptomatic heels include those by Rubin and Witten (69), Tanz (8), and Barrett et al (70), with rates of 27% of 461 16%, and 21%, respectively. Although plantar spurs can be identified in a variable percentage of patients with plantar heel pain, their significance is not clear. Rogers et al (71) studied the association of enthesophytes (bone formation at a ligament attachment) and osteophytes (bone formation at the edge of a joint) and found that these 2 conditions present together when present and also occur at multiple sites, indicating that patients with spurs might be “bone formers.” This idea of bone formers was corroborated by Menz et al (72), who noted that patients with plantar calcaneal spurs were more likely to have Achilles spurs. They also showed a positive association with spurs in patients with obesity, increased age, and osteoarthritis. Bassiouni (73) also showed a high incidence of calcaneal spurs in patients with both osteoarthritis and rheumatoid arthritis. The calcaneal enthesophyte incidence has also been reported by Mahto and Ohmar (74) (22% of 100 cadaveric specimens), Kullar et al (75) (26.5% of 200 specimens), Toumi et al (76) (38% combined plantar and posterior spurs), and Williams et al (77) (75% in painful heels and 63%

in contralateral nonpainful heels). That both plantar and Achilles spurs have been identified in some, but not all, patients and the association with bone formation at multiple sites would support the argument that the spur might not be causative but simply a finding suggestive of an arthritic condition or a trait leading to multiple-site bone formation.

Further confusing the issue regarding the significance of spurs and the diagnosis of heel pain is the referral bias present in most studies. Johal and Milner (16) highlighted this in a review of 19 patients with heel pain (89% incidence of plantar spur) and 19 age-matched controls (32% incidence of plantar spurs). Despite the identification of an increased incidence, causation could not be established. That referrals from primary care providers to a specialist are more likely when radiographs show a spur introduces bias into the assessment. Ahmad et al (78) reported on the size and shape of plantar calcaneal spurs in a group of patients referred for plantar heel pain. They found no correlation between the size or shape of the spur with symptoms (i.e., small spurs were likely to have worse symptoms than large spurs) (78). They concluded that the spur is not the source of inflammation and pain but an incidental finding. Moroney et al (79) evaluated the clinical symptoms and lateral radiographs of 1103 patients with and without calcaneal spurs. Their findings were similar to others reporting more overall foot pain in patients with spurs and an increase incidence of spurs with obesity, increased age, diabetes, and osteoarthritis. They concluded that the presence of calcaneal spurs might

## Open ended questions

1. What is the primary diagnostic modality for inferior calcaneal heel pain?
2. What are the primary treatment modalities for interior calcaneal heel pain?
3. What are the secondary treatment modalities if primary treatment modalities fail?
4. What are the tertiary conservative treatment modalities if secondary treatment modalities fail?
5. How many steroid injections will you give?
6. Do you need ultrasound guidance for steroid injections?
7. How important is biomechanical support (ie orthotics)?
8. How do you determine OTC vs. custom orthotics?
9. How important is BMI in development/treatment of BMI?
10. Do you apply strapping/taping?
11. What is your differential diagnosis if conservative treatment fails?
12. How do you differentiate between plantar fasciitis and inferior calcaneal bursitis?
13. How do you differentiate between plantar fasciitis and Baxter's neuritis?
14. How do you differentiate between plantar fasciitis and tarsal tunnel syndrome?
15. At what point is advanced imaging considered?
16. Is equinus important in treatment of plantar fasciitis?
17. At what point do you refer to physical therapy?
18. How long do you wait before considering surgical intervention for plantar fasciitis?
19. Do you ever operate on inferior calcaneal bursitis?
20. Does the literature support use of:
  - a. PRP?
  - b. Botox?
  - c. Needling?
  - d. Topaz® coblation?
  - e. Neurotherm® radiofrequency ablation?
  - f. EWST?
21. For surgical intervention, are there better outcomes for one type of procedure— in step, percutaneous, EPF, medial open.
22. Any other thoughts/questions for us to consider?

Fig. (continued)

be an indicator of foot pain, independent of plantar fasciitis, and that spurs themselves do not cause the pain but might be indicators of associated conditions (79).

When studying the radiographic data on plantar calcaneal spurs, another interesting finding emerged. It has been widely held that plantar calcaneal enthesophytes are caused by excessive traction on the plantar fascia from biomechanical causes. However, multiple studies have shown that the “spur” is not often located in the plantar fascia but is consistently present superior to the fascia in the intrinsic muscles

(10,70,80). This has led some to postulate that the cause of the spur is related to vertical compression rather than longitudinal traction (10,72).

**Consensus Statement: The panel reached consensus that the statement “Advanced imaging, such as magnetic resonance imaging and ultrasonography, is not necessary for diagnosis or guidance of treatment in nontraumatic plantar fasciitis” was appropriate.**

The panel believed that advanced imaging will have its greatest utility for those patients in whom conservative treatment has failed

and when historical or clinical symptoms are present that suggest another plausible etiology. When studying advanced imaging studies of patients with plantar heel pain, one consistent imaging finding in plantar heel pain is thickening of the plantar fascia and associated soft tissue structures. However, these structural changes are not always consistent with symptoms and are not generally required for the diagnosis or to indicate specific treatments. Ehrmann et al (81) studied magnetic resonance images from 77 asymptomatic volunteers. The mean plantar fascia thickness was 0.6 mm medially, 4.0 mm centrally, and 2.3 mm within the lateral fascicle. The T<sub>1</sub>-weighted sequence signal intensity was increased in the fascia of 16 of 77 volunteers (21%) and in only 7.8% using T<sub>2</sub>-weighted images. Only 6.5% (5 volunteers) had soft tissue edema notable deep to the fascia, and 21% had edema superficial to the fascia. Calcaneal spurs were detected in 19% (15 of 77) volunteers, and 5.2% demonstrated calcaneal bone marrow edema. Physicians should be mindful that patients can be asymptomatic even with images demonstrating signs of pathology. Signal changes at the plantar fascia and the presence of superficial fascial edema and calcaneal spurs might not be consistent with a plantar fasciitis diagnosis. Magnetic resonance imaging findings that were previously thought to represent plantar fasciitis can also be found in asymptomatic volunteers. Overuse of imaging could lead to overdiagnosis, with no benefit. Fleischer et al (82) used both quantitative and qualitative ultrasound findings of plantar fascia thickness and biconvexity of the proximal plantar fascia to predict patients' response to treatment. They determined that patients found to have biconvexity (qualitative appearance) tended to have lower responses to mechanical therapy over 3 months but that thickness (quantitative appearance) was not associated with treatment failure (82). Radwan et al (83) performed a systematic review of the effectiveness of ultrasonography for the diagnosis of plantar fasciitis and found it was an effective tool for assessing structural changes in the fascia. Although advanced imaging is clearly capable of assessing the structural morphology and integrity of the fascia, its necessity for determining the diagnosis and utility in predicting the treatment course remains unclear.

**Consensus Statement: The panel reached consensus that the statement “Diagnostic ultrasonography is an important adjuvant tool in the diagnosis and treatment of nontraumatic plantar fasciitis” was unclear—neither appropriate nor inappropriate.**

The answer for this statement varied widely according to experience and practice location and type. Those in favor used ultrasonography to help, not only to guide the injection, but also to measure the thickness of the plantar fascia for injection and at the follow-up appointments in the office. Other practitioners in the panel do not use ultrasonography at all. The panel agreed that the actual significance of the ultrasound findings is empirical and that the benefit of its use to guide treatment is not entirely clear when considering the available scientific data. However, for those with access, it does make sense that ultrasonography would allow more accurate targeting of injection therapy and the practitioner to measure the thickness of the fascia and to assess for qualitative changes during the treatment regimen.

**Consensus Statement: The panel reached consensus that the statement “In most cases, infracalcaneal heel pain is a soft tissue-based disorder and calcaneal spurring is most likely not a causative factor” was appropriate.**

Our conclusion was determined by the variable incidence and location of the spur and the data regarding soft tissue thickening and structural changes. This notion has been bolstered by the finding that patients with plantar calcaneal spurs tend to have osteophytes and enthesophytes at multiple anatomic locations, possibly because of phenotypic characteristics rather than from local mechanical or traumatic causes, which is often cited with heel spurs. The question that requires consideration, however, is the need to see these soft tissue and

bone changes to either make the diagnosis or choose the proper treatment for a patient with the typical clinical presentation of acute plantar heel pain. Parallel with the question of necessity is the cost of the imaging studies. If the identification of a spur does not help the clinician with the diagnosis or to refine the treatment recommendation, the cost of the imaging study is wasteful. However, if the clinical presentation is atypical, suggests the presence of a stress fracture (calcaneal body pain), or the initial appropriate therapy fails, imaging is a useful modality.

#### *Treatment of Plantar Fasciitis*

Nonsurgical treatment methods for plantar fasciitis will be successful in most individuals. Unlike the previous 2010 heel pain clinical practice guideline (1), the panel thought that less emphasis should be placed on a prescriptive protocol, or treatment ladder, that details when in the treatment course various modalities should be introduced. Instead, we believed it was more important for providers to attempt to tailor treatments to fit their patient's activity and lifestyle/employment requirements, with consideration of the patient's chronicity and severity of symptoms.

**Consensus Statement: The panel reached consensus that the statement “Appropriate treatment of plantar fasciitis requires sufficient understanding of the patient's chronicity of symptoms” was appropriate.**

It is important for providers to select treatments that will have the greatest effect within each stage of plantar fasciitis. Generally, the duration of symptoms helps to define the 3 phases of plantar fasciitis: acute, subacute, and chronic. Acute plantar fasciitis refers to the initial 4 to 6 weeks after onset. It can be either traumatic in etiology or due to mechanical overload. Subacute plantar fasciitis is usually present for approximately 6 to 12 weeks, and chronic plantar fasciitis is present for >3 months. A subdivision of chronic is refractory/recalcitrant. Refractory plantar fasciitis is best defined as chronic plantar fasciitis that has not improved with appropriate intervention for >6 months and is much more difficult to successfully treat.

#### *Nonsurgical Treatment*

**Consensus Statement: The panel reached consensus that the statement “Nonsteroidal antiinflammatory drugs (NSAIDs) are safe and effective in the treatment of the pain associated with plantar fasciitis” was unclear—neither appropriate nor inappropriate.**

Although it makes sense to treat the acute phase of plantar fasciitis with antiinflammatory agent, no published data support its use. Only Donley et al (84) reviewed the use of oral NSAIDs in a randomized, prospective, placebo-controlled study. Patients were given a treatment regimen that included either celecoxib or placebo. Both patient groups improved, with no statistically significant differences between the placebo and NSAID groups at 1, 2, or 6 months. Therefore, based on expert opinion and the sparse data, the panel does not recommend the routine use of NSAIDs in treating plantar fasciitis.

**Consensus Statement: The panel reached consensus that the statement “Biomechanical support is safe and effective in the treatment of plantar fasciitis” was appropriate.**

Because the primary cause of plantar fasciitis is mechanical overload and increased tension in the fascia, it is important to address any biomechanical factors that might be contributing. This includes taping or strapping, over-the-counter insoles, custom foot orthoses, and BMI counseling to prevent recurrence (39). Patients in all stages of plantar fasciitis are advised to avoid nonsupportive shoes, including flip-flops and ballet slippers. It is important to support the medial longitudinal arch to reduce stress on the plantar fascia. In 2014, Escalona-Marfil et al (85) evaluated whether a sandal that incorporates the arch profile of an in-shoe foot orthosis raises the medial

longitudinal arch. They concluded that medial longitudinal arch height is elevated by contoured sandals and approximates the subtalar joint neutral position of the foot, similar to that achieved by an orthosis (85).

Foot taping and strapping are particularly beneficial in the acute phase of plantar fasciitis to help support the medial longitudinal arch. Numerous studies (86–91) have evaluated the efficacy of taping and shown that in the short term, this remains a viable option to help reduce acute pain by supporting the plantar fascia.

A meta-analysis by Lee et al (92) showed that the use of foot orthoses in patients with plantar fasciitis appears to be associated with reduced pain and increased function. Chia et al (93) evaluated the foot pressure patterns for different types of orthotics and compared them with bone spur pads and flat insoles in patients with chronic plantar fasciitis. They concluded that prefabricated orthotics and custom orthotics reduced rearfoot peak forces and are useful in distributing pressure uniformly over the rear foot region (93). Additionally, Landorf et al (94), in a randomized trial, evaluated the short- and long-term effectiveness of foot orthosis in the treatment of plantar fasciitis. They followed up 135 participants for 12 months (94). They compared a sham orthotic, prefabricated orthotic, and a custom orthotic. At 3 months, pain relief and function favored the prefabricated custom orthotics. However, at the 12-month review, no significant changes were found in the primary outcome (94). A prospective randomized trial by Pfeffer et al (35), studied 236 patients from 15 centers with a symptom duration of  $\leq 6$  months. They combined stretching and shoe devices, including a silicone heel pad, a felt pad, a rubber heel cup, and custom orthotic device. All patients improved; however, they found that the patient improvement rates were greatest for the patients who performed stretching exercises and wore a prefabricated shoe insert (35). Stuber and Kristmason (95), in a narrative review of randomized controlled trials (RCTs), demonstrated several studies that showed custom-made orthotics were more beneficial than over-the-counter devices. In a double-blind, prospective, randomized clinical trial, Wrobel et al (96) compared custom foot orthoses, prefabricated foot orthoses, and a sham insole. Seventy-seven patients were included, and all the patients had had symptoms for  $< 1$  year. Patients in the custom foot orthosis group were 5 times more active, despite having performed 50% less Achilles tendon stretching, compared with the prefabricated insole and sham groups. All 3 groups in the study improved with respect to post-static dyskinesia on rising in the morning with the use of supportive shoe gear, stretching, and ice. Based on findings from all the studies, it is imperative to discuss appropriate biomechanical support with patients with plantar fasciitis. Medical treatment without patient involvement will lessen the success rates of nonsurgical treatment options. Appropriate and supportive shoe gear is important to support the medial longitudinal arch. Taping has been successful in published studies; however, most of the panel does not perform taping of patients on a regular basis. Taping can be used to support the arch and rest the plantar fascia in the short term. It can also be used as a test to determine whether the patient would do well with a more controlling insole or custom orthotic. The panel agreed that the decision to use a custom orthotic (versus an over-the-counter insole) depends primarily on the patient's magnitude of foot deformity, activity level, and whether the patient had a previous failed response with an over-the-counter insole.

**Consensus Statement: The panel reached consensus that the statement “Stretching is safe and effective in the treatment of plantar fasciitis” was appropriate.**

Tight hamstrings and equinus are common in patients with plantar fasciitis (64). Treatment of equinus is important for all stages of plantar fasciitis. A prospective, randomized study by DiGiovanni et al (97), investigated patient outcomes with chronic heel pain. The 101 patients with chronic plantar fasciitis were divided into a plantar fascia tissue

stretching program or an Achilles tendon stretching program. Of the 101 patients, 82 returned for a follow-up examination after 8 weeks. They found that patients performing plantar fascia-specific stretching exercises had superior results in reducing the pain with their first step in the morning and their highest level of pain. Kamonseki et al (98) compared the effects of stretching with and without muscle strengthening of the foot alone or foot and hip on pain and function in patients with plantar fasciitis. At 8 weeks, they found that all patients experienced improvement in function and stability (98). Equinus is quite common in patients with plantar fasciitis; therefore, a strict stretching exercise program will be beneficial.

In 2006, Roos et al (99) compared the effects of foot orthosis and night splints, alone or combined, in a prospective, randomized trial with 1-year follow-up data. Forty-three patients were randomized to receive foot orthoses, foot orthoses and night splints, or night splints alone. At 12 weeks, pain reduction of 30% to 50% was seen in all groups. At 52 weeks, the pain reduction was 62% in the 2 groups using foot orthoses compared with 40% in the night splint-only group. At 12 months, 19 of the 23 patients available for follow-up examinations were still using the foot orthosis compared with only 1 of 28 still using the night splint. Their study showed that stretching with a night splint is beneficial but that patient compliance is not as high as that for orthotics. Lee et al (100) evaluated the effectiveness of adjustable dorsiflexion night splints alone and combined with accommodative foot orthosis in the treatment of plantar fasciitis. Their study of 28 patients demonstrated that the addition of dorsiflexion night splints to the use of foot orthoses was more effective than the use of foot orthoses alone. Finally, Barry et al (101) in 2002 compared the effectiveness of standing gastrocnemius soleus stretching to the use of a prefabricated night splint sock. They concluded that the night splint treatment group had a significantly shorter recovery time, fewer follow-up visits before recovery, and fewer total additional interventions compared with the stretching group (101).

Physical therapy is also a beneficial adjunct for those who have difficulty stretching at home. In addition to stretching, physical therapy offers other modalities, including iontophoresis, soft tissue mobilization (102), and myofascial release (103,104).

The consensus of the panel is that stretching is extremely important in the treatment of plantar fasciitis. The type of stretching protocol (home stretching, night splint, or physical therapy) will vary according to the severity of the equinus and patient preference. No consensus was reached regarding the type of stretching needed. However, the panel agreed that more aggressive stretching would be preferred.

**Consensus Statement: The panel reached consensus that the statement “Corticosteroid injections are safe and effective in the treatment of plantar fasciitis” was appropriate.**

In a recent Cochrane review and meta-analysis of 3 RCTs, David et al (105) concluded that local steroid injections compared with placebo or no treatment might slightly reduce heel pain for  $\leq 1$  month but not subsequently. The panel was of the same opinion and admitted to using injectable steroids for the acute relief of symptoms, recognizing that these are not disease modifying and have little lasting effect beyond the first 4 weeks. These findings clearly underscore the importance of not offering corticosteroid injections as monotherapy for plantar fasciitis.

A systematic review by Uden et al (106) evaluated experimental studies in English from 1998 to 2010. Six RCTs met their selection criteria and were included. They concluded that both customized foot orthosis and corticosteroid injections can lead to a reduction in the pain associated with plantar fasciitis. They commented that steroid injections can have side effects (especially pain as a result of the injection), which could limit their acceptability (106). In a comparison between ultrasound and palpation guidance of local steroid injections, Tsai et al (107) concluded that ultrasound guidance is associated



with a lower recurrence of heel pain owing to the ability to appropriately inject in the area of maximal tenderness. Tatli and Kapasi (108) evaluated the “real risks” of steroid injections. They showed significant improvement in the short term. Combined with stretching, corticosteroid injections can provide efficacious pain relief. However, they recommended performing the injection with ultrasound monitoring to reduce the risk of potential complications (108). A RCT by McMillan et al (109) compared 82 patients with a clinical and ultrasound diagnosis of plantar fasciitis unrelated to systemic inflammatory disease. They found a single ultrasound-guided dexamethasone injection was safe and effective; however, significant pain relief did not continue beyond 4 weeks. In a recent meta-analysis comparing ultrasound- versus palpation-guided corticosteroid injections, Li et al (110) examined 5 RCTs with 149 patients and concluded that ultrasound-guided injection was superior with regard to the visual analog scale score for pain, response rate, and plantar fascia appearance on ultrasound scans. However, no statistically significant difference was found between the 2 groups for heel pain tenderness.

It appears that ultrasound guidance can be helpful for more anatomic precision. However, the panel was unable to reach a conclusion regarding whether it is required for corticosteroid injections.

Because very little guidance is available from the published data regarding the proper placement of injections, steroid strength, and/or injection frequency, the panel members were also asked to comment individually on their preferred technique. The members of the panel were comfortable giving 2 to 3 injections maximum within a 12-month period, citing the risk of rupture and/or fat pad atrophy as the primary concerns with continued use. The dose and type of corticosteroid injected varied widely among members. However, all agreed that caution should be exercised when injecting steroids to prevent fat pad and tissue atrophy with multiple injections or from using too high of a steroid dose. The members agreed that providers must also exercise good clinical judgment and not continue to offer corticosteroids to patients without improvement or a positive response. Finally, the panel members varied considerably regarding their preferred location of steroid placement for patients with plantar fasciitis (e.g., above, below, or within the fascia itself). However, for patients with classic proximally based plantar fasciitis, the panel agreed that attempts should be made to place the injection in close proximity to the insertion of the plantar fascia into the calcaneus.

**Consensus Statement: The panel reached consensus that the statement “Other injection techniques (e.g., amniotic tissue, platelet-rich plasma, botulinum toxin, needling, and prolotherapy) are safe and effective in the treatment of plantar fasciitis” was uncertain—neither appropriate nor inappropriate.**

Although other injection techniques are emerging for the treatment of plantar fasciitis, they have been supported only by low-quality studies consisting of case series, retrospective comparative studies, or small trials, lacking long-term follow-up data. Rather than speculate on the value of these injection therapies, the panel thought that further investigation is needed to assess how these will compare with the more conventional treatment protocols.

**Consensus Statement: The panel reached consensus that the statement “Extracorporeal shockwave therapy (ESWT) is safe and effective in the treatment of plantar fasciitis” was appropriate.**

Most ESWT protocols are designed to be administered in the office, once a week for 3 to 5 sessions total (high- or low-dose/energy delivered either by radial or focused shock waves). In these instances, anesthesia (e.g., nerve block) is not indicated and, when used, likely reduces the efficacy of the treatment (111,112). In contrast, high-energy, focused ESWT, which is extremely painful, can also be administered in 1 session under intravenous sedation in the operating room. The published data suggest that both are efficacious for subacute and chronic heel pain. At the time of the present CCS, we

found 6 systematic reviews (112–117), which identified 20 RCTs among them. The reviews included different RCTs in individual meta-analysis and presented data for different outcomes. All reviews suggested a net beneficial effect of ESWT compared with placebo, especially with respect to heel pain at 12 weeks, but also in activity, function, and quality of life (112–117). A general observation across all studies was that approximately 70% of patients with chronic or subacute plantar fasciitis who underwent ESWT had experienced meaningful improvement in their heel pain at 12 weeks. ESWT, however, does not appear to be an effective first-line option for patients with acute plantar fasciitis. Rompe et al (118) found that a program of manual stretching was superior to low-energy radial ESWT in their RCT of 102 patients with symptoms for <6 weeks. Because ESWT has few negative consequences and the recovery time is short, with patients typically walking and returning to full activities within a few days, the panel thought that ESWT is a valuable option for providers treating heel pain. However, because it is still not widely available in the United States owing to the cost of treatments and the lack of health insurance coverage, most members of the panel were not using ESWT routinely in their practice.

#### *Surgical Treatment*

Despite the tremendous progress in the conservative management of plantar fasciitis, a subset of patients continue to need surgical intervention to resume their normal daily lifestyle. Surgical intervention should be reserved for chronic, refractory cases that have failed appropriate conservative treatment for  $\geq 6$  months (35,48,119–121). Surgery for plantar fasciitis has 2 common and accepted types of procedures, and both work by releasing the tension from the plantar fascia. The panel reached a consensus that the reduction of plantar fascial tension is an integral part of surgical intervention for plantar fasciitis. The first treatment modality is plantar fasciotomy, which involves cutting a portion of the plantar fascia directly to decrease the tension on the fascial band. The second modality is gastrocnemius recession to decrease the tension indirectly.

**Consensus Statement: The panel reached consensus that the statement “Plantar fasciotomy (open and endoscopic) is a safe and effective option for chronic, refractory plantar fasciitis” was appropriate.**

Partial or complete release of the plantar fascia has been performed for many years, whether as an isolated procedure or combined with excision of the plantar calcaneal spur or gastrocnemius recession. In 1995, Tomczak and Haverstock (122) performed a retrospective comparison of endoscopic plantar fasciotomies (EPFs) to open plantar fasciotomy with heel spur resection. They reported that both groups were asymptomatic at 9 months but that the EPF group had returned to work and full activities 55 days earlier (122). The largest review of EPF was 652 cases treated by 25 surgeons reported by Barrett et al (70) in 1995. In their series, all surgeons released the medial one third of the band and demonstrated success and reproducibility. However, the patients were only followed up for 3 weeks postoperatively (70). O'Malley et al (123) in 2000 reviewed 20 feet treated by EPF and found that all patients with unilateral heel pain had complete relief and that the 1 patient with bilateral heel pain reported no improvement in pain. Morton et al (48) in 2013 performed a retrospective review of 105 consecutive EPF procedures on U.S. army soldiers and reviewed the outcomes stratified by the BMI. Of those patients with a BMI of  $\leq 25.53$  kg/m<sup>2</sup>, 96.35% had a postoperative pain level of 0, but only 44% of those with a BMI of  $\geq 29.8$  kg/m<sup>2</sup> had a postoperative pain score of 0. Hill et al (124) in 1989 performed a study on increased body weight and heel pain in consecutive plantar heel pain patients. They found a statistically significant correlation between heel pain and increased body weight. This positive correlation was also reported by Riddle et al (24) in 2003 and Rano et al (39) in 2001. Fishco

et al (125) reported the findings from a retrospective study of instep plantar fasciotomy on 83 patients. The main complication was scarring in 9.6% of the patients (125). Surgery was deemed successful 93.6% of the time, and 95.7% of the patients would recommend the procedure to someone with the same condition (125). Woelffer et al (12) in 2000 reported the 5-year results for patients who had undergone instep plantar fasciotomy. The satisfaction rate was  $\geq 90\%$  in 30 of the 33 feet, although 3 patients did complain of pain at the surgical site at times. The consensus of the panel was that release of the plantar fascia by any method is a valid surgical procedure in the treatment of chronic plantar fasciitis.

**Consensus Statement: The panel reached consensus that the statement “Gastrocnemius release is a safe and effective option for chronic, refractory plantar fasciitis when clinically significant equinus is present” was appropriate.**

Achilles tendon tension and plantar fascia loading are closely related. Patients with posterior group tightness and gastrocnemius contracture are known to exhibit decreased ankle joint range of motion and are at increased risk of developing plantar fasciitis (46). Cychoz et al (126) in 2015 performed a systematic review on the effectiveness of gastrocnemius recession in overuse pathologies in the foot and ankle. Although infracalcaneal heel pain was not studied specifically, they concluded that gastrocnemius release remains an underrepresented treatment for overload pathologies in the foot and ankle. They also found clear efficacy for gastrocnemius release and relief of midfoot and forefoot pain (126). In 2012, Schroeder (127) demonstrated that clinically significant improvement in ankle joint range of motion can be obtained with gastrocnemius recession. To date, 3 studies have examined gastrocnemius release in patients with plantar fasciitis, 2 using proximal release of the medial head in the popliteal fossa (128, 129) and 1 using a distal release at the myotendinous junction (130). Abbassian et al (128) studied proximal medial gastrocnemius release (PMGR) in 21 heels (17 patients) with  $\geq 1$  year of follow-up data. They found that 81% of the patients in the study reported total or significant pain relief at the final follow-up examination with fast recovery and low overall morbidity (128). Two patients related subjective weakness (12%) and 3 (17%) had some evidence of objective weakness at the final follow-up visit; however, this did not affect their outcome or satisfaction with the procedure (128). In the case series by Maskill et al (130), 25 limbs underwent gastrocnemius recession for painful plantar fasciitis. The mean visual analog scale pain scores had improved from 8.1 preoperatively to 1.9 at the final follow-up examination. Finally, in a retrospective comparative study, Monteagudo et al (129) compared the results of open plantar fasciotomy ( $n = 30$ ) with PMGR ( $n = 30$ ) in the treatment of chronic recalcitrant plantar fasciitis. They found that gastrocnemius release was superior to open fasciotomy for all outcomes (129). Patient satisfaction in the PMGR group reached 95% (compared with only 60% in the fasciotomy group). Additionally, patients in the PMGR group had returned to work and sports at 3 weeks postoperatively on average, and the functional and pain scores were considerably better in the PMGR group (129). Although no high level evidence is available yet to support of gastrocnemius release/recession, the panel still unanimously agreed that this represents a safe and effective treatment option (in isolation and in combination) for patients with gastrocnemius contracture and chronic refractory infracalcaneal heel pain.

**Consensus Statement: The panel reached consensus that the statement “Other surgical techniques (e.g., ultrasonic debridement with a microtip device, cryosurgery, and bipolar radiofrequency ablation) are safe and effective options for chronic, refractory plantar fasciitis” was uncertain—neither appropriate nor inappropriate.**

These treatment options have very little long-term data or peer-reviewed studies. Further research is needed to determine their

effectiveness. Cryosurgery is a minimally invasive percutaneous procedure for plantar fasciitis that has been described by both Allen et al (131) and Cavazos et al (121). Cryosurgery has very limited usage or clinical research to recommend its use. One retrospective study by Cavazos et al (121) demonstrated a 77.4% success rate in a sampling of 137 feet. Ultrasonic debridement with a microtip is new and does not yet have appropriate peer-reviewed studies for this panel to give a recommendation. This technology has been touted to remove only the degenerated tissue; however, outcome studies are needed. Bipolar radiofrequency ablation for recalcitrant plantar fasciitis has only been investigated and reported once by Sorensen et al (132) and provided only a 33.3% satisfactory pain relief at 4 weeks. The rate of good results did improve to 85.72% when rated subjectively.

In conclusion, in considering a treatment protocol for the diagnosis and treatment of plantar fasciitis, it is important to understand that each patient presentation will vary and no “cookie cutter” design will fit all patients. Appropriate diagnosis is mandatory to rule out other causes of heel pain. Treatment modalities will differ according to the chronicity and severity of the patient’s pain. Instead of giving a specific algorithm, the panel believed it would be more appropriate to review the published data and comment on the efficacy of the most common modalities used for diagnosis and treatment. Efforts should be made to tailor a treatment plan to each individual patient according to their specific expectations and physical requirements. In addition, it is important to remain cost conscious and responsible to the health-care system. Not all patients present equally; therefore, not every treatment regimen can be standardized. It is important to continue to monitor patients and their response to treatment for appropriate and timely improvement in their disease state.

## References

1. Thomas JL, Christensen JC, Kravitz SR, Mendicino RW, Schubert JM, Vanore JV, Weil LS Sr, Zlotoff HJ, Bouché R, Baker J; American College of Foot and Ankle Surgeons heel pain committee. The diagnosis and treatment of heel pain: a clinical practice guideline-revision 2010. *J Foot Ankle Surg* 49(3 suppl):S1–S19, 2010.
2. La Porta GA, La Fata PC. Pathologic conditions of the plantar fascia. *Clin Podiatr Med Surg* 22:1–9, 2005.
3. Wearing SC, Smeathers JE, Urry SR, Hennig EM, Hills AP. The pathomechanics of plantar fasciitis. *Sports Med* 36:585–611, 2006.
4. Dylevsky I. Connective tissues of the hand and foot. *Acta Univ Carol Med Monogr* 127:5–195, 1988.
5. Sarrafian SK. *Anatomy of the Foot and Ankle: Descriptive, Topographic, Functional*. JB Lippincott Company, New York, 1983.
6. Hawkins BJ, Langermen RJ Jr, Gibbons T, Calhoun JH. An anatomic analysis of endoscopic plantar fascia release. *Foot Ankle Int* 16:552–558, 1995.
7. Nakamura A, Osonoi T, Terauchi Y. Relationship between urinary sodium excretion and pioglitazone-induced edema. *J Diabetes Investig* 1:208–211, 2010.
8. Tanz SS. Heel pain. *Clin Orthop Relat Res* 28:169–178, 1963.
9. Forman WM, Green MA. The role of intrinsic musculature in the formation of inferior calcaneal exostoses. *Clin Podiatr Med Surg* 7:217–223, 1990.
10. Kumai T, Benjamin M. Heel spur formation and the subcalcaneal entheses of the plantar fascia. *J Rheumatol* 29:1957–1964, 2002.
11. Li J, Muehleman C. Anatomic relationship of heel spur to surrounding soft tissues: greater variability than previously reported. *Clin Anat* 20:950–955, 2007.
12. Woelffer KE, Figura MA, Sandberg NS, Snyder NS. Five-year follow-up results of instep plantar fasciotomy for chronic heel pain. *J Foot Ankle Surg* 39:218–223, 2000.
13. Benjamin M. The fascia of the limbs and back—a review. *J Anat* 214:1–18, 2009.
14. Snow SW, Bohne WH, DiCarlo E, Chang VK. Anatomy of the Achilles tendon and plantar fascia in relation to the calcaneus in various age groups. *Foot Ankle Int* 16:418–421, 1995.
15. Stecco C, Corradin M, Macchi V, Morra A, Porzionato A, Biz C, De Caro R. Plantar fascia anatomy and its relationship with Achilles tendon and paratenon. *J Anat* 223:665–676, 2013.
16. Johal KS, Milner SA. Plantar fasciitis and the calcaneal spur: fact or fiction? *Foot Ankle Surg* 18:39–41, 2012.
17. League AC. Current concepts review: plantar fasciitis. *Foot Ankle Int* 29:358–366, 2008.
18. Pohl MB, Hamill J, Davis IS. Biomechanical and anatomic factors associated with a history of plantar fasciitis in female runners. *Clin J Sport Med* 19:372–376, 2009.
19. Riddle DL, Schappert SM. Volume of ambulatory care visits and patterns of care for patients diagnosed with plantar fasciitis: a national study of medical doctors. *Foot Ankle Int* 25:303–310, 2004.

20. Sammarco GJ, Helfrey RB. Surgical treatment of recalcitrant plantar fasciitis. *Foot Ankle Int* 17:520–526, 1996.
21. Thomas MJ, Roddy E, Zhang W, Menz HB, Hannan MT, Peat GM. The population prevalence of foot and ankle pain in middle and old age: a systematic review. *Pain* 152:2870–2880, 2011.
22. Cole C, Seto C, Gazewood J. Plantar fasciitis: evidence-based review of diagnosis and therapy. *Am Fam Physician* 72:2237–2242, 2005.
23. Crawford F, Thomson C. Interventions for treating plantar heel pain. *Cochrane Database Syst Rev* (3):CD000416, 2003.
24. Riddle DL, Pulisic M, Pidcoke P, Johnson RE. Risk factors for plantar fasciitis: a matched case-control study. *J Bone Joint Surg Am* 85-A:872–877, 2003.
25. Saxena A, Fullem B. Plantar fascia ruptures in athletes. *Am J Sports Med* 32:662–665, 2004.
26. Toomey EP. Plantar heel pain. *Foot Ankle Clin* 14:229–245, 2009.
27. Rome K. Anthropometric and biomechanical risk factors in the development of plantar heel pain—a review of the literature. *Phys Ther Rev* 2:123–134, 1997.
28. Rome K, Howe T, Haslock I. Risk factors associated with the development of plantar heel pain in athletes. *Foot* 11:119–125, 2001.
29. Lysholm J, Wiklander J. Injuries in runners. *Am J Sports Med* 15:168–171, 1987.
30. Taunton JE, Ryan MB, Clement DB, McKenzie DC, Lloyd-Smith DR, Zumbo BD. A retrospective case-control analysis of 2002 running injuries. *Br J Sports Med* 36:95–101, 2002.
31. Taunton JE, Ryan MB, Clement DB, McKenzie DC, Lloyd-Smith D. Plantar fasciitis: a retrospective analysis of 267 cases. *Phys Ther Sport* 3:57–65, 2002.
32. Buchbinder R. Clinical practice: plantar fasciitis. *N Engl J Med* 350:2159–2166, 2004.
33. Irving DB, Cook JL, Young MA, Menz HB. Obesity and pronated foot type may increase the risk of chronic plantar heel pain: a matched case-control study. *BMC Musculoskelet Disord* 8:41, 2007.
34. Irving DB, Cook JL, Menz HB. Factors associated with chronic plantar heel pain: a systematic review. *J Sci Med Sport* 9:11–24, 2006.
35. Pfeiffer G, Bacchetti P, Deland J, Lewis A, Anderson R, Davis W, Alvarez R, Brodsky J, Cooper P, Frey C, Herrick R, Myerson M, Sammarco J, Jannecki C, Ross S, Bowman M, Smith R. Comparison of custom and prefabricated orthoses in the initial treatment of proximal plantar fasciitis. *Foot Ankle Int* 20:214–221, 1999.
36. Rompe JD, Furia J, Weil L, Maffulli N. Shock wave therapy for chronic plantar fasciopathy. *Br Med Bull* 81–82:183–208, 2007.
37. Tong KB, Furia J. Economic burden of plantar fasciitis treatment in the United States. *Am J Orthop (Belle Mead NJ)* 39:227–231, 2010.
38. Matheson GO, Macintyre JG, Taunton JE, Clement DB, Lloyd-Smith R. Musculoskeletal injuries associated with physical activity in older adults. *Med Sci Sports Exerc* 21:379–385, 1989.
39. Rano JA, Fallat LM, Savoy-Moore RT. Correlation of heel pain with body mass index and other characteristics of heel pain. *J Foot Ankle Surg* 40:351–356, 2001.
40. Clement DB, Taunton JE, Smart GW, McNicol KL. A survey of overuse running injuries. *Phys Sportsmed* 9:47–58, 1981.
41. Gross ML, Davlin LB, Evanski PM. Effectiveness of orthotic shoe inserts in the long-distance runner. *Am J Sports Med* 19:409–412, 1991.
42. Macintyre JG, Taunton JE, Clement DB, Lloyd-Smith D, McKenzie DC, Morrell RW. Running injuries: a clinical study of 4,173 cases. *Clin J Sport Med* 1:81–87, 1991.
43. Davis PF, Severud E, Baxter DE. Painful heel syndrome: results of nonoperative treatment. *Foot Ankle Int* 15:531–535, 1994.
44. Lemont H, Ammirati KM, Usen N. Plantar fasciitis: a degenerative process (fasciosis) without inflammation. *J Am Podiatr Med Assoc* 93:234–237, 2003.
45. McPoi TG, Martin RL, Cornwall MW, Wukich DK, Irrgang JJ, Godges JJ. Heel pain—plantar fasciitis: clinical practice guidelines linked to the international classification of function, disability, and health from the orthopaedic section of the American Physical Therapy Association. *J Orthop Sports Phys Ther* 38:A1–A18, 2008.
46. van Leeuwen KD, Rogers J, Winzenberg T, van Middelkoop M. Higher body mass index is associated with plantar fasciopathy/“plantar fasciitis”: systematic review and meta-analysis of various clinical and imaging risk factors. *Br J Sports Med* 50:972–981, 2016.
47. Messier SP, Pittala KA. Etiologic factors associated with selected running injuries. *Med Sci Sports Exerc* 20:501–505, 1988.
48. Morton TN, Zimmerman JP, Lee M, Schaber JD. A review of 105 consecutive uniport endoscopic plantar fascial release procedures for the treatment of chronic plantar fasciitis. *J Foot Ankle Surg* 52:48–52, 2013.
49. Werner RA, Gell N, Hartigan A, Wiggerman N, Keyserling WM. Risk factors for plantar fasciitis among assembly plant workers. *PM R* 2:110–116, 2010.
50. Erdemir A, Hamel AJ, Fauth AR, Piazza SJ, Sharkey NA. Dynamic loading of the plantar aponeurosis in walking. *J Bone Joint Surg Am* 86-A:546–552, 2004.
51. Wearing SC, Smeathers JE, Yates B, Sullivan PM, Urry SR, Dubois P. Sagittal movement of the medial longitudinal arch is unchanged in plantar fasciitis. *Med Sci Sports Exerc* 36:1761–1767, 2004.
52. Hunt AE, Smith RM, Torode M. Extrinsic muscle activity, foot motion and ankle joint moments during the stance phase of walking. *Foot Ankle Int* 22:31–41, 2001.
53. Hunt AE, Smith RM, Torode M, Keenan AM. Inter-segment foot motion and ground reaction forces over the stance phase of walking. *Clin Biomech (Bristol, Avon)* 16:592–600, 2001.
54. Cashmere T, Smith R, Hunt A. Medial longitudinal arch of the foot: stationary versus walking measures. *Foot Ankle Int* 20:112–118, 1999.
55. Sarrafian SK. Functional characteristics of the foot and plantar aponeurosis under tibiotalar loading. *Foot Ankle* 8:4–18, 1987.
56. Salathe EP Jr, Arangio GA, Salathe EP. A biomechanical model of the foot. *J Biomech* 19:989–1001, 1986.
57. Williams A, VEDI V, Singh D, Gedroye W, Hunt D. Hick’s revisited: a weightbearing in vivo study of the biomechanics of the plantar fascia employing “dynamic” MRI. *J Bone Joint Surg Br* 81:381, 1999.
58. Hicks JH. The mechanics of the foot. II. The plantar aponeurosis and the arch. *J Anat* 88:25–30, 1954.
59. Butterworth PA, Landorf KB, Smith SE, Menz HB. The association between body mass index and musculoskeletal foot disorders: a systematic review. *Obes Rev* 13:630–642, 2012.
60. Arandes R, Viladot A. Biomechanica del calcaneo. *Med Clin (Barc)* 21:25–34, 1953.
61. Pascual Huerta J. The effect of the gastrocnemius on the plantar fascia. *Foot Ankle Clin* 19:701–718, 2014.
62. Amis J. The split second effect: the mechanism of how equinus can damage the human foot and ankle. *Front Surg* 3:38, 2016.
63. Di Caprio F, Buda R, Mosca M, Calabro A, Giannini S. Foot and lower limb diseases in runners: assessment of risk factors. *J Sports Sci Med* 9:587–596, 2010.
64. Bolivar YA, Munuera PV, Padillo JP. Relationship between tightness of the posterior muscles of the lower limb and plantar fasciitis. *Foot Ankle Int* 34:42–48, 2013.
65. Harty J, Soffe K, O’Toole G, Stephens MM. The role of hamstring tightness in plantar fasciitis. *Foot Ankle Int* 26:1089–1092, 2005.
66. Wearing SC, Smeathers JE, Sullivan PM, Yates B, Urry SR, Dubois P. Plantar fasciitis: are pain and fascial thickness associated with arch shape and loading? *Phys Ther* 87:1002–1008, 2007.
67. Wearing SC, Smeathers JE, Urry SR, Sullivan PM, Yates B, Dubois P. Plantar enthesopathy: thickening of the enthesis is correlated with energy dissipation of the plantar fat pad during walking. *Am J Sports Med* 38:2522–2527, 2010.
68. Levy JC, Mizel MS, Clifford PD, Temple HT. Value of radiographs in the initial evaluation of nontraumatic adult heel pain. *Foot Ankle Int* 27:427–430, 2006.
69. Rubin G, Witten M. Plantar calcaneal spurs. *Am J Orthop* 5:38–41, 1963.
70. Barrett SL, Day SV, Pignetti TT, Robinson LB. Endoscopic plantar fasciotomy: a multi-surgeon prospective analysis of 652 cases. *J Foot Ankle Surg* 34:400–406, 1995.
71. Rogers J, Shepstone L, Dieppe P. Bone formers: osteophyte and enthesophyte formation are positively associated. *Ann Rheum Dis* 56:85–90, 1997.
72. Menz HB, Zammit GV, Landorf KB, Munteanu SE. Plantar calcaneal spurs in older people: longitudinal traction or vertical compression? *J Foot Ankle Res* 1:7, 2008.
73. Bassiouni M. Incidence of calcaneal spurs in osteo-arthritis and rheumatoid arthritis, and in control patients. *Ann Rheum Dis* 24:490–493, 1965.
74. Mahto A, Omar S. Enthesophytes and tubercles of the calcaneum: an anatomical and clinical understanding of the relationship between calcaneal spurs and plantar heel pain. *IJSS* 3:99–103, 2015.
75. Kullar JS, Randhawa GK, Kullar KK. A study of calcaneal enthesophytes (spurs) in Indian population. *Int J Appl Basic Med Res* 4(suppl 1):S13–S16, 2014.
76. Toumi H, Davies R, Mazor M, Coursier R, Best TM, Jennane R, Lespessailles E. Changes in prevalence of calcaneal spurs in men & women: a random population from a trauma clinic. *BMC Musculoskelet Disord* 15:87–2474-15-87, 2014.
77. Williams PL, Smibert JG, Cox R, Mitchell R, Klenerman L. Imaging study of the painful heel syndrome. *Foot Ankle* 7:345–349, 1987.
78. Ahmad J, Karim A, Daniel JN. Relationship and classification of plantar heel spurs in patients with plantar fasciitis. *Foot Ankle Int* 37:994–1000, 2016.
79. Moroney PJ, O’Neill BJ, Khan-Bhambro K, O’Flanagan SJ, Keogh P, Kenny PJ. The conundrum of calcaneal spurs: do they matter? *Foot Ankle Spec* 7:95–101, 2014.
80. Abreu MR, Chung CB, Mendes L, Mohana-Borges A, Trudell D, Resnick D. Plantar calcaneal enthesophytes: new observations regarding sites of origin based on radiographic, MR imaging, anatomic, and paleopathologic analysis. *Skeletal Radiol* 32:13–21, 2003.
81. Ehrmann C, Maier M, Mengiardi B, Pfirrmann CW, Sutter R. Calcaneal attachment of the plantar fascia: MR findings in asymptomatic volunteers. *Radiology* 272:807–814, 2014.
82. Fleischer AE, Albright RH, Crews RT, Kelil T, Wrobel JS. Prognostic value of diagnostic sonography in patients with plantar fasciitis. *J Ultrasound Med* 34:1729–1735, 2015.
83. Radwan A, Wyland M, Applequist L, Bolowsky E, Klingensmith H, Virag I. Ultrasonography, an effective tool in diagnosing plantar fasciitis: a systematic review of diagnostic trials. *Int J Sports Phys Ther* 11:663–671, 2016.
84. Donley BG, Moore T, Sferra J, Gozdanovic J, Smith R. The efficacy of oral nonsteroidal anti-inflammatory medication (NSAID) in the treatment of plantar fasciitis: a randomized, prospective, placebo-controlled study. *Foot Ankle Int* 28:20–23, 2007.
85. Escalona-Marfil C, McPoi TG, Mellor R, Vicenzino B. A radiographic and anthropometric study of the effect of a contoured sandal and foot orthosis on supporting the medial longitudinal arch. *J Foot Ankle Res* 7:38, 2014.
86. Podolsky R, Kalichman L. Taping for plantar fasciitis. *J Back Musculoskelet Rehabil* 28:1–6, 2015.
87. Park C, Lee S, Lim DY, Yi CW, Kim JH, Jeon C. Effects of the application of low-dye taping on the pain and stability of patients with plantar fasciitis. *J Phys Ther Sci* 27:2491–2493, 2015.
88. Hyland MR, Webber-Gaffney A, Cohen L, Lichtman PT. Randomized controlled trial of calcaneal taping, sham taping, and plantar fascia stretching for the short-term management of plantar heel pain. *J Orthop Sports Phys Ther* 36:364–371, 2006.



89. Abd El Salam MS, Abd Elhafz YN. Low-dye taping versus medial arch support in managing pain and pain-related disability in patients with plantar fasciitis. *Foot Ankle Spec* 4:86–91, 2011.
90. van de Water AT, Speksnijder CM. Efficacy of taping for the treatment of plantar fasciosis: a systematic review of controlled trials. *J Am Podiatr Med Assoc* 100:41–51, 2010.
91. Radford JA, Landorf KB, Buchbinder R, Cook C. Effectiveness of low-dye taping for the short-term treatment of plantar heel pain: a randomised trial. *BMC Musculoskelet Disord* 7:64, 2006.
92. Lee SY, McKeon P, Hertel J. Does the use of orthoses improve self-reported pain and function measures in patients with plantar fasciitis? A meta-analysis. *Phys Ther Sport* 10:12–18, 2009.
93. Chia KK, Suresh S, Kuah A, Ong JL, Phua JM, Seah AL. Comparative trial of the foot pressure patterns between corrective orthotics, formthotics, bone spur pads and flat insoles in patients with chronic plantar fasciitis. *Ann Acad Med Singapore* 38:869–875, 2009.
94. Landorf KB, Keenan AM, Herbert RD. Effectiveness of foot orthoses to treat plantar fasciitis: a randomized trial. *Arch Intern Med* 166:1305–1310, 2006.
95. Stuber K, Kristmanson K. Conservative therapy for plantar fasciitis: a narrative review of randomized controlled trials. *J Can Chiropr Assoc* 50:118–133, 2006.
96. Wrobel JS, Fleischer AE, Crews RT, Jarrett B, Najafi B. A randomized controlled trial of custom foot orthoses for the treatment of plantar heel pain. *J Am Podiatr Med Assoc* 105:281–294, 2015.
97. DiGiovanni BF, Nawoczenski DA, Lintal ME, Moore EA, Murray JC, Wilding GE, Baumhauer JF. Tissue-specific plantar fascia-stretching exercise enhances outcomes in patients with chronic heel pain: a prospective, randomized study. *J Bone Joint Surg Am* 85-A:1270–1277, 2003.
98. Kamonseki DH, Goncalves GA, Yi LC, Junior IL. Effect of stretching with and without muscle strengthening exercises for the foot and hip in patients with plantar fasciitis: a randomized controlled single-blind clinical trial. *Man Ther* 23:76–82, 2016.
99. Roos E, Engstrom M, Soderberg B. Foot orthoses for the treatment of plantar fasciitis. *Foot Ankle Int* 27:606–611, 2006.
100. Lee WC, Wong WY, Kung E, Leung AK. Effectiveness of adjustable dorsiflexion night splint in combination with accommodative foot orthosis on plantar fasciitis. *J Rehabil Res Dev* 49:1557–1564, 2012.
101. Barry LD, Barry AN, Chen Y. A retrospective study of standing gastrocnemius-soleus stretching versus night splinting in the treatment of plantar fasciitis. *J Foot Ankle Surg* 41:221–227, 2002.
102. Looney B, Srokose T, Fernandez-de-las-Penas C, Cleland JA. Graston instrument soft tissue mobilization and home stretching for the management of plantar heel pain: a case series. *J Manipulative Physiol Ther* 34:138–142, 2011.
103. Hansberger BL, Baker RT, May J, Nasypany A. A novel approach to treating plantar fasciitis—effects of primal reflex release technique: a case series. *Int J Sports Phys Ther* 10:690–699, 2015.
104. Ajimsha MS, Binsu D, Chithra S. Effectiveness of myofascial release in the management of plantar heel pain: a randomized controlled trial. *Foot (Edinb)* 24:66–71, 2014.
105. David JA, Sankarapandian V, Christopher PR, Chatterjee A, Macaden AS. Injected corticosteroids for treating plantar heel pain in adults. *Cochrane Database Syst Rev* (6):CD009348, 2017.
106. Uden H, Boesch E, Kumar S. Plantar fasciitis—to jab or to support? A systematic review of the current best evidence. *J Multidiscip Healthc* 4:155–164, 2011.
107. Tsai WC, Hsu CC, Chen CP, Chen MJ, Yu TY, Chen YJ. Plantar fasciitis treated with local steroid injection: comparison between sonographic and palpation guidance. *J Clin Ultrasound* 34:12–16, 2006.
108. Tatli YZ, Kapasi S. The real risks of steroid injection for plantar fasciitis, with a review of conservative therapies. *Curr Rev Musculoskelet Med* 2:3–9, 2009.
109. McMillan AM, Landorf KB, Gilheany MF, Bird AR, Morrow AD, Menz HB. Ultrasound guided corticosteroid injection for plantar fasciitis: randomised controlled trial. *BMJ* 344:e3260, 2012.
110. Li Z, Xia C, Yu A, Qi B. Ultrasound- versus palpation-guided injection of corticosteroid for plantar fasciitis: A meta-analysis. *PLoS One* 9:e92671, 2014.
111. Klonschinski T, Ament SJ, Schlereth T, Rompe JD, Birklein F. Application of local anesthesia inhibits effects of low-energy extracorporeal shock wave treatment (ESWT) on nociceptors. *Pain Med* 12:1532–1537, 2011.
112. Lou J, Wang S, Liu S, Xing G. Effectiveness of extracorporeal shock wave therapy without local anesthesia in patients with recalcitrant plantar fasciitis: a meta-analysis of randomized controlled trials. *Am J Phys Med Rehabil* 96:529–534, 2017.
113. Thomson CE, Crawford F, Murray GD. The effectiveness of extra corporeal shock wave therapy for plantar heel pain: a systematic review and meta-analysis. *BMC Musculoskelet Disord* 6:19, 2005.
114. Aqil A, Siddiqui MR, Solan M, Redfern DJ, Gulati V, Cobb JP. Extracorporeal shock wave therapy is effective in treating chronic plantar fasciitis: a meta-analysis of RCTs. *Clin Orthop Relat Res* 471:3645–3652, 2013.
115. Dixon JN, Gonzalez-Suarez C, Zamora MT, Gambito ED. Effectiveness of extracorporeal shock wave therapy in chronic plantar fasciitis: a meta-analysis. *Am J Phys Med Rehabil* 92:606–620, 2013.
116. Landorf KB. Plantar heel pain and plantar fasciitis. *BMJ Clin Evid* 2015:1111, 2015.
117. Sun J, Gao F, Wang Y, Sun W, Jiang B, Li Z. Extracorporeal shock wave therapy is effective in treating chronic plantar fasciitis: a meta-analysis of RCTs. *Medicine (Baltimore)* 96:e6621, 2017.
118. Rompe JD, Cacchio A, Weil L Jr, Furia JP, Haist J, Reiners V, Schmitz C, Maffulli N. Plantar fascia-specific stretching versus radial shock-wave therapy as initial treatment of plantar fasciopathy. *J Bone Joint Surg Am* 92:2514–2522, 2010.
119. Davies MS, Weiss GA, Saxby TS. Plantar fasciitis: how successful is surgical intervention? *Foot Ankle Int* 20:803–807, 1999.
120. Wolgin M, Cook C, Graham C, Mauldin D. Conservative treatment of plantar heel pain: long-term follow-up. *Foot Ankle Int* 15:97–102, 1994.
121. Cavazos GJ, Khan KH, D'Antoni AV, Harkless LB, Lopez D. Cryosurgery for the treatment of heel pain. *Foot Ankle Int* 30:500–505, 2009.
122. Tomczak RL, Haverstock BD. A retrospective comparison of endoscopic plantar fasciotomy to open plantar fasciotomy with heel spur resection for chronic plantar fasciitis/heel spur syndrome. *J Foot Ankle Surg* 34:305–311, 1995.
123. O'Malley MJ, Page A, Cook R. Endoscopic plantar fasciotomy for chronic heel pain. *Foot Ankle Int* 21:505–510, 2000.
124. Hill JJ Jr, Cutting PJ. Heel pain and body weight. *Foot Ankle* 9:254–256, 1989.
125. Fishco WD, Goecker RM, Schwartz RI. The instep plantar fasciotomy for chronic plantar fasciitis. A retrospective review. *J Am Podiatr Med Assoc* 90:66–69, 2000.
126. Cychosz CC, Phisitkul P, Belatti DA, Glazebrook MA, DiGiovanni CW. Gastrocnemius recession for foot and ankle conditions in adults: evidence-based recommendations. *Foot Ankle Surg* 21:77–85, 2015.
127. Schroeder SM. Uniportal endoscopic gastrocnemius recession for treatment of gastrocnemius equinus with a dedicated EGR system with retractable blade. *J Foot Ankle Surg* 51:714–719, 2012.
128. Abbassian A, Kohls-Gatzoulis J, Solan MC. Proximal medial gastrocnemius release in the treatment of recalcitrant plantar fasciitis. *Foot Ankle Int* 33:14–19, 2012.
129. Monteagudo M, Maceira E, Garcia-Virto V, Canosa R. Chronic plantar fasciitis: plantar fasciotomy versus gastrocnemius recession. *Int Orthop* 37:1845–1850, 2013.
130. Maskill JD, Bohay DR, Anderson JG. Gastrocnemius recession to treat isolated foot pain. *Foot Ankle Int* 31:19–23, 2010.
131. Allen BH, Fallat LM, Schwartz SM. Cryosurgery: an innovative technique for the treatment of plantar fasciitis. *J Foot Ankle Surg* 46:75–79, 2007.
132. Sorensen MD, Hyer CF, Philbin TM. Percutaneous bipolar radiofrequency microdebridement for recalcitrant proximal plantar fasciosis. *J Foot Ankle Surg* 50:165–170, 2011.