Overview of deep small bowel enteroscopy

Author
Hiroto Kita, MD, PhD

Section Editor
Douglas A Howell, MD, FASGE, FACG

Deputy Editor
Anne C Travis, MD, MSc, FACG, AGAF

All topics are updated as new evidence becomes available and our peer review process is complete.
Literature review current through: Sep 2014. | **This topic last updated:** Oct 23, 2013.

INTRODUCTION — Evaluation of the small bowel is difficult due to its length, intraperitoneal location, and contractility. Methods used to evaluate the small bowel include push enteroscopy, video capsule endoscopy, and intraoperative enteroscopy. These techniques all have advantages and limitations:

- Push enteroscopy has both diagnostic and therapeutic capabilities, but typically only examines that part of the small bowel that is 50 to 150 cm distal to the ligament of Treitz
- Video capsule endoscopy is capable of examining the entire small bowel, but lacks therapeutic capacity
- Intraoperative enteroscopy permits examination of the entire small bowel and therapeutic interventions, but is much more invasive

Alternative endoscopic approaches have been developed to overcome these limitations. Deep small bowel enteroscopy permits visualization and interventional therapy throughout the small bowel by using insertion techniques that pleat the small bowel onto an overtube. The techniques used for deep small bowel enteroscopy limit stretching of the small bowel (as occurs with push enteroscopy), permit better transmission of maneuvers designed to position the tip of the enteroscope, and stabilize the enteroscope, thereby facilitating therapeutic interventions.

Options for deep small bowel enteroscopy available in the United States include:

- Double balloon enteroscopy (Double Balloon Technology, Fujinon, Inc.)
- Single balloon enteroscopy (Single Balloon Enteroscope System, Olympus, Inc.)
- Spiral enteroscopy (Endo-Ease Discovery SB System, Spirus Medical LLC)

An additional option available outside the United States is the NaviAid Balloon Guided Endoscopy Device (Smart Medical Systems).

The first report of double balloon enteroscopy (DBE) appeared in 2001 [1], followed by the introduction of a dedicated system for DBE in 2003 [2]. Use of DBE has subsequently grown worldwide, and the first international workshop on DBE was held in Japan in August 2006. Single balloon enteroscopy (SBE) became commercially available in 2007 [3], and a spiral enteroscopy system was approved by the United States Food and Drug Administration for deep small bowel enteroscopy in 2008.

This topic will review the indications, techniques, and complications of balloon-assisted enteroscopy and spiral enteroscopy. Wireless video capsule endoscopy is discussed elsewhere. (See "Wireless video capsule endoscopy".)

INDICATIONS — Deep small bowel enteroscopy has multiple diagnostic and therapeutic applications, the most common being the evaluation of obscure gastrointestinal (GI) bleeding. (See "Evaluation of obscure gastrointestinal bleeding".)

Wireless capsule endoscopy is often preferred as an initial diagnostic test because it is noninvasive, well-tolerated, and

can view the entire small bowel [4]. However, deep small bowel enteroscopy is required in some patients, such as those with findings that require biopsy or therapeutic intervention. Deep small bowel enteroscopy may also be preferred when a small bowel stricture is suspected, since wireless capsule endoscopy in such patients is associated with an increased risk of capsule retention. (See "Wireless video capsule endoscopy", section on 'Capsule retention'.)

Diagnostic applications — Diagnostic applications for deep small bowel enteroscopy include:

- Evaluation of obscure gastrointestinal bleeding [4]
- Evaluation and tattooing of suspected small bowel malignancies (eg, adenocarcinoma, lymphoma, gastrointestinal stromal tumors, metastatic tumors) or abnormal findings on other imaging studies [5-11]
- Evaluation of suspected nonsteroidal anti-inflammatory drug-induced small bowel injury [12-15]
- Evaluation of suspected or established small bowel Crohn's disease [16]
- Evaluation of refractory celiac disease [17,18]
- Detection of polyps in patients with polyposis syndromes such as familial adenomatous polyposis or Peutz-Jeghers syndrome [19]
- Examination of the gastric remnant in patients who have undergone Roux-en-Y gastric bypass [20]
- Diagnostic endoscopic retrograde cholangiopancreatography (ERCP) in patients with Roux-en-Y anatomy [21,22]

Therapeutic applications — An advantage of deep small bowel enteroscopy compared with capsule endoscopy and radiologic methods to visualize the small bowel is the ability to perform a wide variety of therapeutic interventions [23-30]. Therapeutic applications for deep small bowel enteroscopy include:

- Treatment of gastrointestinal bleeding (eg, angiodysplasia)
- Small bowel polypectomy
- Stricture dilation
- Stenting of small bowel obstructions
- Foreign body retrieval (eg, retained video capsule) [31,32]
- Endoscopic mucosal resection [33]
- Placement of direct percutaneous jejunostomy
- In patients with Roux-en-Y reconstructions (figure 1), ERCP with lithotripsy, dilatation of a biliary stenosis, and/or stent placement [34-37]

Advanced techniques — Novel approaches involving balloon-assisted enteroscopy continue to be reported. These include a modified double balloon enteroscopy (DBE) technique to access the proximal side of a stricture in the distal colon (anterograde colonoscopy) by using a long transnasal decompression tube as a guide [38], balloon-assisted intubation of the ileocecal valve to facilitate retrograde DBE [39], and balloon dilation of obstructing small bowel strictures [40].

CONTRAINDICATIONS — In general, patients deemed fit to undergo endoscopic procedures are candidates for deep small bowel enteroscopy. However, some authors suggest that surgically altered gastrointestinal (GI) anatomy (eg, an ileoanal or ileocolonic anastomosis or an ileostomy) should be a relative contraindication because of a higher perforation rate [3]. (See 'Complications' below.)

Because of the risk of perforation, we suggest that the examination be carried out cautiously by providers who have significant experience with these procedures when patients with surgically altered GI tract anatomy require deep small bowel enteroscopy (eg, a patient who has undergone Roux-en-Y gastric bypass who needs an endoscopic retrograde cholangiopancreatography).

In addition, the balloons used for double balloon enteroscopy (though not for single balloon enteroscopy) are latex and should not be used in patients with latex allergies. (See "Latex allergy: Epidemiology, clinical manifestations, and diagnosis".)

BALLOON-ASSISTED ENTEROSCOPY — Balloon-assisted enteroscopy includes double balloon enteroscopy (DBE) and single balloon enteroscopy (SBE). While similar, the systems vary with regard to whether a balloon is attached only to the overtube (SBE) or also to the tip of the enteroscope (DBE), resulting in differences in the techniques used to perform the procedures. Limited data suggest that the systems have similar efficacy. (See 'Efficacy' below and 'Single balloon enteroscopy' below.)

Systems are also being developed to permit balloon-assisted enteroscopy using a balloon passed through the channel of a standard colonoscope (NaviAid Balloon System) [41].

Double balloon enteroscopy — There are three DBE systems available. The standard DBE system includes an endoscope with an 8.5 mm diameter and a 200 cm working length (Fujinon EN-450P5), a 145 cm soft overtube with an outer diameter of 12.2 mm, and a specifically designed pump (picture 1). After the overtube is backloaded onto the scope, a soft latex balloon is attached to the tip of the enteroscope. The balloon can be inflated and deflated using a pump through the air channel in the enteroscope. The flexible overtube also has a latex balloon at its tip that can be inflated and deflated. The pressure in both balloons is monitored and regulated at 5.6 kPa.

A therapeutic double balloon enteroscope (Fujinon EN-450T5) is also available. It is similar to the standard enteroscope with a 200 cm working length, but has a larger outer diameter (9.4 mm) so that it can accommodate a larger channel (2.8 mm in diameter). A shorter double balloon endoscope with a working length of 152 cm is also available (Fujinon EN-450B15). This endoscope will accept both endoscopic retrograde cholangiopancreatography (ERCP) length and colonoscopy length accessories and is primarily used for cases of incomplete colonoscopy and for ERCP in patients with surgically altered anatomy.

Patient preparation and sedation — Patients should fast after midnight the evening prior to the examination to allow time for food residue to clear the small bowel. In addition, patients undergoing retrograde examinations should receive a bowel preparation to cleanse the colon. (See "Bowel preparation for colonoscopy and flexible sigmoidoscopy in adults".)

Balloon-assisted enteroscopy can generally be performed under conscious sedation, though some centers prefer to perform anterograde procedures under general anesthesia. One reason for using general anesthesia is that it can be difficult to maintain adequate sedation throughout what is often a prolonged procedure. (See "Overview of procedural sedation for gastrointestinal endoscopy".)

Technique for DBE — Double balloon enteroscopy (DBE) can be performed from either the mouth (anterograde approach) or the anus (retrograde approach). The insertion route is chosen according to the estimated location of the suspected lesion(s). In a study of 60 patients undergoing DBE, an anterograde approach was used for lesions noted in the first 60 percent of a capsule endoscopy study (based on the time at which the lesion was noted in the small bowel relative to the total small bowel transit time), whereas a retrograde approach was used for lesions in the distal 40 percent [42]. Using this cut-off, the lesions were reached on the first examination in all patients.

With an antegrade examination, the enteroscope is advanced using repetitive cycles of balloon inflation/deflation and scope advancement (figure 2). During one cycle of the procedure, the scope is advanced until no further forward

progress is made. The balloon on the tip of the scope is then inflated, anchoring the small bowel. Once the small bowel is anchored by the enteroscope balloon, the balloon on the overtube is deflated (having been inflated during the prior cycle) and advanced until it reaches the inflated balloon on the scope. The balloon at the end of the overtube is then inflated, and with both balloons inflated, the scope and overtube are gently withdrawn to remove loops and pleat the small bowel onto the overtube. The balloon on the scope is then deflated, and the cycle is repeated until the scope can no longer be advanced or the lesion of interest is reached. The procedure is carried out in reverse during withdrawal of the scope.

The procedure is the same for retrograde examinations, except that the cycles of scope advancement and withdrawal are carried out in the colon as well as in the small bowel to ensure that there is no colonic looping prior to intubation of the terminal ileum.

The point of maximal insertion is frequently tattooed so that it can be identified on subsequent capsule endoscopy, deep small bowel enteroscopy from the opposite approach, or at the time of surgery. The maximal insertion depth may be limited in patients with adhesions due to prior surgery or inflammatory disorders.

Fluoroscopy may be used when initially learning balloon-assisted enteroscopy to permit the endoscopist to observe advancement and reduction of the enteroscope and to identify looping (image 1) [3].

Efficacy — The majority of the published data on balloon-assisted enteroscopy are from studies of double balloon enteroscopy (DBE). Multiple reports have described experience with DBE, and a few have compared it with other methods to visualize the small bowel [23,43-54]. Most of these studies focused on patients with obscure gastrointestinal bleeding. (See "Evaluation of obscure gastrointestinal bleeding", section on 'Enteroscopy'.)

Reported mean procedure times with DBE range from 73 to 123 minutes, with average small bowel insertion depths of 220 to 360 cm for antegrade examinations and 124 to 183 cm for retrograde examinations [23,49,52,55,56]. In a majority of patients without a significant history of abdominal surgery who undergo an antegrade examination, the mid to distal jejunum or proximal ileum can be reached within 40 to 80 minutes of examination time (not including the time to set up for the examination, which can be significant) [46,56].

Retrograde examinations are more difficult, and even in expert hands, the failure rates for ileal intubation during retrograde examinations range from 7 to 30 percent [52,56-58]. Even if the terminal ileum is intubated, adhesions may limit subsequent advancement to only 10 to 15 cm within the small bowel.

The reported rates of complete enteroscopy (ie, visualization of the entire small bowel, often through a combination of an anterograde and retrograde approach) vary widely. Rates of 70 to 86 percent have been reported in Japan [1,23,59] compared with 4 to 92 percent reported in the United States and Europe [45,55,56,60-62]. Lower rates of complete enteroscopy have been noted in patients who are obese and in operators with less experience with DBE. Typically, complete enteroscopy is accomplished by performing both an antegrade and a retrograde examination.

Diagnostic and therapeutic yields — The diagnostic yield of DBE ranges from 40 to 80 percent, with therapy being performed in 15 to 55 percent of patients [23,49,52,55,56,58]. A meta-analysis of 11 studies that compared DBE with capsule endoscopy estimated that the overall yield for clinically pertinent small bowel findings was similar with the two examinations (60 and 57 percent) [63]. The yield was also similar when comparing specific types of findings, such as vascular malformations (picture 2) (24 percent with both), tumors (picture 3) (11 percent with both), polyps (picture 4) (11 percent with both), and inflammatory lesions (18 and 16 percent).

A few studies have compared DBE with push enteroscopy and found better diagnostic yields with DBE [43,44]. The better diagnostic yields with DBE were in part related to higher rates of complete visualization of the small bowel (ie, total enteroscopy).

A study of 2245 DBE examinations in 1765 patients found that the diagnostic yield varied with the indication [61]:

- Peutz-Jegher's syndrome: 82 percent
- Mid-gastrointestinal bleeding: 53 percent
- Crohn's disease: 47 percent
- Abdominal pain: 19 percent
- Diarrhea: 16 percent

In patients with mid-gastrointestinal bleeding due to angiodysplasia, DBE allows for effective treatment with argon plasma coagulation (APC), though recurrent bleeding is common [64,65]. In a study of 50 patients with small bowel lesions, 44 patients (88 percent) were treated with APC for angiodysplasia [64]. After a mean follow-up of 55 months, hemoglobin levels increased from a mean of 7.6 g/dL prior to treatment to 11.0 g/dL following treatment. In addition, there was a significant decrease in the number of patients requiring blood transfusions, from 30 patients prior to treatment to 8 patients following treatment. However, small bowel bleeding recurred in 21 of the patients (48 percent) treated with APC.

In a second study that included 98 patients with small bowel vascular lesions who were followed following treatment during DBE (primarily with APC), rebleeding occurred in 45 (46 percent) at 36 months [65]. Factors that increased the risk of bleeding included the total number of observed lesions and the presence of valvular and or arrhythmic cardiac disease.

Learning curve — The technical skill to perform DBE improves with experience. The learning curve for DBE was evaluated in a study involving six tertiary centers in the United States [56]. A total of 188 patients underwent 237 DBE procedures, mainly for obscure gastrointestinal bleeding. About two-thirds of the cases were antegrade. The mean procedure duration for antegrade examinations was 102 ± 45 minutes for the first 10 cases, declining to 90 ± 37 minutes thereafter. The improvement in procedure duration was observed only for anterograde cases, with no change in mean procedure time being observed for retrograde examinations. In addition, retrograde cases failed to reach the small bowel in 31 percent of cases.

It has been estimated that the learning curve for antegrade examinations is approximately 10 cases, compared with 20 to 30 cases for retrograde examinations [3,66]. However, some endoscopists require more than 100 to 150 cases to develop expertise [55].

Complications — The overall complication rates for DBE in large series have ranged from 1.2 to 1.6 percent [61,67,68]. A meta-analysis found that minor complications occurred in 9.1 percent of procedures, whereas major complications were reported in 0.7 percent. Complications include pancreatitis, perforation, bleeding, and aspiration pneumonia [61,67-70]. The rate of complications may be higher for patients undergoing therapeutic procedures compared with those undergoing diagnostic procedures (eg, 4.3 versus 0.8 percent in a series of 2362 procedures) [67].

Pancreatitis — Pancreatitis is the most common significant complication of DBE. The rate of pancreatitis following DBE is approximately 0.3 percent based upon data from three series with a total of 8734 procedures [67,68,70]. The cause of pancreatitis is uncertain, but may be related to physical trauma to the pancreas. It is important to distinguish clinical pancreatitis from hyperamylasemia alone, which occurs in approximately 50 percent of patients, especially following long procedures [71,72]. There are no proven methods to reduce the incidence of pancreatitis.

Perforation — The rate of perforation is 0.3 to 0.4 percent [67,68,70]. The cause of perforation is likely to be multifactorial. In one report, perforation occurred in two patients who may have been at increased risk due to inflammation [23]. One had intestinal lymphoma and had received chemotherapy, while the other had Crohn's disease.

Therapeutic interventions also increase the risk of perforation. In one series, 3.4 percent of polypectomies were complicated by perforation [68]. The risk is also increased if stricture dilation is carried out in the setting of active ulceration. Balloon dilation in these cases should be postponed until the ulcer has healed [73].

Surgically altered gastrointestinal (GI) anatomy is another risk factor for perforation. In one series, the rate of perforation in 219 examinations in patients with surgically altered anatomy was 3 percent [70]. Patients who may be at particularly increased risk include those with an ileoanal or ileocolonic anastomosis and those having their examination performed through a stoma. This has led some authorities to suggest that altered surgical GI anatomy should be considered a relative contraindication to balloon-assisted enteroscopy. (See 'Contraindications' above.)

Given these risk factors for perforation, we suggest that further insertion of the enteroscope across the lesion be avoided when fragile lesions such as active ulceration are encountered in the small intestine. In addition, DBE should be performed with caution in patients with a history of GI tract surgery.

Bleeding — Bleeding has been reported in approximately 0.2 percent of procedures [68,70]. Polypectomy and biopsy appear to be risk factors for bleeding.

Other — Additional reported complications include two cases of aspiration pneumonia in a series of 265 procedures [69], one cecal volvulus in a series of 2478 procedures [70], and a case report that described severe esophageal trauma from the overtube in a patient with eosinophilic esophagitis, a condition known to predispose to mucosal tearing [74]. (See "Clinical manifestations and diagnosis of eosinophilic esophagitis".)

Single balloon enteroscopy — The SBE system uses a 200 cm high-resolution enteroscope (Olympus SIF-Q180) with a 2.8 mm working channel. The overtube is 140 cm long with a 13.2 mm outer diameter. The overtube is equipped with a silicone balloon at its tip, which can be inflated and deflated with a pressure setting range of -6.0 to + 5.4 kPa.

The technique for SBE is similar to that used for DBE. (See 'Technique for DBE' above.) Like DBE, SBE uses an overtube with a distal balloon to aid with scope advancement through the small bowel. However, SBE uses the scope's flexible tip to anchor the scope, rather than a second balloon on the tip of the enteroscope as with DBE (figure 3). Anchoring stabilizes the scope, permitting advancement of the overtube. The overtube balloon is then inflated, and the tip of the enteroscope is straightened. With the overtube balloon inflated, the scope and overtube can be withdrawn, pleating the small bowel onto the overtube. The enteroscope is then advanced. Like DBE, the cycle of advancement and withdrawal is repeated until the scope can no longer be advanced or the lesion of interest is reached. As with DBE, the point of maximal insertion is frequently marked with a tattoo.

Experience with SBE suggests that its efficacy is similar to that of DBE. Diagnostic yields have ranged from 41 to 65 percent, and therapeutic yields have ranged from 7 to 50 percent [57,75-83]. Average depths of small bowel insertion range from 133 to 270 cm for antegrade examinations and 73 to 199 cm for retrograde examinations [75,78,80,81,83]. However, the rate of total enteroscopy may be lower than with DBE at 0 to 24 percent [75-77,82]. In our experience, this is largely due to more difficult intubation of the terminal ileum with SBE compared with DBE. With DBE, the balloon on the tip of the enteroscope can anchor the scope in the small bowel while the overtube is advanced. This is not an option with SBE, so it is harder to maintain position of the enteroscope within the small bowel during overtube advancement. (See 'Diagnostic and therapeutic yields' above.)

The majority of the data on complications of balloon-assisted enteroscopy come from studies of DBE. Complications that have been reported with SBE include abdominal pain, fever, pancreatitis (following endoscopic retrograde cholangioscopy), mucosal tears, and perforation [57,75-78,81,84,85]. (See 'Complications' above.)

SPIRAL ENTEROSCOPY — Spiral enteroscopy is an alternative to balloon-assisted enteroscopy for antegrade evaluation of the small bowel. The method was developed in an attempt to provide a simpler, faster method for deep small bowel enteroscopy. Spiral enteroscopy uses an overtube with a soft raised helix at its distal end (Endo-Ease Discovery SB, Spirus Medical, Inc, Stoughton, MA) (picture 5).

Like balloon-assisted enteroscopy, spiral enteroscopy can be performed using conscious sedation or general anesthesia. However, if the patient is endotracheally intubated, the anesthesiologist should be asked to deflate the cuff

on the endotracheal tube until the spiral is completely within the stomach to prevent esophageal trauma that may be induced by the raised helical spirals on the overtube. (See "Overview of procedural sedation for gastrointestinal endoscopy".)

The 118-cm overtube is compatible with enteroscopes that are 200 cm long and between 9.1 and 9.5 mm in diameter (ie, the enteroscopes used for double balloon or single balloon enteroscopy, but not standard enteroscopes). The spirals on the overtube are either 4.5 mm (low profile) or 5.5 mm (standard profile) high. The overtube has a coupling device that affixes it to the scope, while permitting rotation of the overtube. By rotating the overtube clockwise, the small bowel is pleated onto the overtube, and the enteroscope is advanced.

Data on spiral enteroscopy are limited. Initial reports suggest decreased procedure times and similar depths of insertion compared with balloon-assisted enteroscopy and low complication rates [81,86-91]. However, other reports suggest lower rates of complete small bowel enteroscopy with spiral enteroscopy compared with balloon-assisted enteroscopy. This, however, is not surprising since spiral enteroscopy is performed from an antegrade approach, whereas balloon-assisted enteroscopy can be performed both antegrade and retrograde, increasing the chances for complete enteroscopy. In one study, the rate of complete small bowel enteroscopy was much lower for spiral enteroscopy compared with balloon assisted enteroscopy (8 versus 92 percent), though the rate of complete small bowel enteroscopy with balloon-assisted enteroscopy was higher than that reported in many studies [62]. (See 'Efficacy' above.) In addition, the reported yield of spiral enteroscopy in some studies has been lower than that seen with balloon-assisted enteroscopy and varies by indication.

- In a study of 27 patients with obscure gastrointestinal bleeding, 25 underwent spiral enteroscopy [86]. The examination could not be carried out in two patients (due to a Schatzki ring or an inability to advance the overtube into the esophagus). The depth of insertion ranged from 80 to 340 cm from the ligament of Treitz (mean 175 cm), and the procedure time ranged from 19 to 65 minutes (mean 37 minutes). Possible sources of bleeding were noted in nine patients (33 percent), including angiodysplasia in eight and a duodenal ulcer in one. All of the angiodysplasias were treated with bipolar cautery. There were no major complications. Superficial esophageal mucosal trauma was noted in 22 percent of patients, and a postprocedure sore throat was noted in 28 percent.

- In a second report, 90 procedures were carried out in 95 patients [87]. The most common indications for the procedure were abdominal pain with loose stools or diarrhea (72 percent), occult gastrointestinal bleeding (12 percent), overt gastrointestinal bleeding (3 percent), a history of intestinal polyps (11 percent), and chronic abdominal pain alone (3 percent). In five of the patients, the overtube did not successfully engage the small bowel. The mean procedure time was 34 ± 8 minutes, and the mean depth of insertion was 262 ± 57 cm. Notable findings were present in 12 percent of the patients. There were no perforations and only two cases of deep mucosal tears associated with the procedure.

- In a third series of 61 patients, the procedure was successfully completed in 56 patients (92 percent). The most common indication was gastrointestinal bleeding (85 percent). The average depth of insertion was 217 ± 79 cm, and the mean procedure time was 41 ± 15 minutes [88]. Positive findings were present in 36 patients (59 percent), and therapeutic maneuvers were carried out in 30 patients (49 percent). Complications included bradycardia requiring procedure termination (one patient), mucosal abrasions in the esophagus (2 patients), and abdominal pain necessitating hospital admission.

- A low rate of complications was reported in a series of 1750 cases [90]. Severe complications were reported in seven procedures (0.4 percent). Six of the complications were perforations, and all occurred as the enteroscope was being pushed through the overtube. Three of the perforations occurred with clinicians who had performed fewer than 10 cases [90].

The yield of spiral enteroscopy in patients with positive findings on capsule endoscopy has also been examined. One

study included 56 spiral enteroscopy procedures [92]. Findings on capsule endoscopy included angiodysplasia (26 patients), masses (eight patients), ulcers (four patients), polyps (four patients), abnormal mucosa (six patients), fresh blood (six patients), and stricture (one patient). The findings on capsule endoscopy were reproduced with spiral enteroscopy in 30 patients (54 percent). The type of finding on capsule endoscopy was associated with reproducibility on spiral enteroscopy. Blood was reproducible in 86 percent of patients, angiodysplasia in 69 percent, abnormal mucosa in 50 percent, masses in 38 percent, polyps in 33 percent, and ulcers and strictures in zero percent.

SUMMARY AND RECOMMENDATIONS

- Deep small bowel enteroscopy permits visualization and interventional therapy throughout the small bowel.
- Available options for deep small bowel enteroscopy include double balloon enteroscopy (DBE), single balloon enteroscopy (SBE), and spiral enteroscopy. (See 'Introduction' above.)
- Balloon-assisted enteroscopy (ie, DBE and SBE) can be performed orally or per rectum, whereas spiral enteroscopy can only be performed orally.
- The most common indication for deep small bowel enteroscopy is the evaluation of obscure gastrointestinal bleeding. There are multiple other indications, including the evaluation of suspected small bowel malignancies and the evaluation of small bowel Crohn's disease. (See 'Diagnostic applications' above.)
- Therapeutic applications for deep small bowel enteroscopy include the treatment of gastrointestinal bleeding from the small bowel, small bowel polypectomy, and small bowel stricture dilation. (See 'Therapeutic applications' above.)
- We suggest that deep small bowel enteroscopy (rather than wireless capsule endoscopy, push enteroscopy, or intraoperative enteroscopy) be used when (**Grade 2C**):
  - There are findings on wireless capsule endoscopy or radiographic small bowel imaging that require biopsy or therapeutic intervention, including active bleeding from the small bowel that is out of reach of a standard endoscope
  - There is suspicion for a small bowel lesion despite a negative capsule study
  - There is suspicion of impaction of a video capsule proximal to a small bowel stricture
- Deep small bowel enteroscopy is generally well tolerated, but has been associated with many of the complications seen with other forms of endoscopy. The two most common serious complications are perforation and pancreatitis. (See 'Complications' above and 'Single balloon enteroscopy' above and 'Spiral enteroscopy' above.)

REFERENCES

1. Yamamoto H, Sekine Y, Sato Y, et al. Total enteroscopy with a nonsurgical steerable double-balloon method. Gastrointest Endosc 2001; 53:216.
2. Yamamoto H, Yano T, Kita H, et al. New system of double-balloon enteroscopy for diagnosis and treatment of small intestinal disorders. Gastroenterology 2003; 125:1556; author reply 1556.
3. Gerson LB, Flodin JT, Miyabayashi K. Balloon-assisted enteroscopy: technology and troubleshooting. Gastrointest Endosc 2008; 68:1158.
4. Westerhof J, Weersma RK, Koornstra JJ. Investigating obscure gastrointestinal bleeding: capsule endoscopy or double balloon enteroscopy? Neth J Med 2009; 67:260.

5. Yoshida N, Wakabayashi N, Nomura K, et al. Ileal mucosa-associated lymphoid tissue lymphoma showing several ulcer scars detected using double-balloon endoscopy. Endoscopy 2004; 36:1022.
6. Iwamoto M, Yamamoto H, Kita H, et al. Double-balloon endoscopy for ileal GI stromal tumor. Gastrointest Endosc 2005; 62:440.
7. Kunihiro K, Manabe N, Hata J, et al. Gastrointestinal stromal tumor in jejunum: diagnosis using contrast-enhanced ultrasonography and double-balloon enteroscopy. Dig Dis Sci 2006; 51:1236.
8. Yamaguchi T, Manabe N, Tanaka S, et al. Multiple carcinoid tumors of the ileum preoperatively diagnosed by enteroscopy with the double-balloon technique. Gastrointest Endosc 2005; 62:315.
9. Ji JS, Choi H, Choi KY, et al. Two cases of GI involvement of Gorham's disease diagnosed by double-balloon enteroscopy: case report and review of the literature. Gastrointest Endosc 2005; 62:312.
10. Ross A, Mehdizadeh S, Tokar J, et al. Double balloon enteroscopy detects small bowel mass lesions missed by capsule endoscopy. Dig Dis Sci 2008; 53:2140.
11. Yamagami H, Oshitani N, Hosomi S, et al. Usefulness of double-balloon endoscopy in the diagnosis of malignant small-bowel tumors. Clin Gastroenterol Hepatol 2008; 6:1202.
12. Hayashi Y, Yamamoto H, Kita H, et al. Non-steroidal anti-inflammatory drug-induced small bowel injuries identified by double-balloon endoscopy. World J Gastroenterol 2005; 11:4861.
13. Yen HH, Chen YY, Soon MS. Nonsteroidal anti-inflammatory drug-associated ileal ulcers: an evaluation by double-balloon enteroscopy. Gastrointest Endosc 2006; 63:328; discussion 328.
14. Nosho K, Endo T, Yoda Y, et al. Diaphragm disease of small intestine diagnosed by double-balloon enteroscopy. Gastrointest Endosc 2005; 62:187.
15. Kamata Y, Iwamoto M, Nara H, et al. A case of rheumatoid arthritis with protein losing enteropathy induced by multiple diaphragmatic strictures of the small intestine: successful treatment by bougieing under double-balloon enteroscopy. Gut 2006; 55:1372.
16. Oshitani N, Yukawa T, Yamagami H, et al. Evaluation of deep small bowel involvement by double-balloon enteroscopy in Crohn's disease. Am J Gastroenterol 2006; 101:1484.
17. Fry LC, Bellutti M, Neumann H, et al. Utility of double-balloon enteroscopy for the evaluation of malabsorption. Dig Dis 2008; 26:134.
18. Hadithi M, Al-toma A, Oudejans J, et al. The value of double-balloon enteroscopy in patients with refractory celiac disease. Am J Gastroenterol 2007; 102:987.
19. Matsumoto T, Esaki M, Yanaru-Fujisawa R, et al. Small-intestinal involvement in familial adenomatous polyposis: evaluation by double-balloon endoscopy and intraoperative enteroscopy. Gastrointest Endosc 2008; 68:911.
20. Sakai P, Kuga R, Safatle-Ribeiro AV, et al. Is it feasible to reach the bypassed stomach after Roux-en-Y gastric bypass for morbid obesity? The use of the double-balloon enteroscope. Endoscopy 2005; 37:566.
21. Shah RJ, Smolkin M, Yen R, et al. A multicenter, U.S. experience of single-balloon, double-balloon, and rotational overtube-assisted enteroscopy ERCP in patients with surgically altered pancreaticobiliary anatomy (with video). Gastrointest Endosc 2013; 77:593.
22. Samarasena JB, Nguyen NT, Lee JG. Endoscopic retrograde cholangiopancreatography in patients with roux-en-Y anatomy. J Interv Gastroenterol 2012; 2:78.
23. Yamamoto H, Kita H, Sunada K, et al. Clinical outcomes of double-balloon endoscopy for the diagnosis and treatment of small-intestinal diseases. Clin Gastroenterol Hepatol 2004; 2:1010.
24. Sunada K, Yamamoto H, Kita H, et al. Case Report: Successful treatment with balloon dilatation in combination with double-balloon enteroscopy of a stricture in the small bowel of a patient with Crohn's disease. Digest Endosc 2004; 16:237.
25. Sunada K, Yamamoto H, Kita H, et al. Clinical outcomes of enteroscopy using the double-balloon method for strictures of the small intestine. World J Gastroenterol 2005; 11:1087.
26. Ohmiya N, Taguchi A, Shirai K, et al. Endoscopic resection of Peutz-Jeghers polyps throughout the small intestine at double-balloon enteroscopy without laparotomy. Gastrointest Endosc 2005; 61:140.
27. Yen HH, Chen YY, Soon MS, Lin YM. An unusual cause of obscure gastrointestinal bleeding. Gut 2007; 56:12, 28.

28. Nishimura M, Yamamoto H, Kita H, et al. Gastrointestinal stromal tumor in the jejunum: diagnosis and control of bleeding with electrocoagulation by using double-balloon enteroscopy. J Gastroenterol 2004; 39:1001.
29. Kuno A, Yamamoto H, Kita H, et al. Double-balloon enteroscopy through a Roux-en-Y anastomosis for EMR of an early carcinoma in the afferent duodenal limb. Gastrointest Endosc 2004; 60:1032.
30. Kita H, Yamamoto H, Nakamura T, et al. Bleeding polyp in the mid small intestine identified by capsule endoscopy and treated by double-balloon endoscopy. Gastrointest Endosc 2005; 61:628.
31. Lee BI, Choi H, Choi KY, et al. Retrieval of a retained capsule endoscope by double-balloon enteroscopy. Gastrointest Endosc 2005; 62:463.
32. May A, Nachbar L, Ell C. Extraction of entrapped capsules from the small bowel by means of push-and-pull enteroscopy with the double-balloon technique. Endoscopy 2005; 37:591.
33. Kita H, Yamamoto H. New indications of double balloon endoscopy. Gastrointest Endosc 2007; 66:S57.
34. Emmett DS, Mallat DB. Double-balloon ERCP in patients who have undergone Roux-en-Y surgery: a case series. Gastrointest Endosc 2007; 66:1038.
35. Mönkemüller K, Fry LC, Bellutti M, et al. ERCP with the double balloon enteroscope in patients with Roux-en-Y anastomosis. Surg Endosc 2009; 23:1961.
36. Saleem A, Baron TH, Gostout CJ, et al. Endoscopic retrograde cholangiopancreatography using a single-balloon enteroscope in patients with altered Roux-en-Y anatomy. Endoscopy 2010; 42:656.
37. Matsushita M, Shimatani M, Ikeura T, et al. ERCP for altered Roux-en-Y anatomy: a single-balloon or short double-balloon enteroscope? Endoscopy 2011; 43:169.
38. Yano T, Yamamoto H, Kita H, et al. Technical modification of the double-balloon endoscopy to access to the proximal side of the stenosis in the distal colon. Gastrointest Endosc 2005; 62:302.
39. Ross AS, Waxman I, Semrad C, Dye C. Balloon-assisted intubation of the ileocecal valve to facilitate retrograde double-balloon enteroscopy. Gastrointest Endosc 2005; 62:987.
40. Ohmiya N, Arakawa D, Nakamura M, et al. Small-bowel obstruction: diagnostic comparison between double-balloon endoscopy and fluoroscopic enteroclysis, and the outcome of enteroscopic treatment. Gastrointest Endosc 2009; 69:84.
41. Ali R, Diehl D, Shieh F, et al. Deep enteroscopy with a conventional colonoscope: Initial multicenter study using the NaviAid balloon system. Am J Gastroenterol 2013; 108:S596.
42. Li X, Chen H, Dai J, et al. Predictive role of capsule endoscopy on the insertion route of double-balloon enteroscopy. Endoscopy 2009; 41:762.
43. Matsumoto T, Moriyama T, Esaki M, et al. Performance of antegrade double-balloon enteroscopy: comparison with push enteroscopy. Gastrointest Endosc 2005; 62:392.
44. May A, Nachbar L, Schneider M, Ell C. Prospective comparison of push enteroscopy and push-and-pull enteroscopy in patients with suspected small-bowel bleeding. Am J Gastroenterol 2006; 101:2016.
45. May A, Nachbar L, Wardak A, et al. Double-balloon enteroscopy: preliminary experience in patients with obscure gastrointestinal bleeding or chronic abdominal pain. Endoscopy 2003; 35:985.
46. May A, Nachbar L, Ell C. Double-balloon enteroscopy (push-and-pull enteroscopy) of the small bowel: feasibility and diagnostic and therapeutic yield in patients with suspected small bowel disease. Gastrointest Endosc 2005; 62:62.
47. Ell C, May A, Nachbar L, et al. Push-and-pull enteroscopy in the small bowel using the double-balloon technique: results of a prospective European multicenter study. Endoscopy 2005; 37:613.
48. Mönkemüller K, Weigt J, Treiber G, et al. Diagnostic and therapeutic impact of double-balloon enteroscopy. Endoscopy 2006; 38:67.
49. Heine GD, Hadithi M, Groenen MJ, et al. Double-balloon enteroscopy: indications, diagnostic yield, and complications in a series of 275 patients with suspected small-bowel disease. Endoscopy 2006; 38:42.
50. Kaffes AJ, Koo JH, Meredith C. Double-balloon enteroscopy in the diagnosis and the management of small-bowel diseases: an initial experience in 40 patients. Gastrointest Endosc 2006; 63:81.

51. Sun B, Rajan E, Cheng S, et al. Diagnostic yield and therapeutic impact of double-balloon enteroscopy in a large cohort of patients with obscure gastrointestinal bleeding. Am J Gastroenterol 2006; 101:2011.
52. Di Caro S, May A, Heine DG, et al. The European experience with double-balloon enteroscopy: indications, methodology, safety, and clinical impact. Gastrointest Endosc 2005; 62:545.
53. Tanaka S, Mitsui K, Yamada Y, et al. Diagnostic yield of double-balloon endoscopy in patients with obscure GI bleeding. Gastrointest Endosc 2008; 68:683.
54. Gerson LB, Batenic MA, Newsom SL, et al. Long-term outcomes after double-balloon enteroscopy for obscure gastrointestinal bleeding. Clin Gastroenterol Hepatol 2009; 7:664.
55. Gross SA, Stark ME. Initial experience with double-balloon enteroscopy at a U.S. center. Gastrointest Endosc 2008; 67:890.
56. Mehdizadeh S, Ross A, Gerson L, et al. What is the learning curve associated with double-balloon enteroscopy? Technical details and early experience in 6 U.S. tertiary care centers. Gastrointest Endosc 2006; 64:740.
57. Aktas H, de Ridder L, Haringsma J, et al. Complications of single-balloon enteroscopy: a prospective evaluation of 166 procedures. Endoscopy 2010; 42:365.
58. Sanaka MR, Navaneethan U, Kosuru B, et al. Antegrade is more effective than retrograde enteroscopy for evaluation and management of suspected small-bowel disease. Clin Gastroenterol Hepatol 2012; 10:910.
59. Nakase H, Matsuura M, Mikami S, Chiba T. Diagnosis and treatment of obscure GI bleeding with double balloon endoscopy. Gastrointest Endosc 2007; 66:S78.
60. May A, Nachbar L, Schneider M, et al. Push-and-pull enteroscopy using the double-balloon technique: method of assessing depth of insertion and training of the enteroscopy technique using the Erlangen Endo-Trainer. Endoscopy 2005; 37:66.
61. Möschler O, May A, Müller MK, et al. Complications in and performance of double-balloon enteroscopy (DBE): results from a large prospective DBE database in Germany. Endoscopy 2011; 43:484.
62. Messer I, May A, Manner H, Ell C. Prospective, randomized, single-center trial comparing double-balloon enteroscopy and spiral enteroscopy in patients with suspected small-bowel disorders. Gastrointest Endosc 2013; 77:241.
63. Pasha SF, Leighton JA, Das A, et al. Double-balloon enteroscopy and capsule endoscopy have comparable diagnostic yield in small-bowel disease: a meta-analysis. Clin Gastroenterol Hepatol 2008; 6:671.
64. May A, Friesing-Sosnik T, Manner H, et al. Long-term outcome after argon plasma coagulation of small-bowel lesions using double-balloon enteroscopy in patients with mid-gastrointestinal bleeding. Endoscopy 2011; 43:759.
65. Samaha E, Rahmi G, Landi B, et al. Long-term outcome of patients treated with double balloon enteroscopy for small bowel vascular lesions. Am J Gastroenterol 2012; 107:240.
66. Mehdizadeh S, Han NJ, Cheng DW, et al. Success rate of retrograde double-balloon enteroscopy. Gastrointest Endosc 2007; 65:633.
67. Mensink PB, Haringsma J, Kucharzik T, et al. Complications of double balloon enteroscopy: a multicenter survey. Endoscopy 2007; 39:613.
68. Möschler O, May AD, Müller MK, et al. [Complications in double-balloon-enteroscopy: results of the German DBE register]. Z Gastroenterol 2008; 46:266.
69. Tanaka S, Mitsui K, Tatsuguchi A, et al. Current status of double balloon endoscopy--indications, insertion route, sedation, complications, technical matters. Gastrointest Endosc 2007; 66:S30.
70. Gerson LB, Tokar J, Chiorean M, et al. Complications associated with double balloon enteroscopy at nine US centers. Clin Gastroenterol Hepatol 2009; 7:1177.
71. Honda K, Itaba S, Mizutani T, et al. An increase in the serum amylase level in patients after peroral double-balloon enteroscopy: an association with the development of pancreatitis. Endoscopy 2006; 38:1040.
72. Kopácová M, Rejchrt S, Tachecí I, Bures J. Hyperamylasemia of uncertain significance associated with oral double-balloon enteroscopy. Gastrointest Endosc 2007; 66:1133.
73. Yano T, Yamamoto H. Current state of double balloon endoscopy: the latest approach to small intestinal diseases. J Gastroenterol Hepatol 2009; 24:185.

74. Kuga R, Furuya CK Jr, Ide E, et al. Eosinophilic esophagitis and double-balloon enteroscopy: a dangerous combination. Endoscopy 2009; 41 Suppl 2:E85.
75. Tsujikawa T, Saitoh Y, Andoh A, et al. Novel single-balloon enteroscopy for diagnosis and treatment of the small intestine: preliminary experiences. Endoscopy 2008; 40:11.
76. May A, Färber M, Aschmoneit I, et al. Prospective multicenter trial comparing push-and-pull enteroscopy with the single- and double-balloon techniques in patients with small-bowel disorders. Am J Gastroenterol 2010; 105:575.
77. Kawamura T, Yasuda K, Tanaka K, et al. Clinical evaluation of a newly developed single-balloon enteroscope. Gastrointest Endosc 2008; 68:1112.
78. Upchurch BR, Sanaka MR, Lopez AR, Vargo JJ. The clinical utility of single-balloon enteroscopy: a single-center experience of 172 procedures. Gastrointest Endosc 2010; 71:1218.
79. Frantz DJ, Dellon ES, Grimm IS, Morgan DR. Single-balloon enteroscopy: results from an initial experience at a U.S. tertiary-care center. Gastrointest Endosc 2010; 72:422.
80. Ramchandani M, Reddy DN, Gupta R, et al. Diagnostic yield and therapeutic impact of single-balloon enteroscopy: series of 106 cases. J Gastroenterol Hepatol 2009; 24:1631.
81. Khashab MA, Lennon AM, Dunbar KB, et al. A comparative evaluation of single-balloon enteroscopy and spiral enteroscopy for patients with mid-gut disorders. Gastrointest Endosc 2010; 72:766.
82. Takano N, Yamada A, Watabe H, et al. Single-balloon versus double-balloon endoscopy for achieving total enteroscopy: a randomized, controlled trial. Gastrointest Endosc 2011; 73:734.
83. Domagk D, Mensink P, Aktas H, et al. Single- vs. double-balloon enteroscopy in small-bowel diagnostics: a randomized multicenter trial. Endoscopy 2011; 43:472.
84. Wang AY, Sauer BG, Behm BW, et al. Single-balloon enteroscopy effectively enables diagnostic and therapeutic retrograde cholangiography in patients with surgically altered anatomy. Gastrointest Endosc 2010; 71:641.
85. Yip WM, Lok KH, Lai L, et al. Acute pancreatitis: rare complication of retrograde single-balloon enteroscopy. Endoscopy 2009; 41 Suppl 2:E324.
86. Akerman PA, Agrawal D, Chen W, et al. Spiral enteroscopy: a novel method of enteroscopy by using the Endo-Ease Discovery SB overtube and a pediatric colonoscope. Gastrointest Endosc 2009; 69:327.
87. Buscaglia JM, Dunbar KB, Okolo PI 3rd, et al. The spiral enteroscopy training initiative: results of a prospective study evaluating the Discovery SB overtube device during small bowel enteroscopy (with video). Endoscopy 2009; 41:194.
88. Judah JR, Draganov PV, Lam Y, et al. Spiral enteroscopy is safe and effective for an elderly United States population of patients with numerous comorbidities. Clin Gastroenterol Hepatol 2010; 8:572.
89. Akerman PA, Agrawal D, Cantero D, Pangtay J. Spiral enteroscopy with the new DSB overtube: a novel technique for deep peroral small-bowel intubation. Endoscopy 2008; 40:974.
90. Akerman P, Contero D. Severe complications of spiral endoscopy in the first 1750 patients. Gastrointest Endosc 2009; 69:AB127.
91. Morgan D, Upchurch B, Draganov P, et al. Spiral enteroscopy: prospective U.S. multicenter study in patients with small-bowel disorders. Gastrointest Endosc 2010; 72:992.
92. Buscaglia JM, Richards R, Wilkinson MN, et al. Diagnostic yield of spiral enteroscopy when performed for the evaluation of abnormal capsule endoscopy findings. J Clin Gastroenterol 2011; 45:342.

Topic 2652 Version 19.0

GRAPHICS

Components of Roux-en-Y gastric bypass procedure

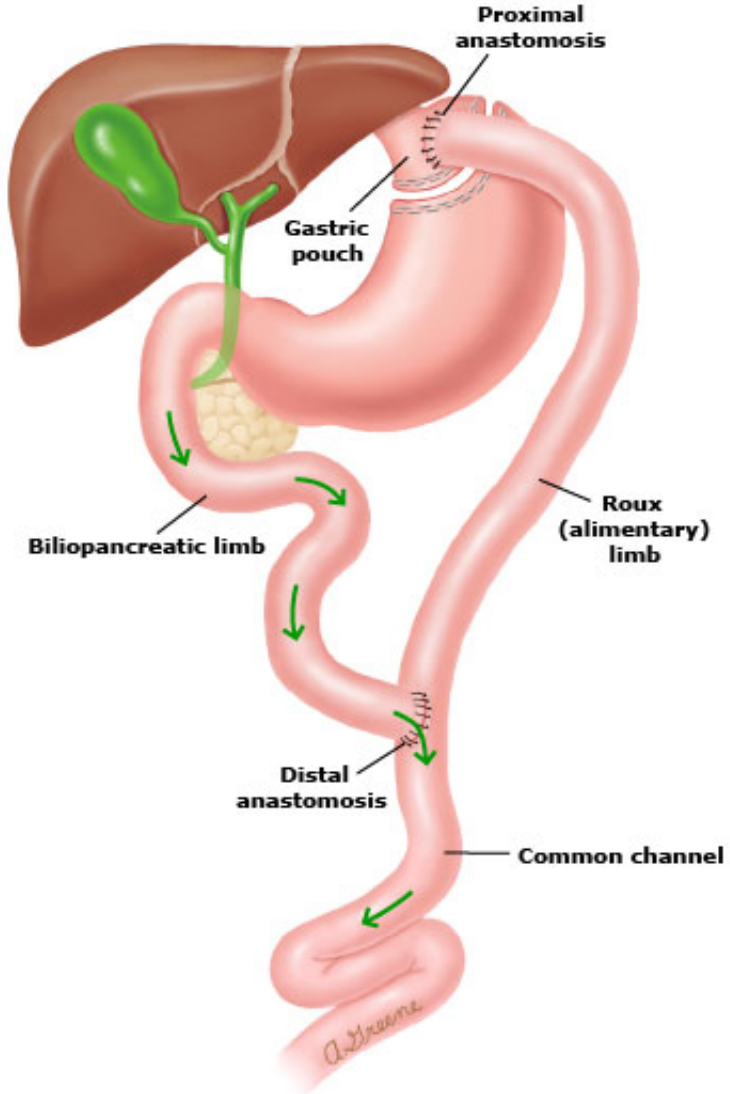

This figure depicts the components of a Roux-en-Ygastric (RYGB) bypass procedure. RYGB involves the creation of a small gastric pouch and an anastomosis to a Roux limb of jejunum that bypasses 75 to 150 cm of small bowel, thereby restricting food and limiting absorption

Graphic 52350 Version 1.0

Double balloon endoscopy system

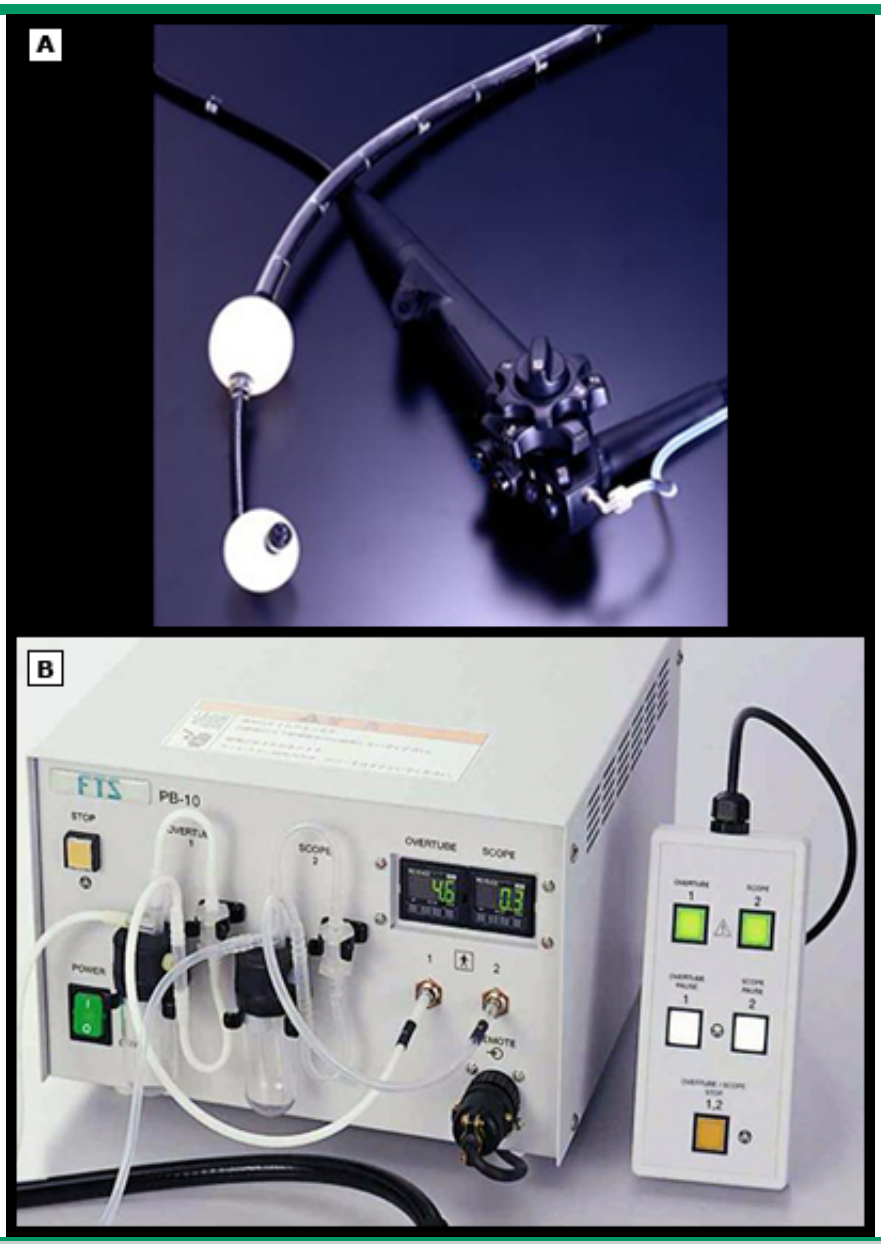

Double balloon endoscopy system showing the endoscope, overtube, and balloons (panel A) as well as the pump and controller for balloon inflation and deflation (panel B).

Reproduced with permission from: Professor Dr. Christian Ell.

Graphic 53187 Version 1.0

Double balloon endoscopy technique

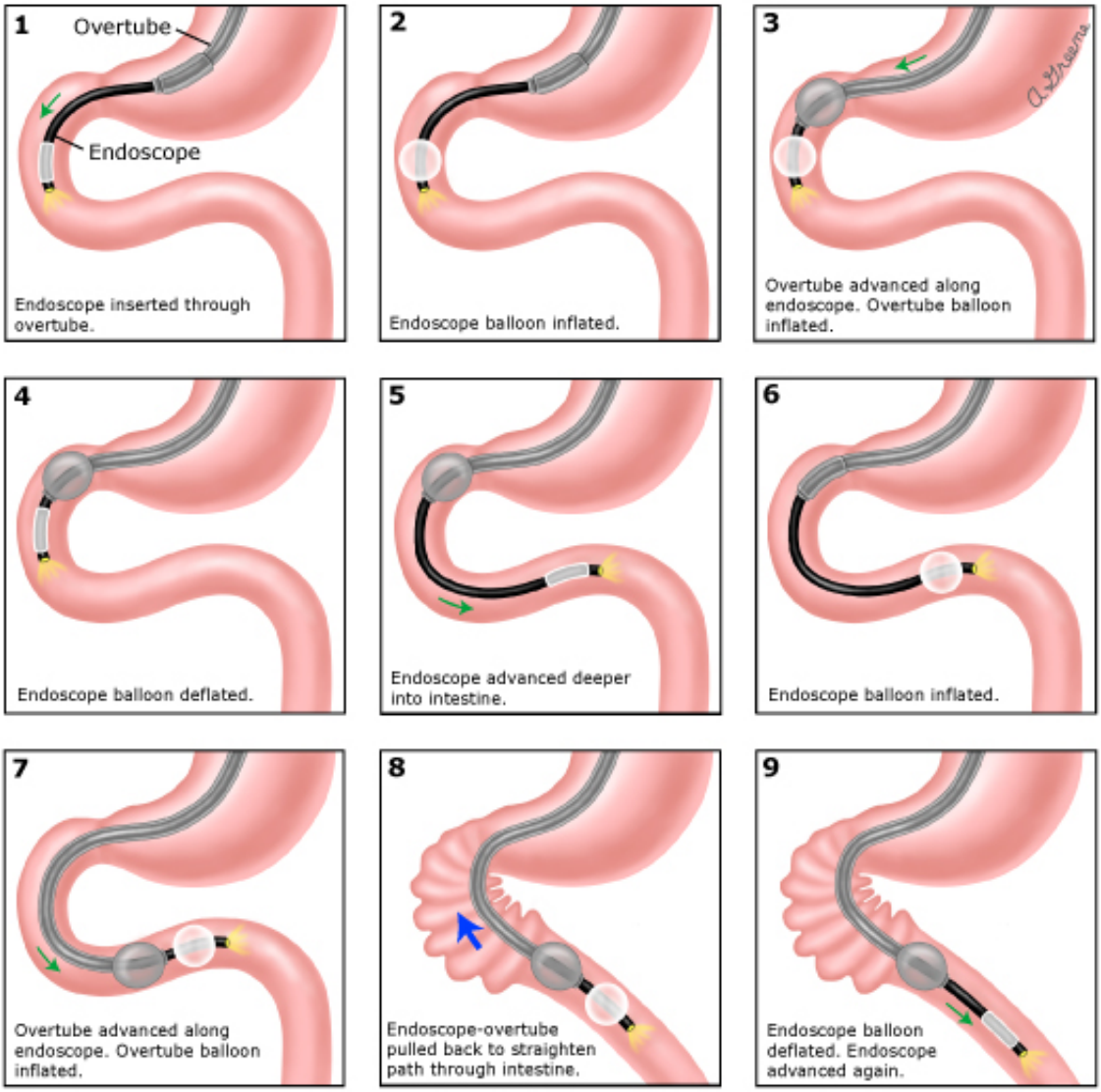

Graphic 50391 Version 2.0

Fluoroscopic view of double balloon enteroscopy

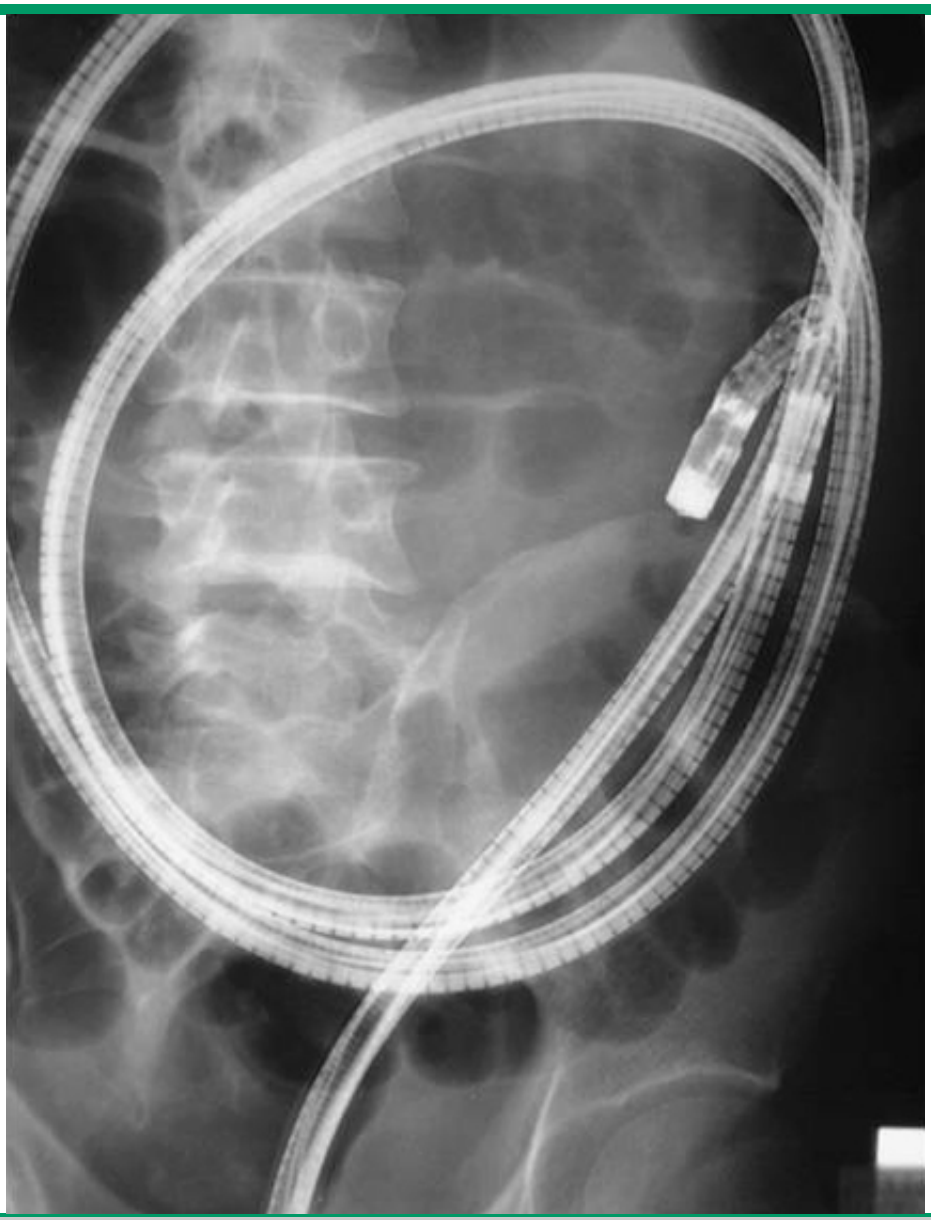

Fluoroscopic image showing the concentric circles that are formed during double balloon enteroscopy as loops are reduced.

Courtesy of Hiroto Kita, MD, PhD.

Graphic 54636 Version 2.0

Small bowel angiodysplasia

Angiodysplasia detected in the small bowel during double balloon enteroscopy.

Courtesy of Hiroto Kita, MD, PhD.

Graphic 70270 Version 2.0

Gastrointestinal stromal tumor in the small bowel

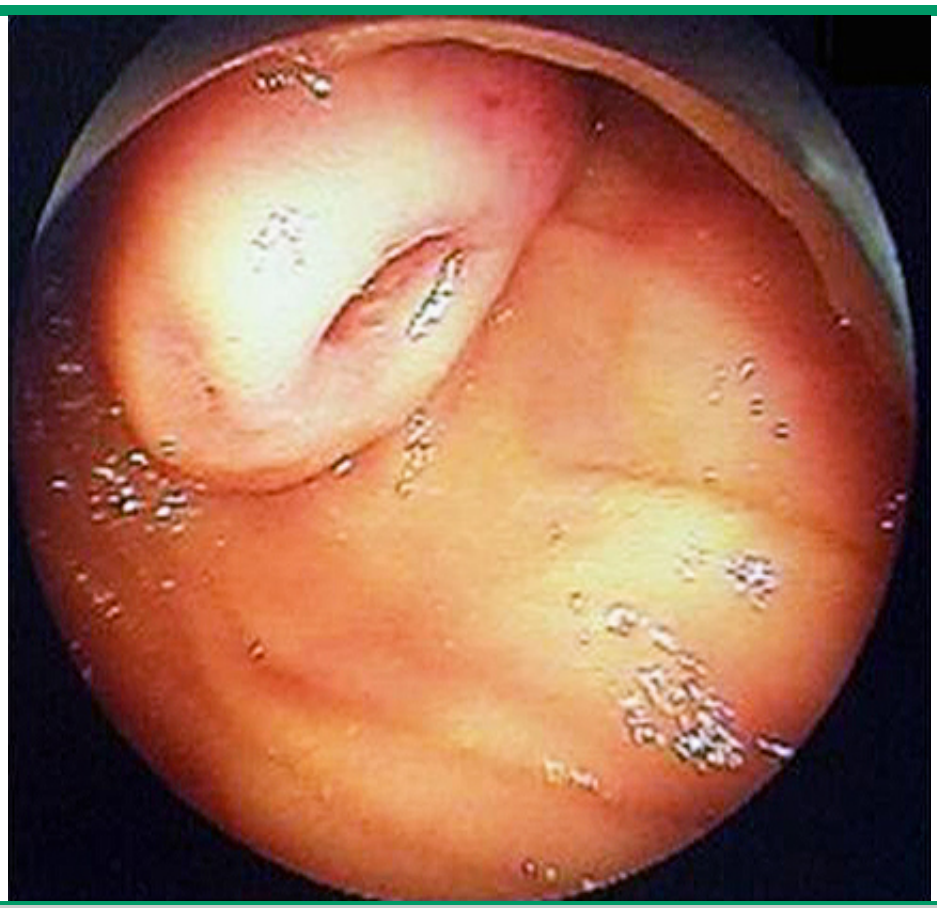

Gastrointestinal stromal tumor of the small bowel detected during double balloon enteroscopy.

Courtesy of Hiroto Kita, MD, PhD.

Graphic 78991 Version 2.0

Small bowel polyp

Small bowel polyp detected during double balloon enteroscopy.

Courtesy of Hiroto Kita, MD, PhD.

Graphic 59056 Version 1.0

Single balloon enteroscopy technique

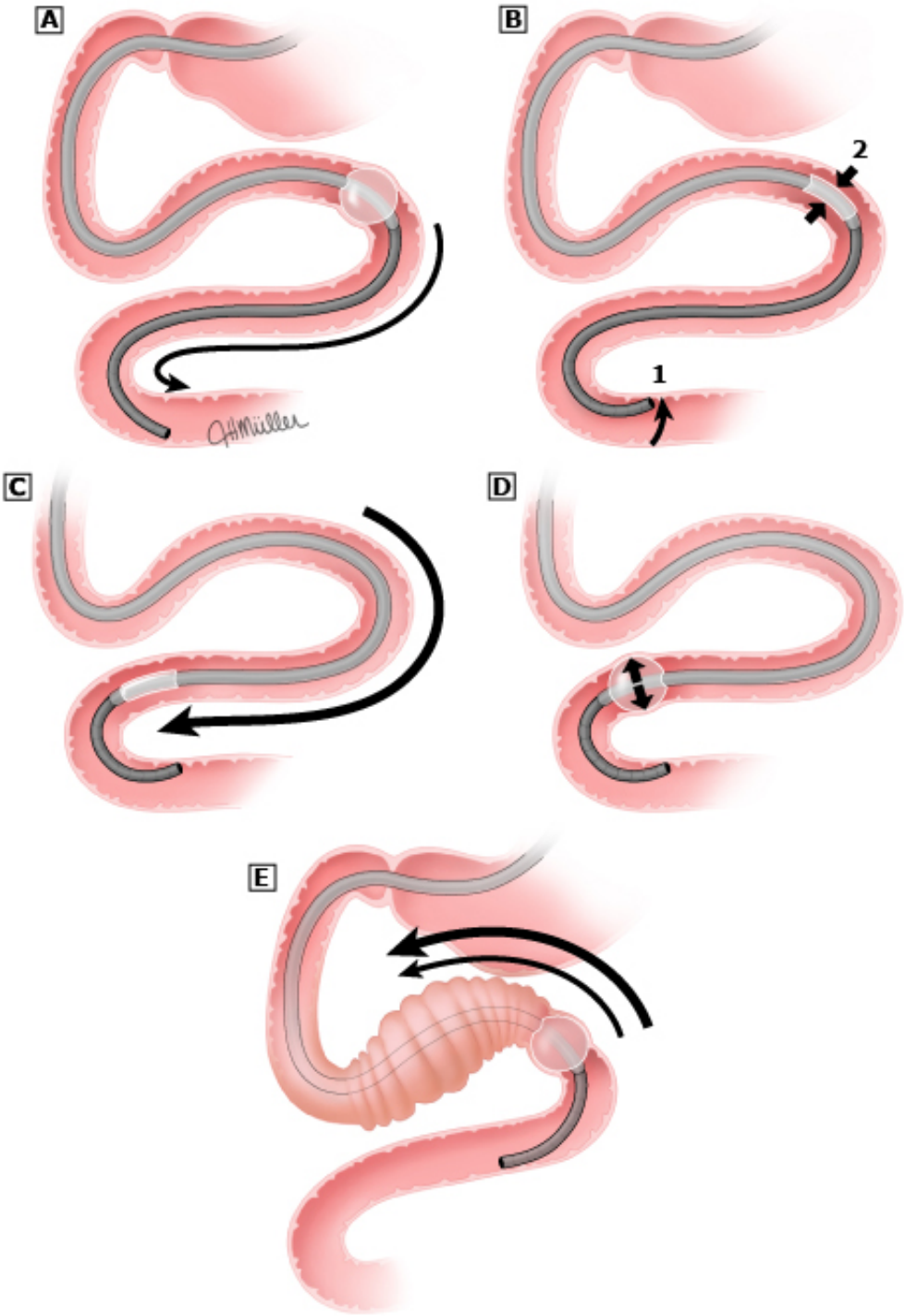

(A) With the balloon at the tip of the overtube inflated to anchor the small bowel, the enteroscope is advanced as deeply into the small bowel as possible (except for the initial insertion, when the enteroscope is advanced with the overtube balloon deflated).

(B) Once forward motion is no longer possible, the tip of the enteroscope is agulated to create a "hook" that will help anchor the enteroscope. Once the small bowel is anchored by the tip of the enteroscope, the overtube balloon is deflated.
(C) The overtube is advanced to the end of the enteroscope.
(D) The overtube balloon is inflated to anchor the small bowel.
(E) Both the enteroscope and the overtube are gently withdrawn to pleat the small bowel onto the overtube. The enteroscope is then advanced as in (A), and the process is repeated until forward progress with the enteroscope is no longer possible or the area of interest within the small bowel is reached.

Graphic 63179 Version 1.0

Spiral enteroscopy overtube

Endo-Ease Discovery SB® overtube for small bowel enteroscopy.

Graphic 76104 Version 2.0

Disclosures

Disclosures: **Hiroto Kita, MD, PhD** Nothing to disclose. **Douglas A Howell, MD, FASGE, FACG** Grant/Research/Clinical Trial Support: Cook Endoscopy [Endoscopic Scopes/Imaging (Endoscopic wires, stents)]; Olympus America [Endoscopic devices]; Boston Scientific [Endoscopic stents, wires, introducers]; Advanced Endoscopic Devices [Scopes, Magnetic imaging, endoscopic clips]. Speaker's Bureau: Olympus America [Endoscopic Scopes/Imaging (Scopes, Magnetic imaging)]. Patent Holder: Cook Endoscopy [Stent introducer system]; Advanced Endoscopic Devices [wire guide access]. **Anne C Travis, MD, MSc, FACG, AGAF** Employee of UpToDate, Inc. Equity Ownership/Stock Options: Proctor & Gamble.

Contributor disclosures are reviewed for conflicts of interest by the editorial group. When found, these are addressed by vetting through a multi-level review process, and through requirements for references to be provided to support the content. Appropriately referenced content is required of all authors and must conform to UpToDate standards of evidence.

Conflict of interest policy