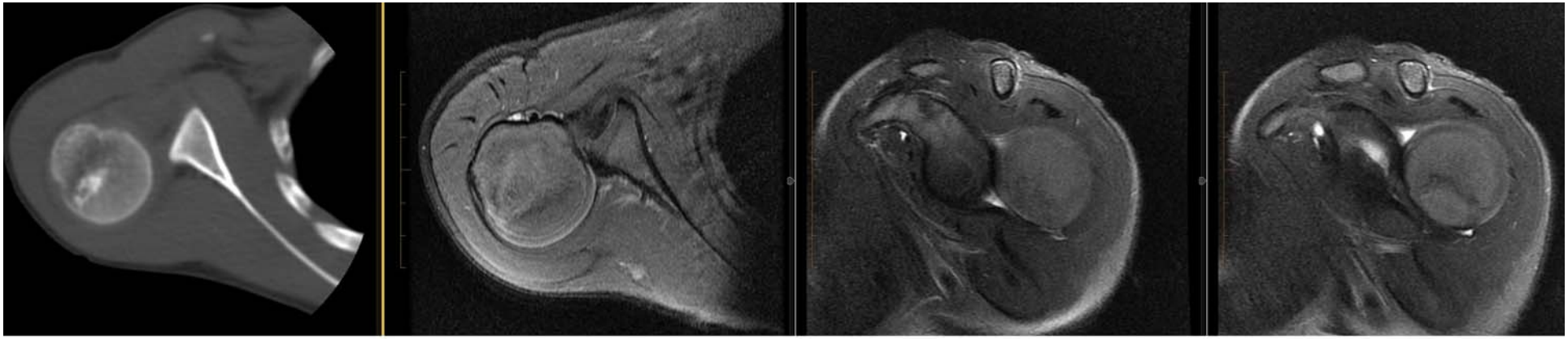

Posterior Shoulder Instability
Open Management

Armodios Hatzidakis MD OLC 2009

WESTERN ORTHOPAEDICS
1830 FRANKLIN STREET, SUITE 450
DENVER, COLORADO 80218

Ambiguity of Terminology

- Dislocation vs subluxation
- Traumatic vs atraumatic
- Habitual vs voluntary vs involuntary

FUCHS B. et.al. J Bone Joint Surg 2000:82:16-25

Basic Questions

- Is the shoulder unstable? Directions?
- Is the labrum torn?
- Is the capsule stretched? Gone?
- Is the bony fulcrum adequate
  - Glenoid
  - Humerus: “Locked” dislocation?
- Does the patient have mental reasons to fail?
- Previous surgery?

FUCHS B. et.al. J Bone Joint Surg 2000:82:16-25

Determination of Instability

- History
- Clinical examination
  - Supine load and shift with comparison to opposite side
  - ABER apprehension/Relocation tests
  - Posterior jerk test
- Arthroscopic Evaluation

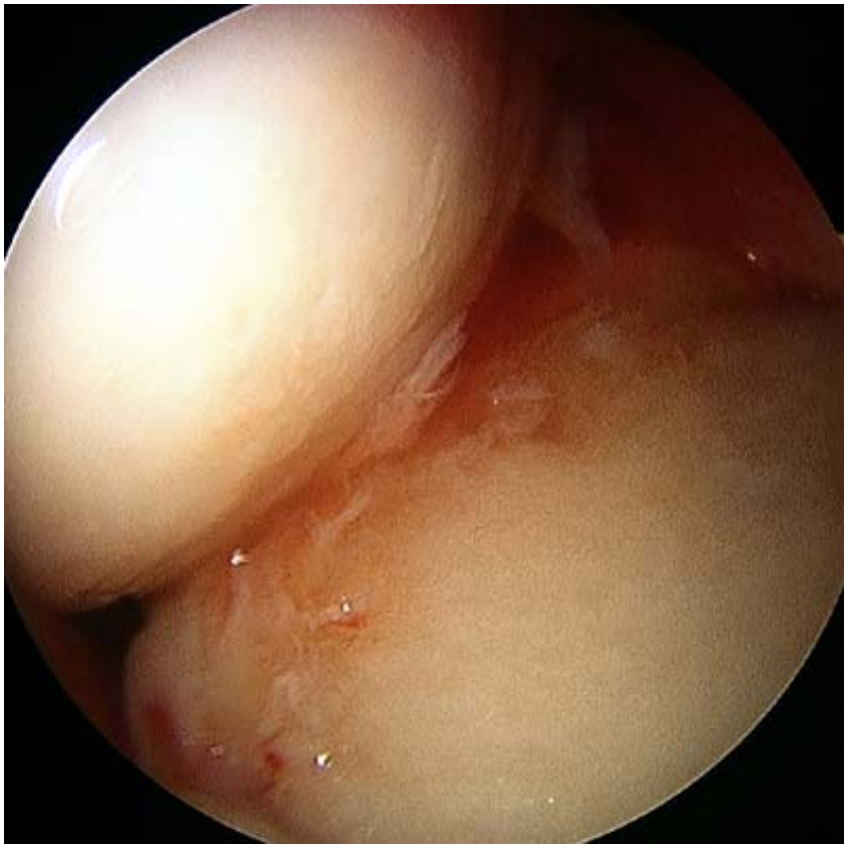

Labrum/Capsule

- History & exam:
  - Thermal Capsulorrhaphy
  - Hyperlaxity
- MRI/Arthrogram
  - Labrum
  - Posterioinferior pouch
- Arthroscopy

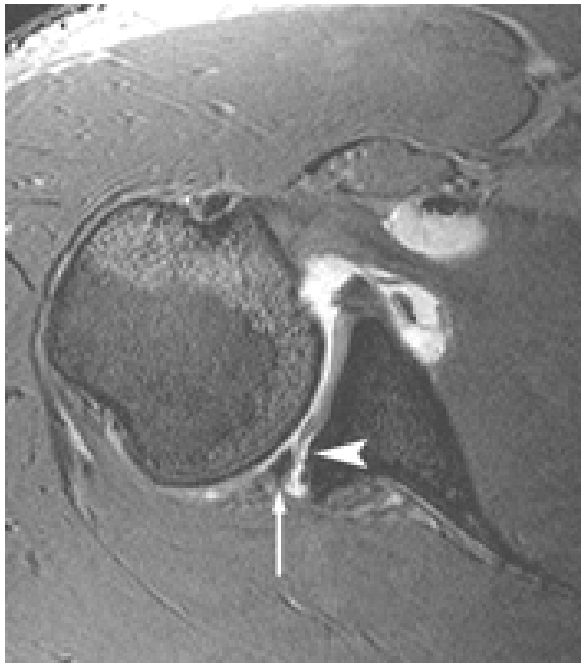

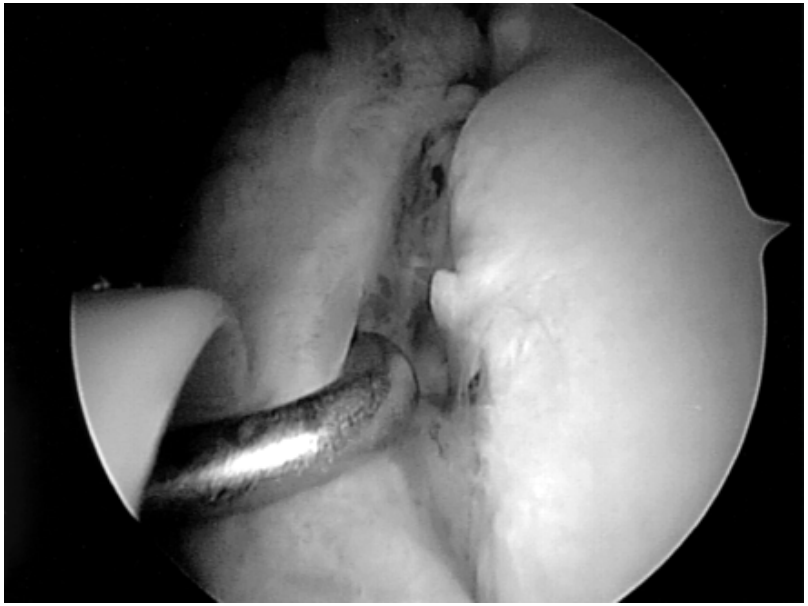

Millett et al, JAAOS 2006

Osseous Evaluation

- MRI suboptimal
- CT scan best. 2D and 3D recons of glenoid face
  - Bone loss: Glenoid or humerus
  - Posterior rim sloping/Fx
  - Excess retroversion/dysplasia

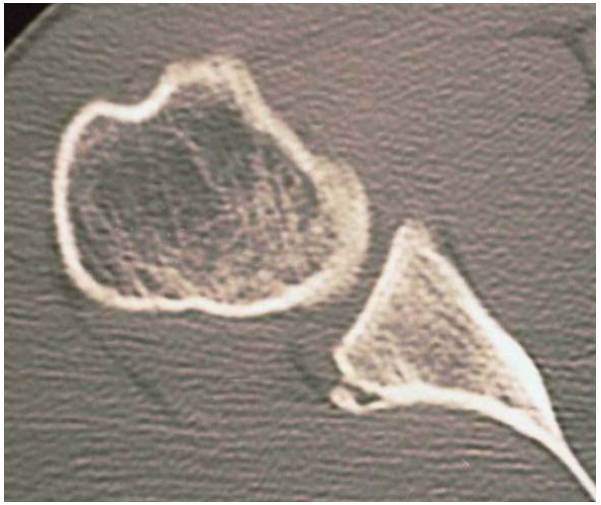

Psychological Factors

- Workman's Compensation claim
- Psychiatric/emotional disorder
  - Habitual (psychiatric, willful)
  - Voluntary (intentional but not willful)
  - Involuntary/unintentional
    - Hawkins et al, JBJS 1984
- We are <u>not</u> psychiatrists

Etiology and Treatment

- Detached labrum
  - Arthroscopic repair
- Capsular tissue stretched
  - Arthroscopic or open repair/casulorrhaphy
- Inadequate bony fulcrum
  - McGlaughlin Procedure
  - Open Glenoid Augmentation
- Inadequate capsular tissue
  - Open capsular reconstruction, Graft Reinforcement

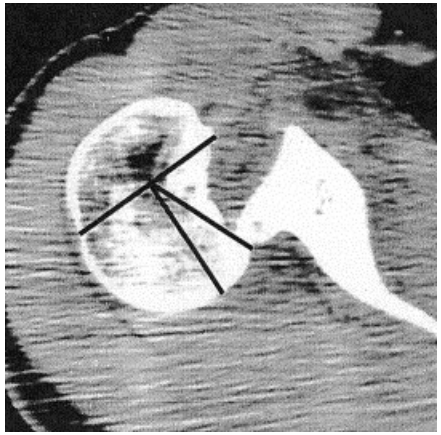

Open Capsullorhaphy: Exposure

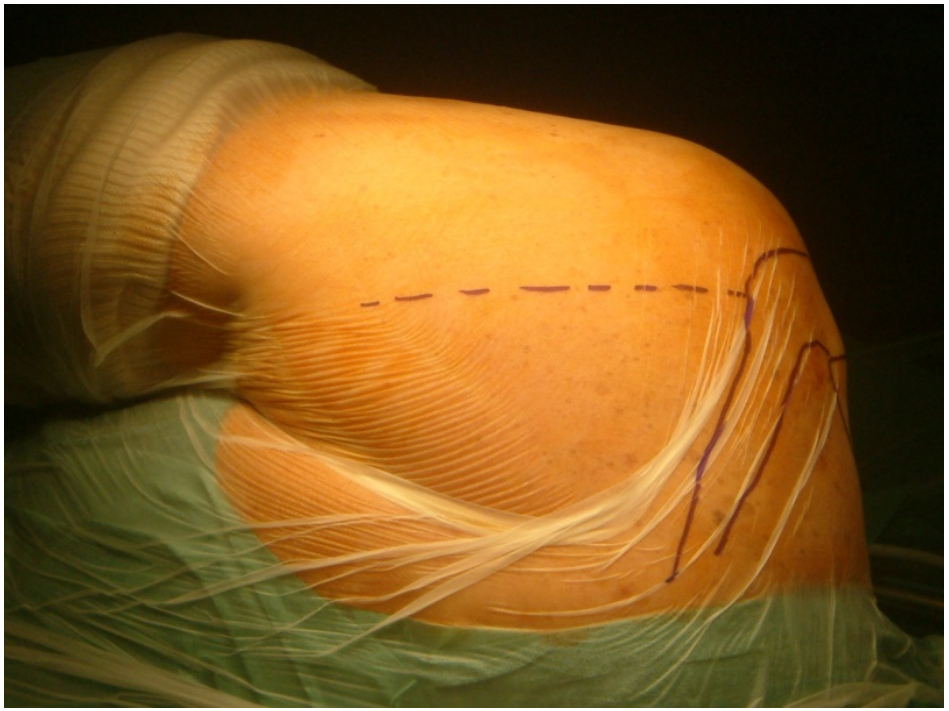

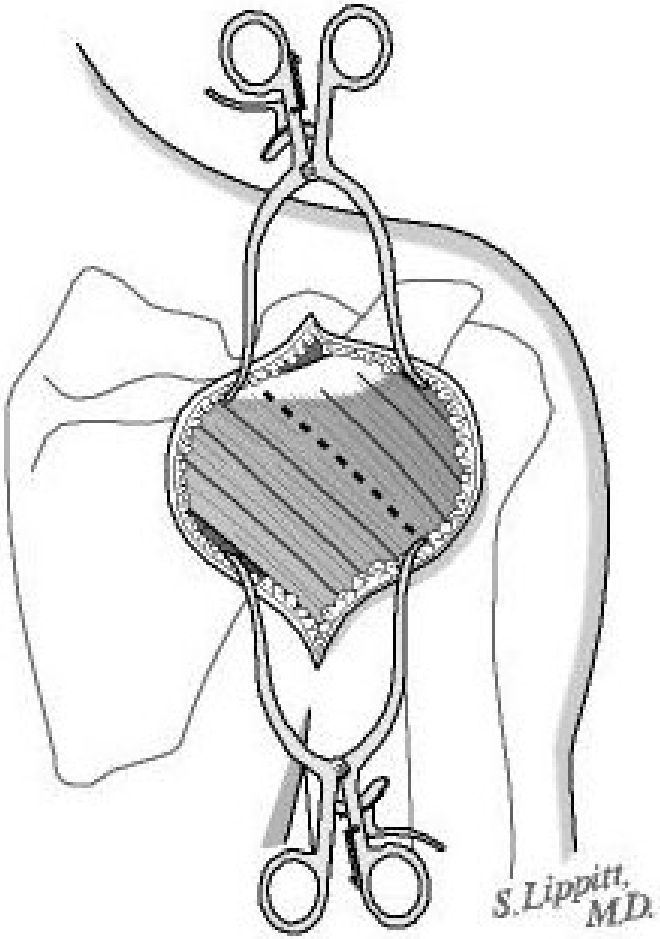

Matsen: www.orthop.washington.edu

Exposure

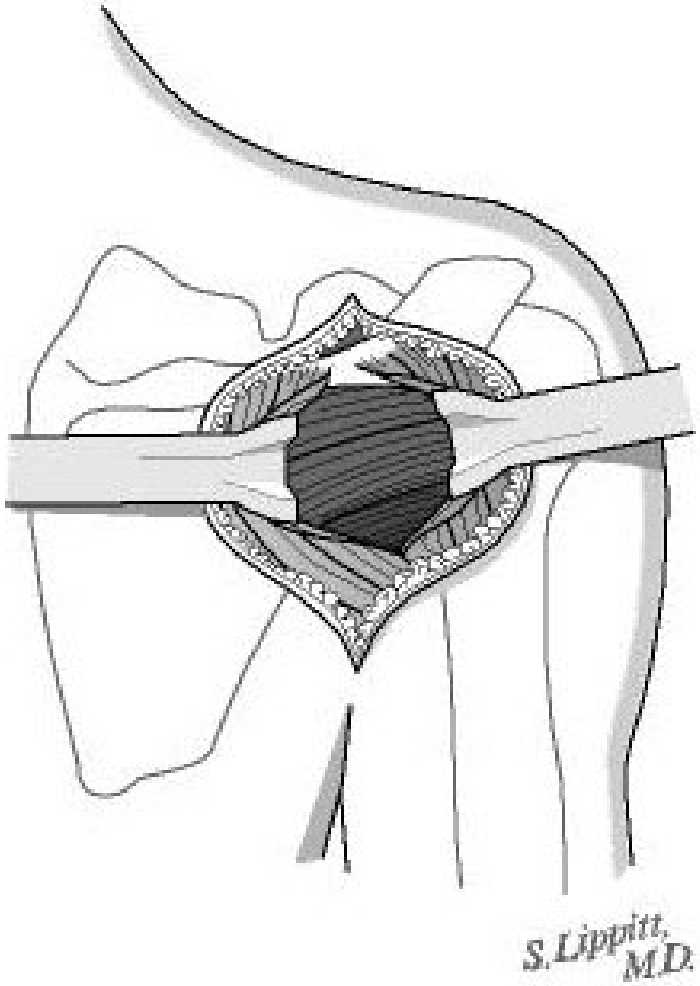

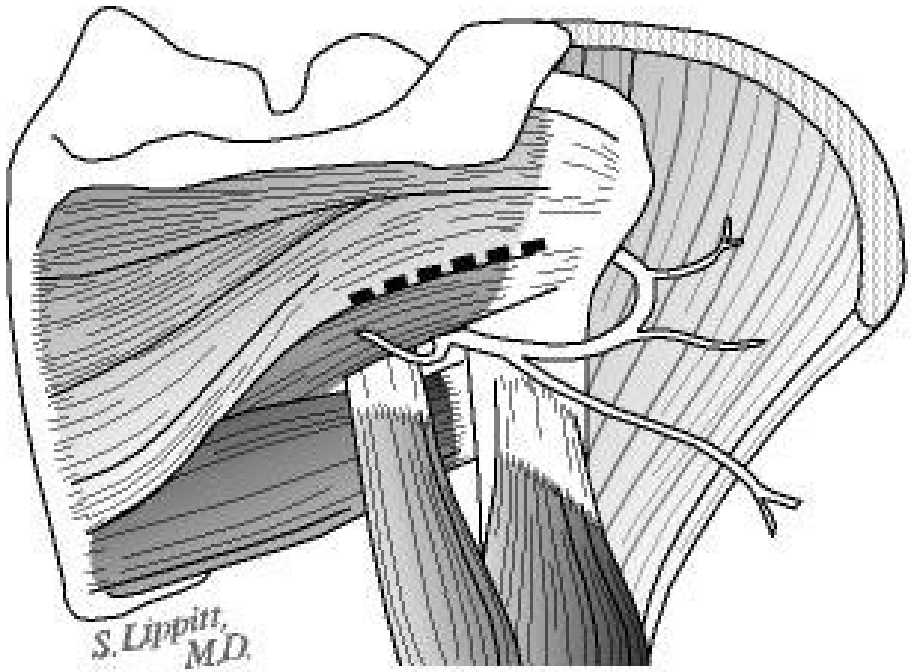

Matsen: www.orthop.washington.edu

With Infraspinatus Release

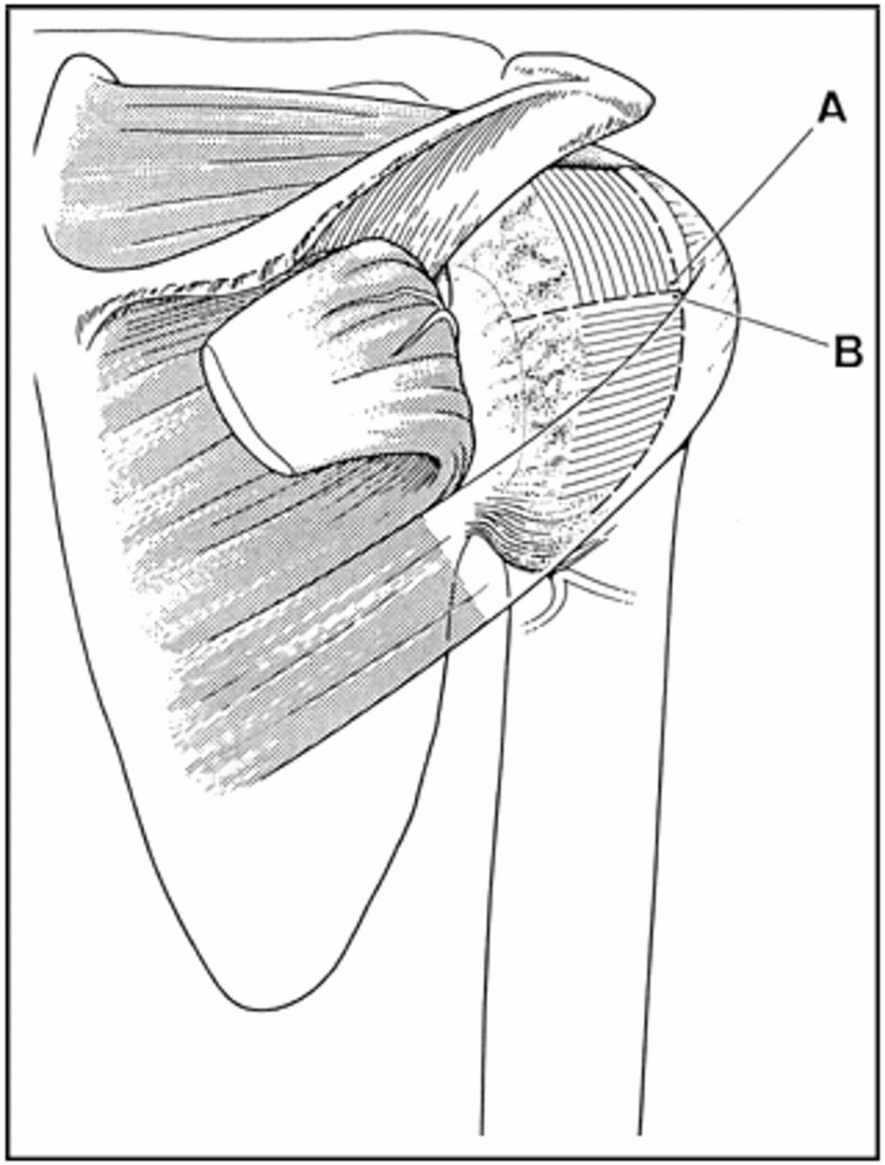

FUCHS B. et.al. J Bone Joint Surg 2000:82:16-25

J B&J S

Neer Humeral Sided Capsular Shift

Courtesy of Gilles Walch

Posterior Glenoid Deficiency

- Dysplasia
  - Osteotomy

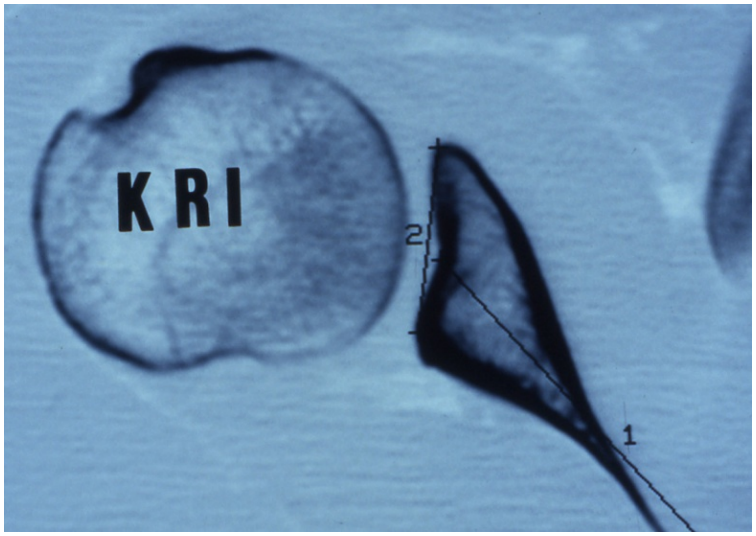

- Posterior Glenoid Rim Loss
  - Augmentation ("Bone Block")

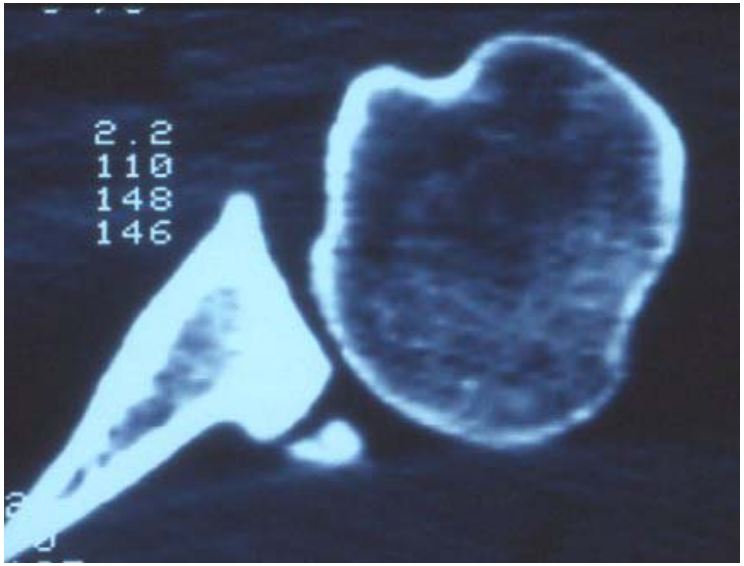

Glenoid Dysplasia: Osteotomy

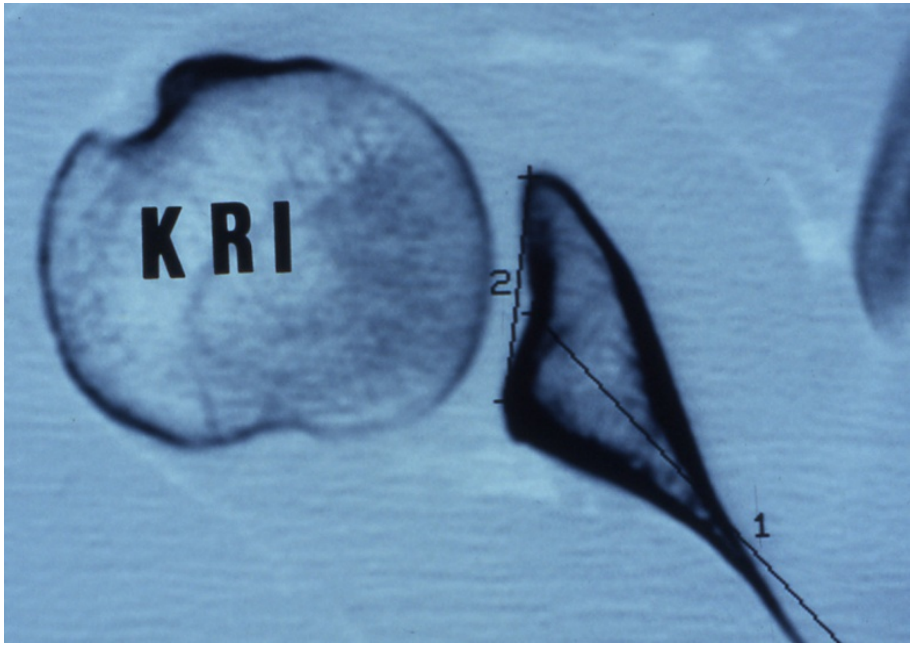

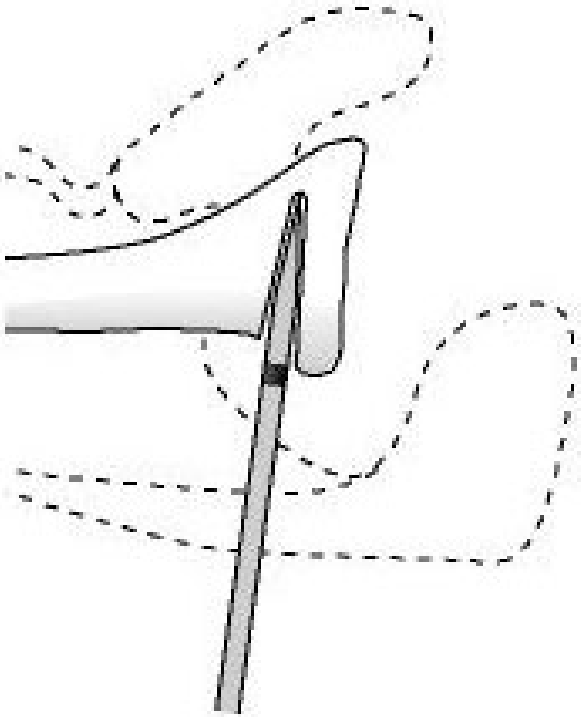

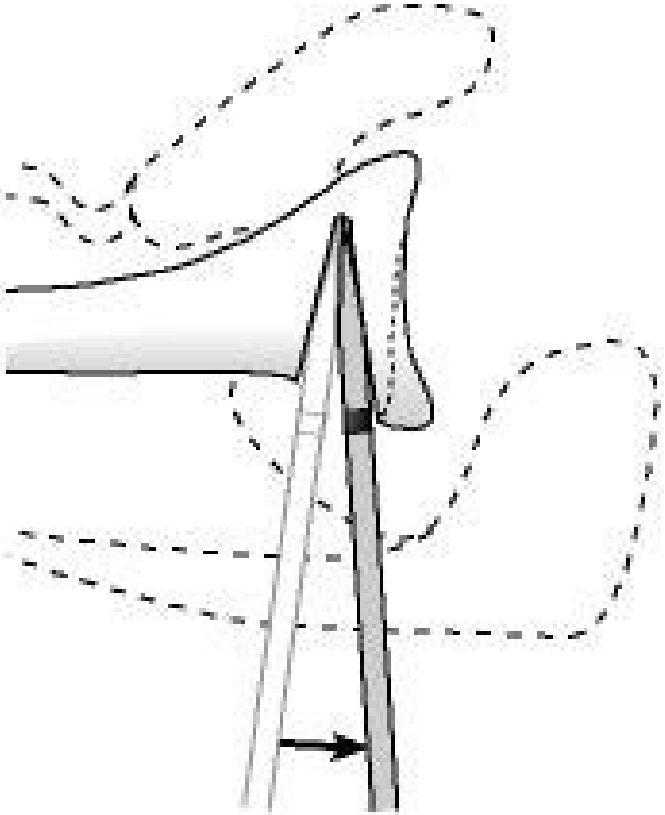

Matsen: www.orthop.washington.edu

Glenoid Osteotomy

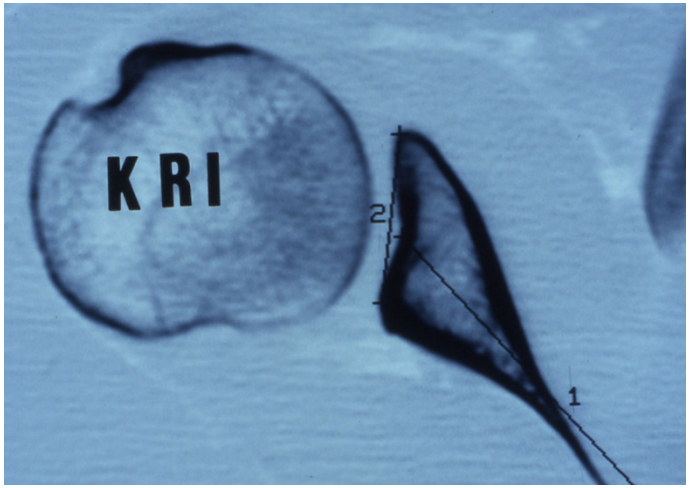

Matsen: www.orthop.washington.edu

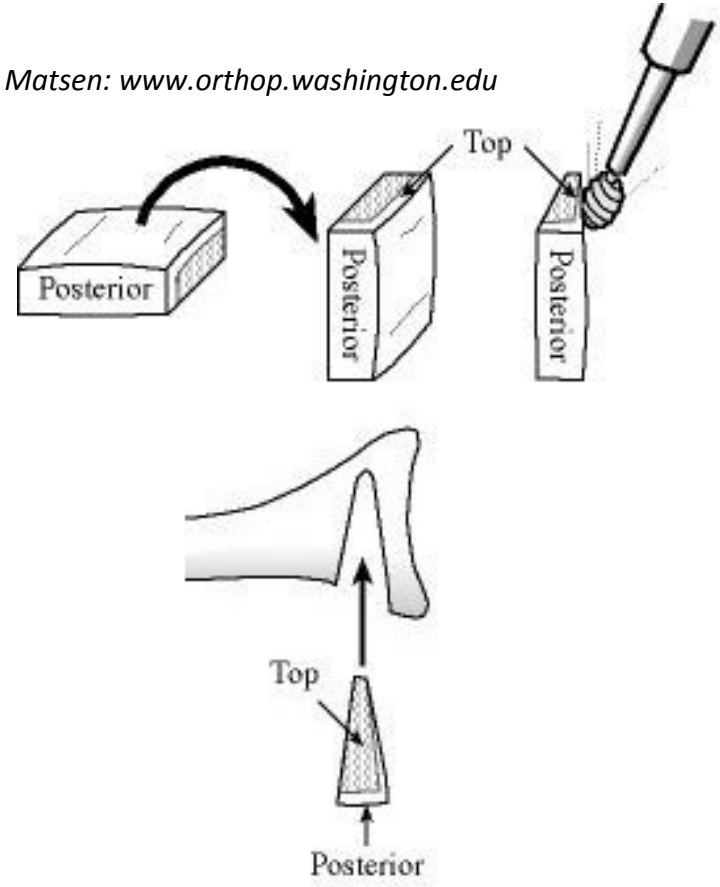

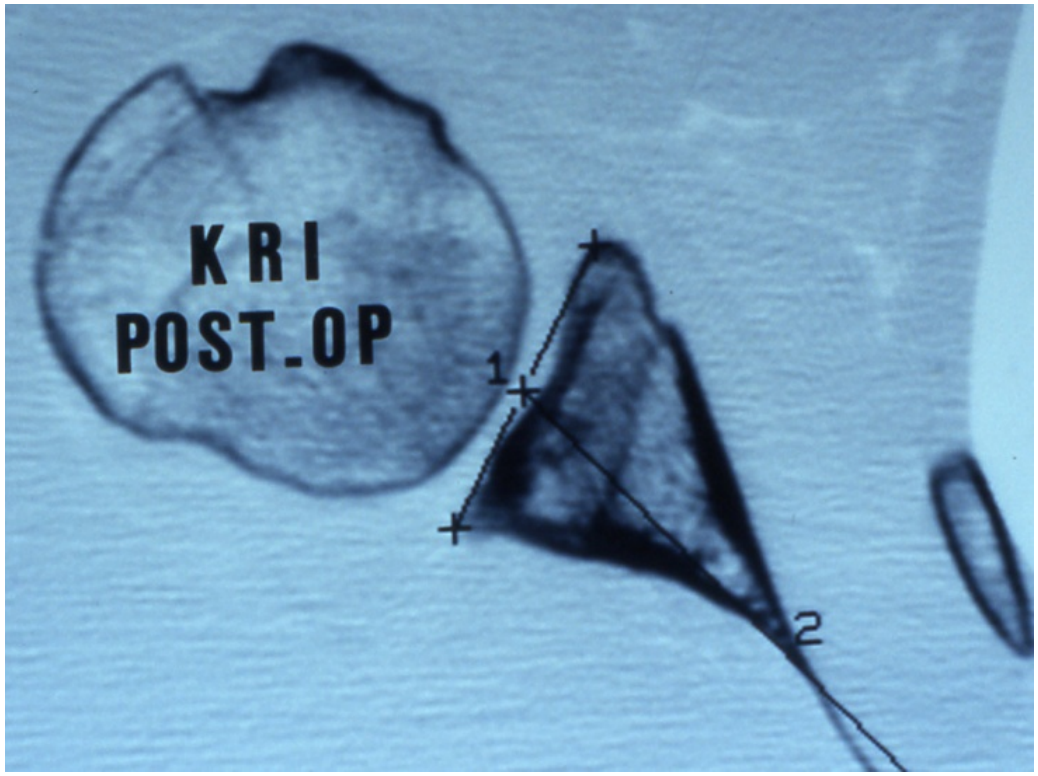

Case Courtesy of Gilles Walch

Patient Selection/Complications

- Severe hypoplasia
- Perforation of Glenoid
  - Johnston et al CORR 1984
- Osteoarthritis

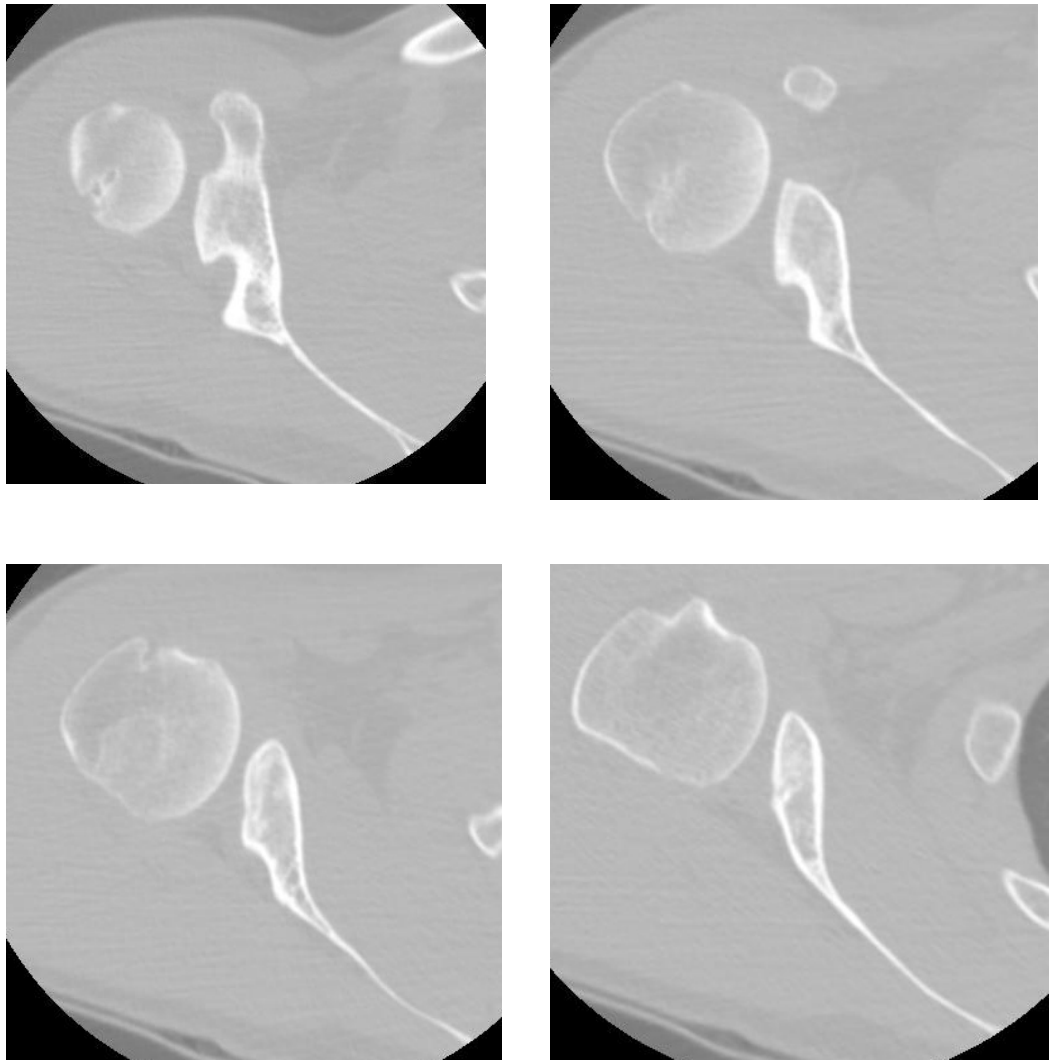

Complication: Osteoarthritis

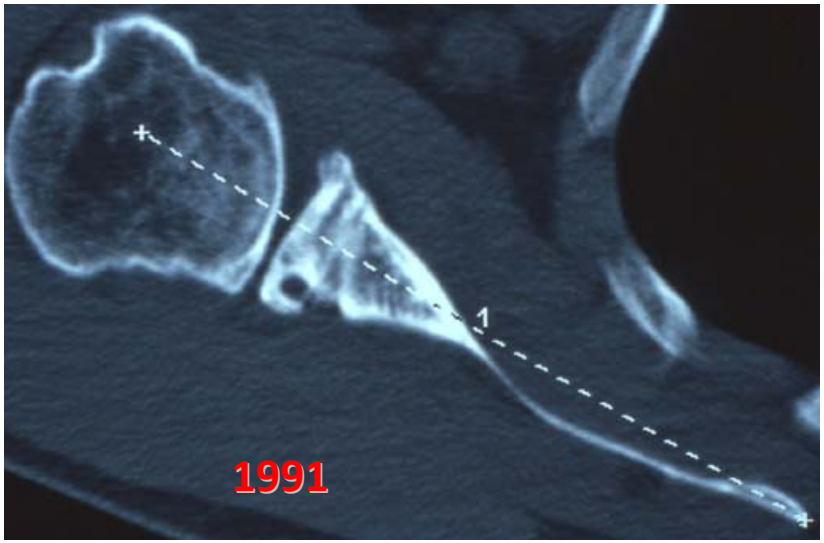

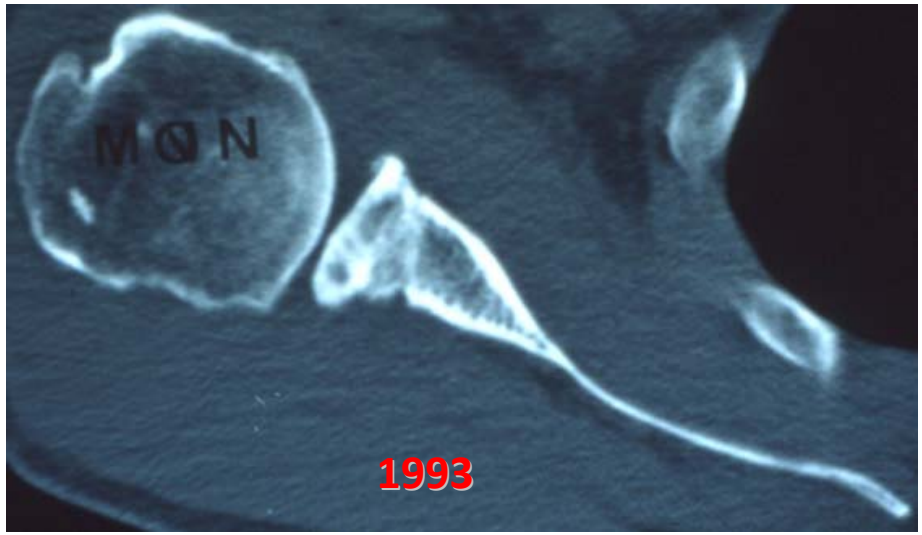

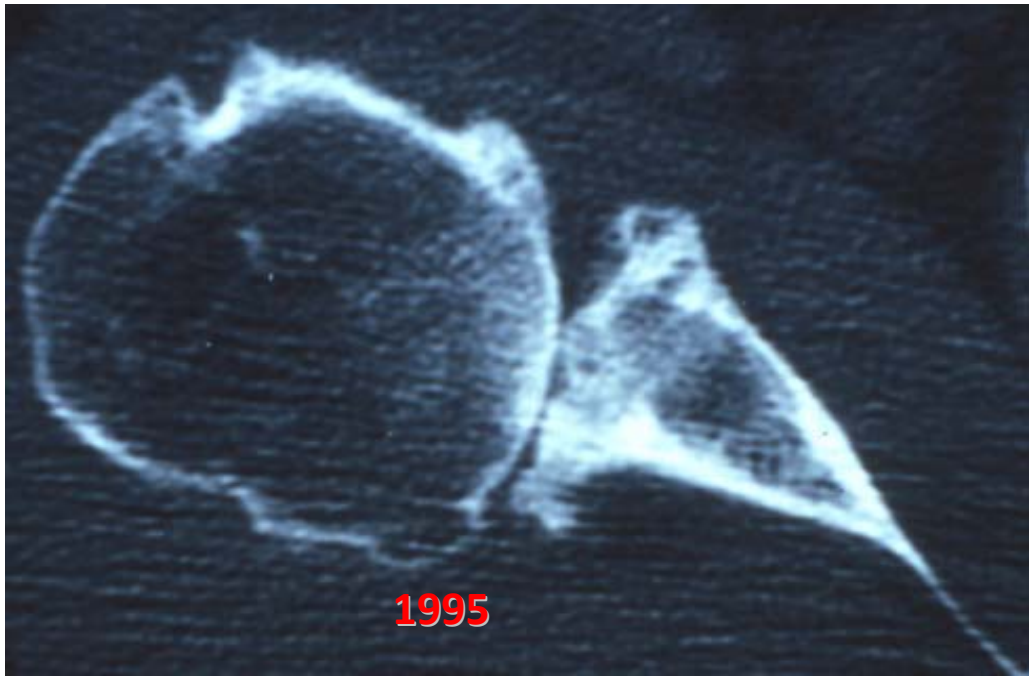

Case Courtesy of Gilles Walch

Posterior Glenoid Rim Loss

- Open Posterior Glenoid Augmentation with Bone Graft

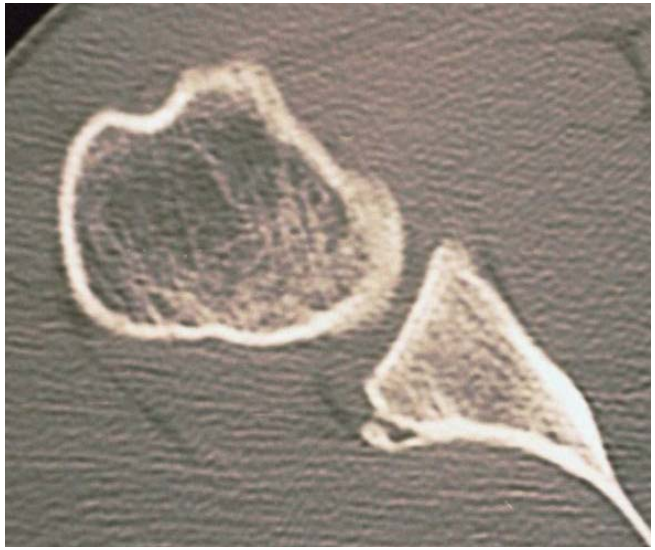

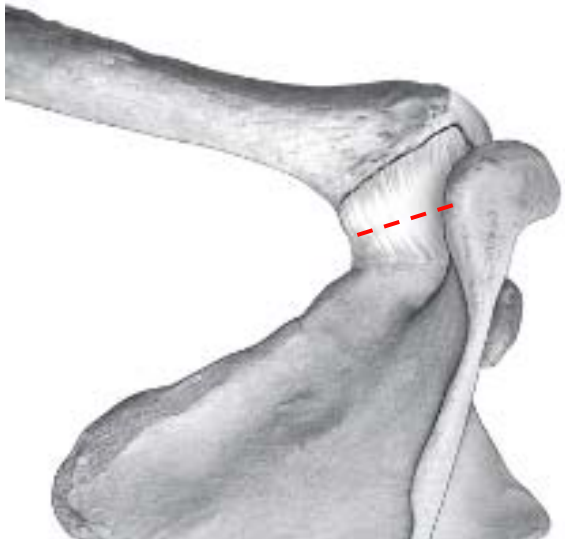

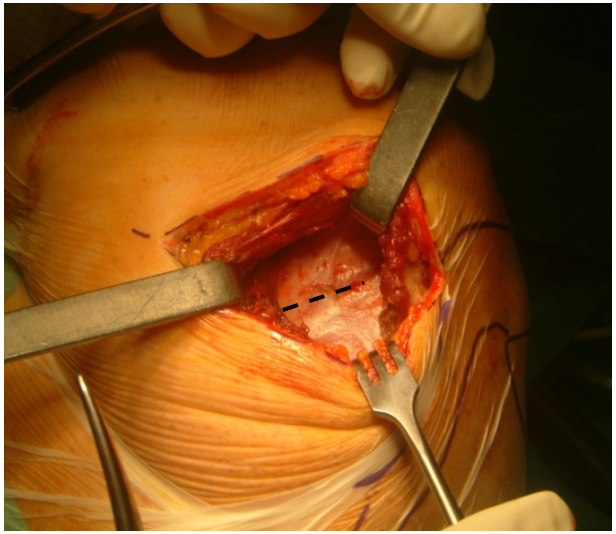

Courtesy of Gilles Walch

Vertical Glenoid Sided Capsuloplasty

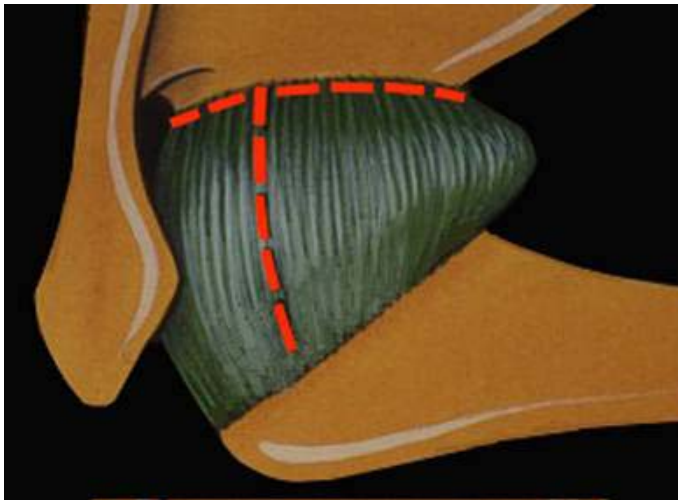

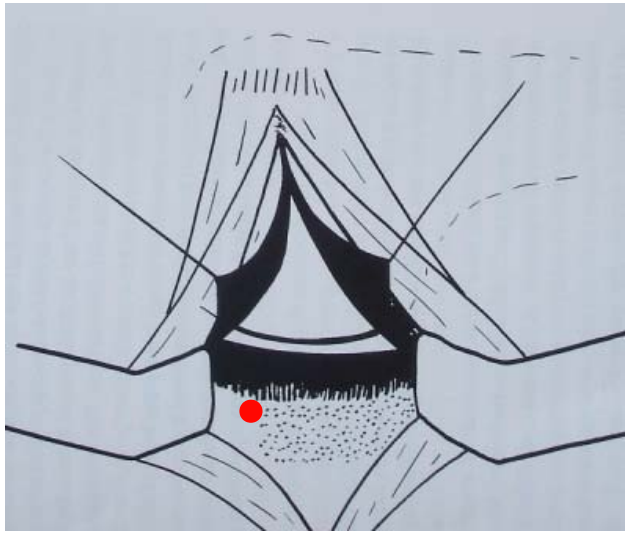

. Post glenoid abraded

. Drill inferior hole (3.2 mm)

T-Shift of Capsule

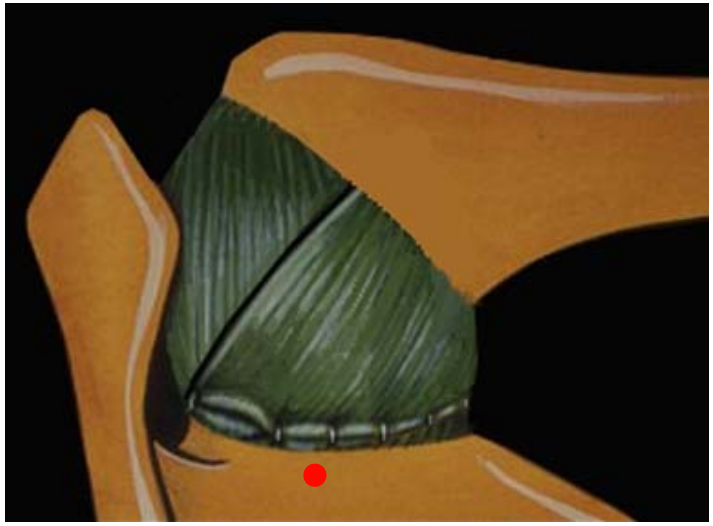

Courtesy of Gilles Walch

Iliac crest (Inner Table Graft

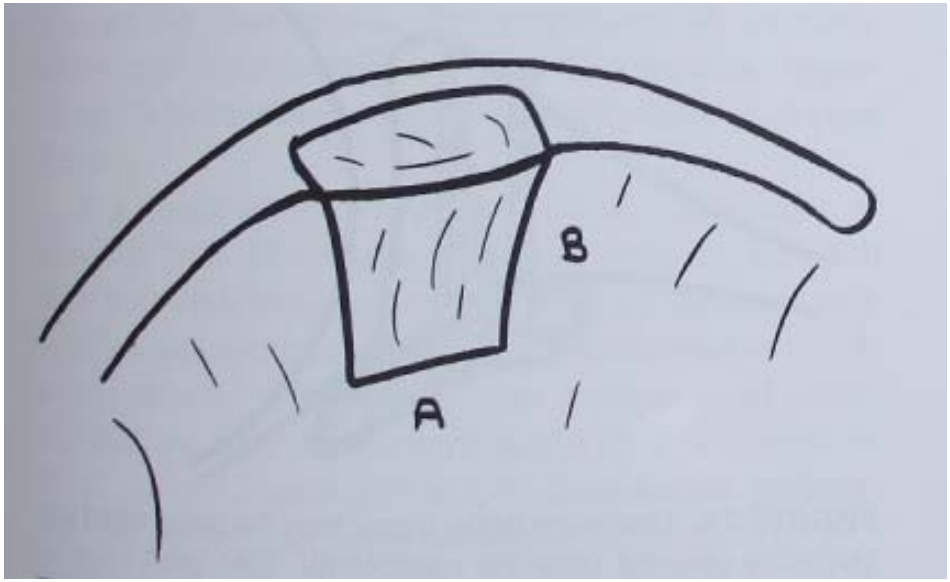

2-3 cm Deep

3-4 cm Long

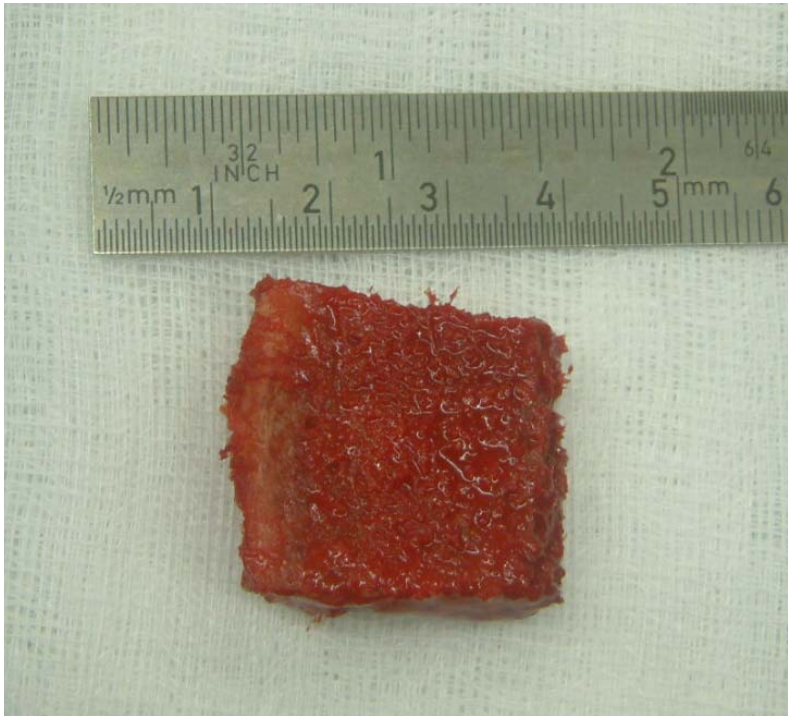

Courtesy of Gilles Walch

Extra-Articular Fixation of Graft

- 2 Malleolar Screws (Large Frag)
- Slight Overhang

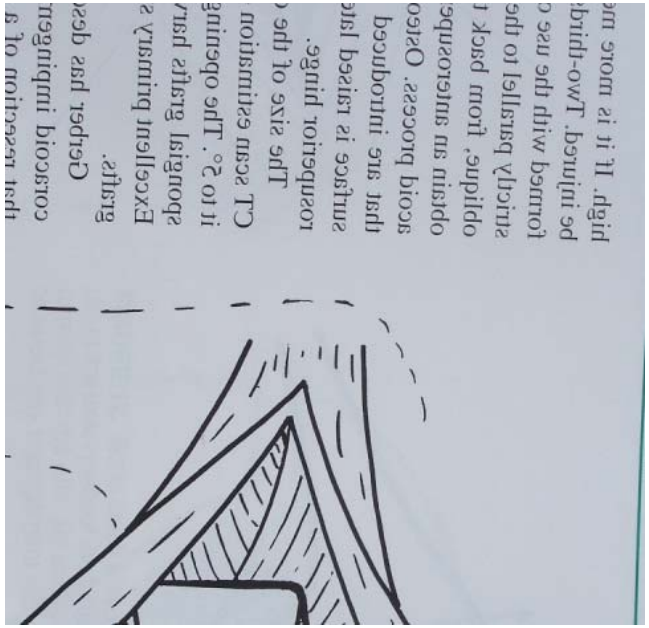

Courtesy of Gilles Walch

Graft Position

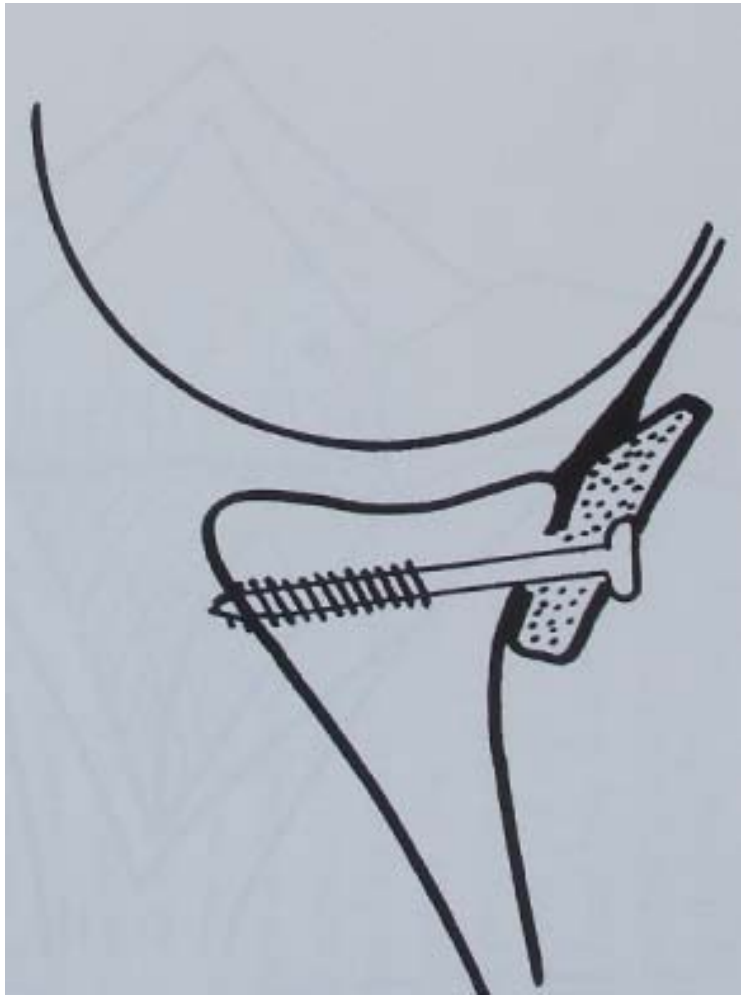

Courtesy of Gilles Walch

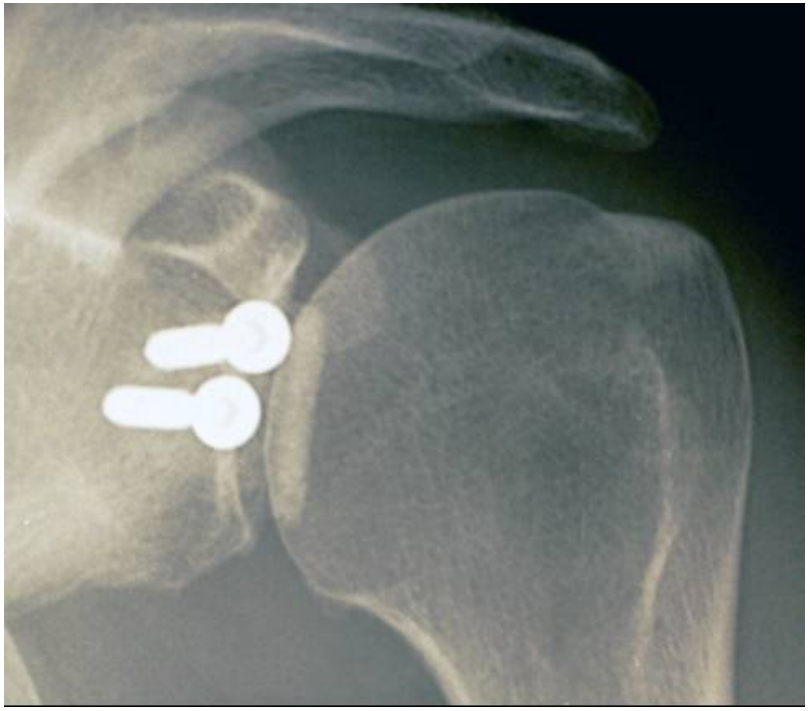

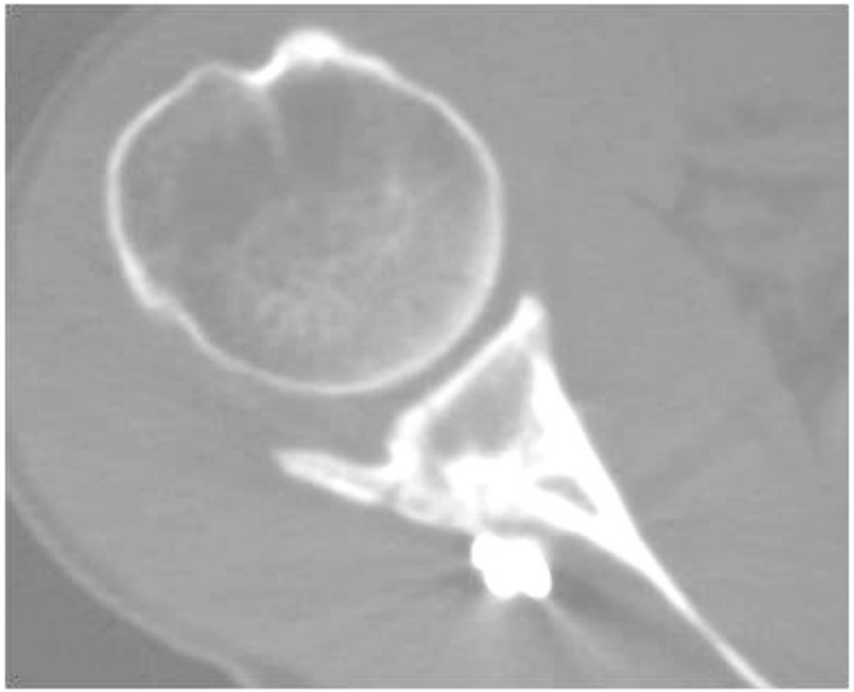

Post operative course

Neutral rotation

4 to 6 weeks

Passive ROM

No IR for 6 weeks

Return to sports after 4 months

Results (Gilles Walch)

21 shoulders

FU 6 y (2-19)

20 VS or S (95%)

Failures : 3 (14%)
- **I recurrence**
- **2 apprehension +++**

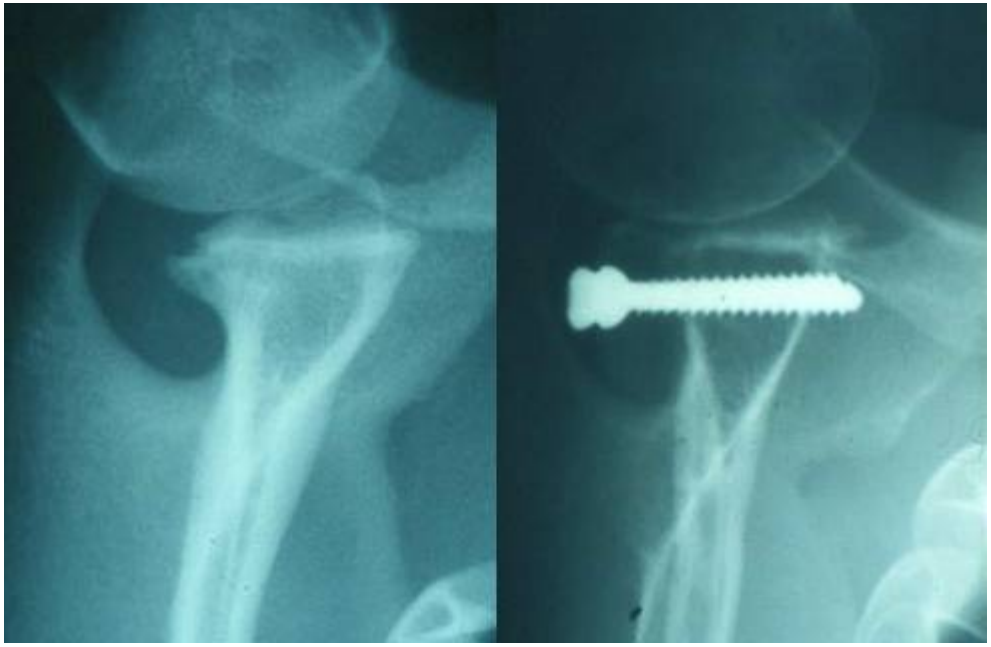

Walch et al, Knee Surg Sports Traumatol Arthrosc 2007

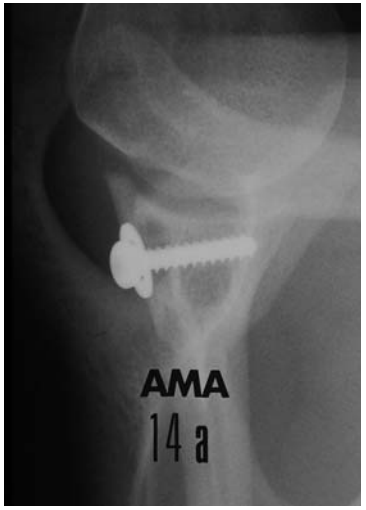

RESULTS

Mean Constant score : 93.3 (80-100)

	Constant Score
Pain	**13 (8-15)**
ADL	**19.3 (17-20)**
Mobility	**39.5 (37-40)**
Strength Kg x 2	**22 (14-28)**

(55% no pain)

(80% symmetric ER)

Courtesy of Gilles Walch

XR Results

4 Arthritis

2 preop

2 postop

Courtesy of Gilles Walch

Post. Capsulorraphy

	n	FU	Rec sub/dis	Failure rate
Provencher (Ascop) (2005-Am J Sports Med)	33	3 y	7	21%
Wolf BR (Open) (2005-JSES)	37	8 y	8	19%
Kim (Ascop) (2003 - JBJS Am)	27	3 y	1	4%
Williams (Ascop) (2003-AJSM)	27	5 y	3	11%

Additional Open Procedures

- Posterior Stabilization via an anterior approach
- Posterior “Addition Acromioplasty”
- Cadaver Graft/Capsular Reinforcement

Post Stabilization via Anterior Approach

- Introduced by Neer ("cruciate closure") for MDI patients with significant posterior instab

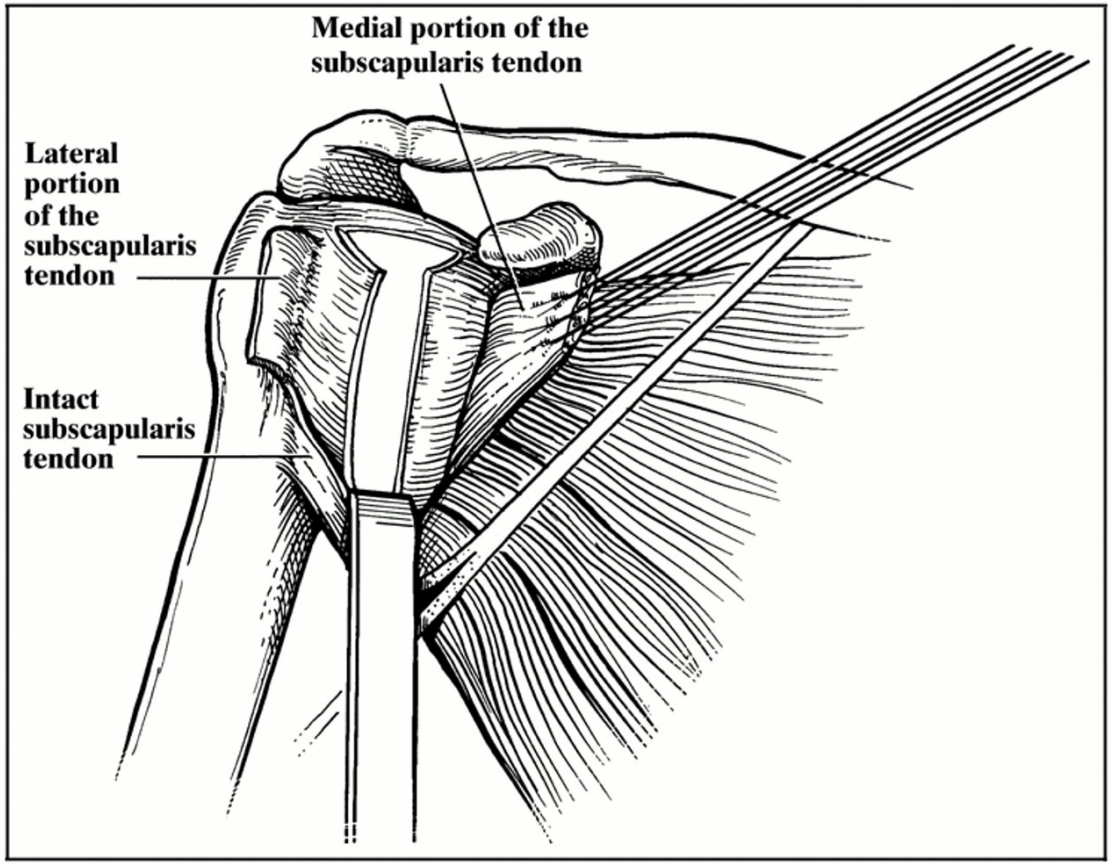

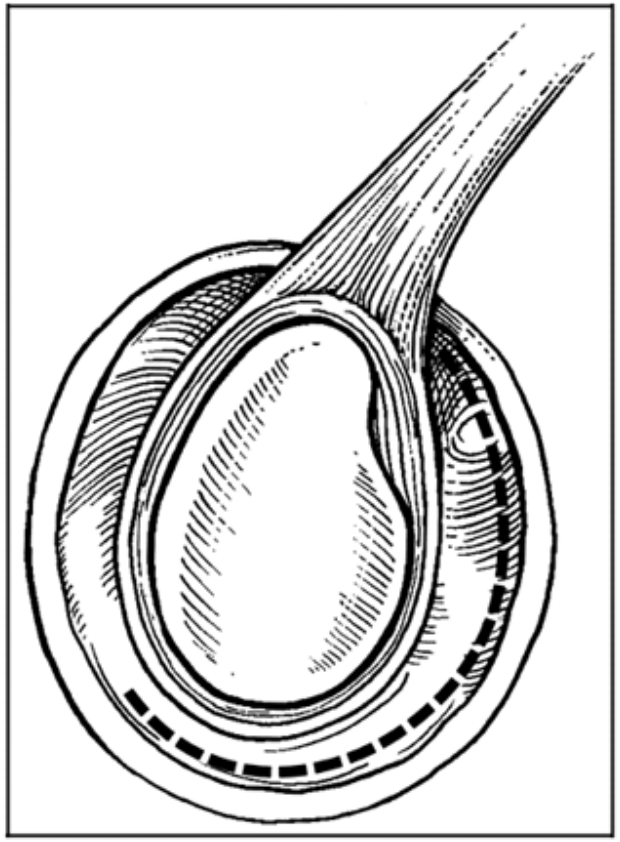

WIRTH M. A. et.al. J Bone Joint Surg 1998:80:1570-8

J B&J S

Posterior Addition Acromioplasty

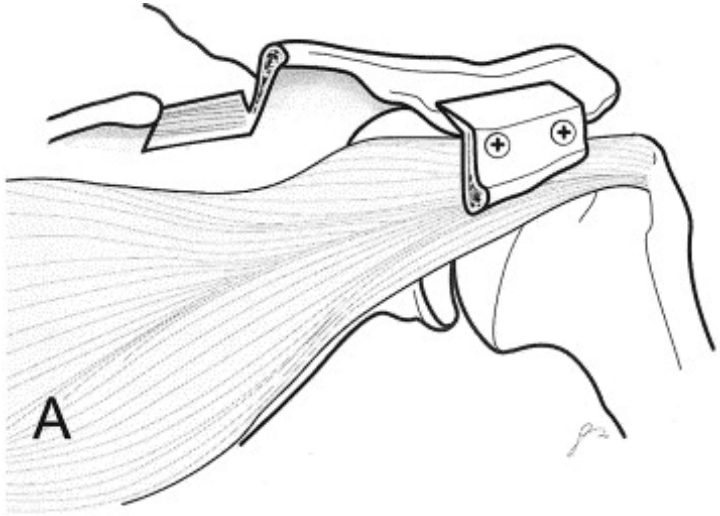

Scapinelli JSES 2006

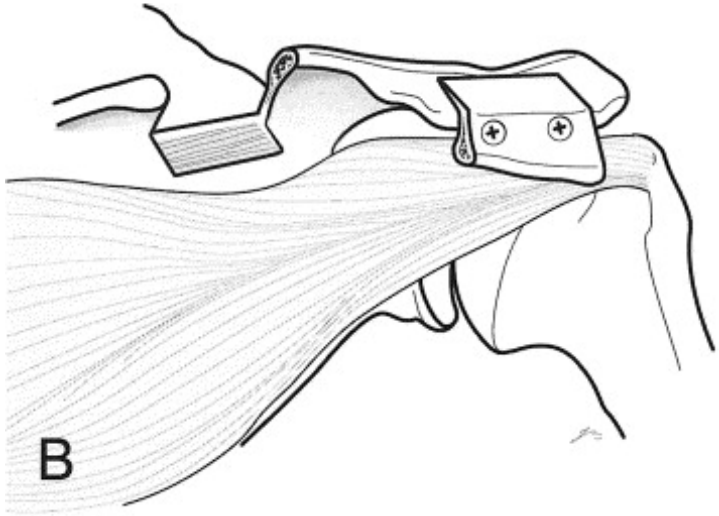

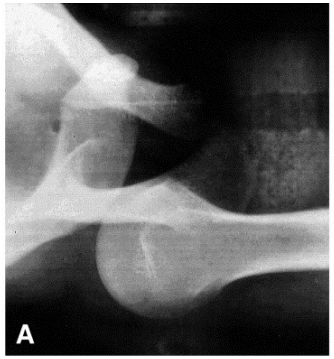

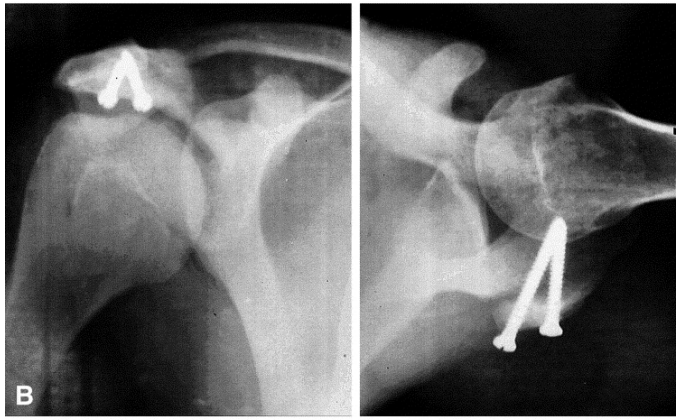

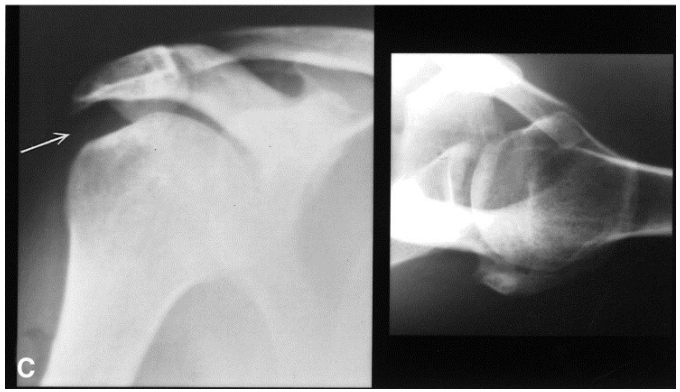

Graft Reinforcement

- Possible improvement of results in cases of thinned/insufficient capsular tissues

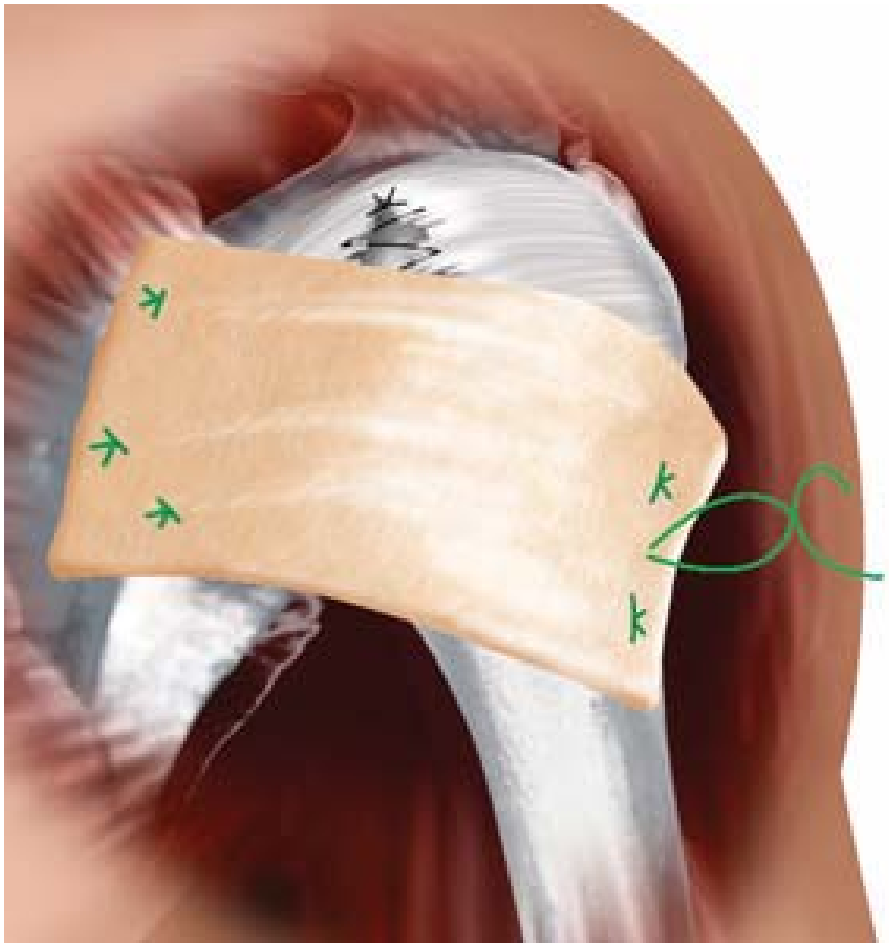

Open Posterior Capsular Reconstruction

- Acceptable treatment option. Higher morbidity but effective alternative to arthroscopic stabilization if performed properly
- Can be performed from the front in cases of MDI
- Treatment of choice in cases of bony and capsular deficiency

Thanks