

Transient Buccal Nerve Paresis

ALI HENDI, MD*

Ali Hendi, MD, has indicated no significant interest with commercial supporters.

Infiltration of a local anesthetic agent (e.g., lidocaine) in the vicinity of the facial nerve can transiently paralyze the temporal branch of the facial nerve and cause ipsilateral brow ptosis. This typically occurs during surgery to remove skin cancers on the temple. The buccal nerve typically is not prone to transient or permanent damage because it lies deep to the buccal fat pad. A case of transient buccal nerve paresis secondary to local anesthetic administration is presented.

Case Report

A 56-year-old woman was referred for Mohs surgery for treatment of a squamous cell carcinoma on her right cheek. To obtain anesthesia, 2 mL of 1:100,000 buffered lidocaine with epinephrine was infiltrated into the upper subcutaneous tissue. The tumor was removed in a single stage with clear margins (Figure 1). Before primary closure, the patient complained of

“heaviness” on the right side of her upper lip. When asked to pucker her lips, there was paresis of the elevator muscles of the right side of the upper lip (Figure 2). This paresis resolved within 24 hours (Figure 3). A diagnosis was made of transient buccal nerve paresis secondary to local anesthesia.

Discussion

The facial nerve is the motor nerve that innervates the muscles of facial expression and mastication. It has five branches: temporal, zygomatic, buccal, marginal mandibular, and cervical. Injury to branches of the facial nerve causes functional and cosmetic morbidity. The rate of permanent injury to branches of the facial nerve with face-lift procedure ranges from 0.4% to 2.6%.¹ The rate of transient facial nerve injury with these procedures is much higher at a reported 16%.² Although different series

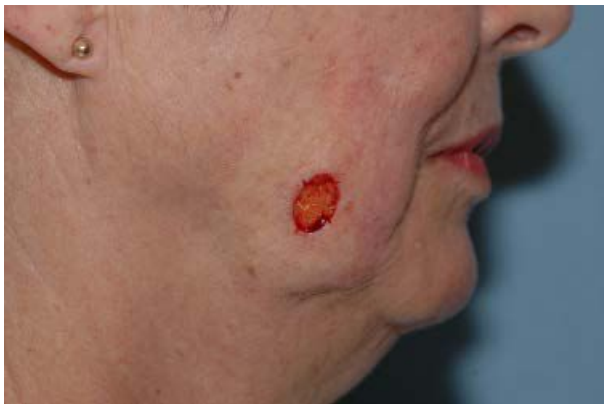

Figure 1. Defect on the lower part of the right cheek.

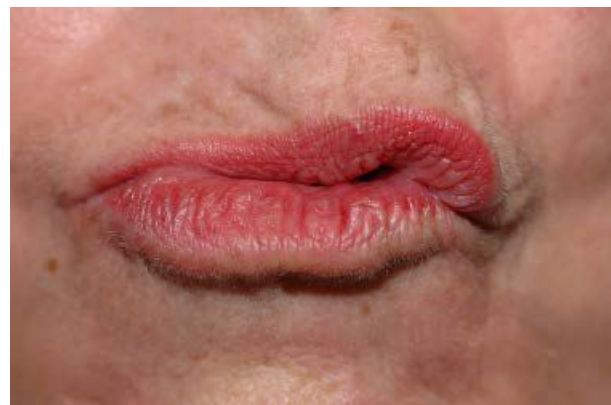

Figure 2. Paresis of the elevator muscles of the right side of the upper lip.

*Department of Dermatology, Mayo Clinic, Jacksonville, Florida

© 2007 by the American Society for Dermatologic Surgery, Inc. • Published by Blackwell Publishing •
ISSN: 1076-0512 • *Dermatol Surg* 2008;34:258–260 • DOI: 10.1111/j.1524-4725.2007.34052.x

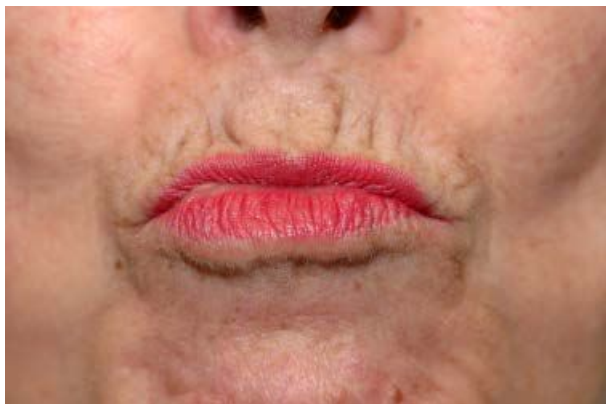

Figure 3. Resolution of paresis.

vary in their reports of which branch of the facial nerve is most frequently damaged in face-lift procedures, the buccal, marginal mandibular, and temporal nerves are the three branches most cited.³⁻⁵ The true rate of facial nerve injury in skin cancer surgery is unknown. The temporal and marginal mandibular nerves are the two branches of the facial nerve at greatest risk for injury.⁶ The temporal branch of the facial nerve is prone to injury during surgery on the

temple, above the zygomatic arch, because it lies superficial to the temporal fascia as the nerve traverses superiorly to innervate the frontalis muscle.⁶ The marginal mandibular nerve is prone to injury at the angle of the mandible, overlying the masseter muscle, as it is protected only by skin, subcutaneous fat, and fascia⁶ (Figure 4).

The buccal nerve originates from the main trunk of the facial nerve and traverses anteriorly to innervate the lip elevators. The buccal nerve is protected by the buccal fat pad and the superficial musculoaponeurotic system and is seldom injured in skin cancer surgery. The buccal nerve is at greater risk for injury during deep-plane face-lift operations¹ and oral maxillofacial procedures.⁷ The area of greatest vulnerability for the buccal nerve is anterior to the parotid gland, before it innervates the lip elevators.⁶ This area between the anterior border of the parotid gland and a line drawn from the lateral canthus to the oral commissure is considered a danger zone for the buccal and zygomatic nerves (Figure 4).

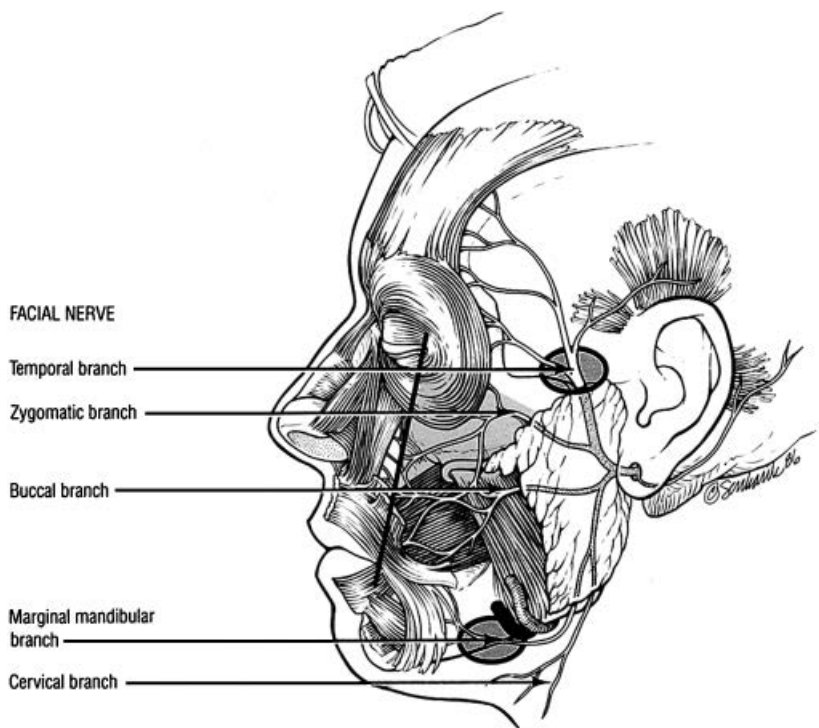


Figure 4. Facial nerve. Darkened areas indicate danger zones. (Reprinted, with permission, from Salasche et al.⁶)

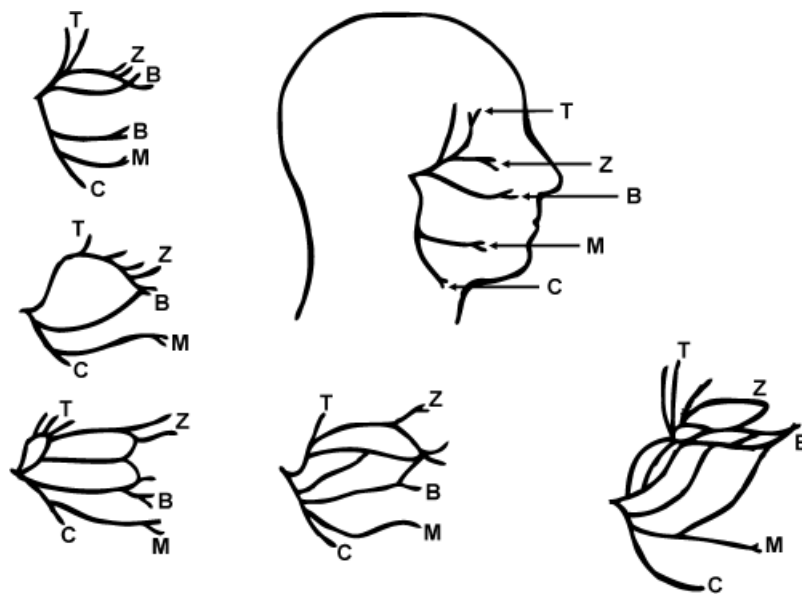


Figure 5. The chief types of facial nerve branching. B, buccal branch; C, cervical branch; M, marginal branch; T, temporal branch; Z, zygomatic branch. (Reprinted, with permission, from Gosain.¹)

The location of the defect directly above the mandible (Figure 1) suggests potential injury to the marginal mandibular nerve. There are two explanations for why this was not the case in this patient. First, this nerve becomes inferiorly displaced as structures sag with age. Second, the branching pattern of the facial nerve varies greatly (Figure 5), and these variations can affect the pattern of facial nerve injury. Of note, the branches of the buccal and zygomatic nerves communicate with adjacent branches of the facial nerve in 70% to 90% of patients. Because of this, injury to these branches is less likely to cause permanent damage, as there is cross-innervation with adjacent branches of the facial nerve.³ In contrast, the temporal and marginal mandibular branches are solitary in 85% of patients.³

Acknowledgments Editing, proofreading, and reference verification were provided by the Section of Scientific Publications, Mayo Clinic.

References

1. Gosain AK. Surgical anatomy of the facial nerve. *Clin Plast Surg* 1995;22:241–51.
2. Barton FE Jr. Rhytidectomy and the nasolabial fold. *Plast Reconstr Surg* 1992;90:601–7.
3. Baker DC, Conley J. Avoiding facial nerve injuries in rhytidectomy: anatomical variations and pitfalls. *Plast Reconstr Surg* 1979;64:781–95.
4. Castañares S. Facial nerve paralyses coincident with, or subsequent to, rhytidectomy. *Plast Reconstr Surg* 1974;54:637–43.
5. Lemmon ML, Hamra ST. Skoog rhytidectomy: a five-year experience with 577 patients. *Plast Reconstr Surg* 1980;65:283–97.
6. Salasche S, Bernstein G, Senkarik M. *Surgical anatomy of the skin*. Norwalk (CT): Appleton & Lange; 1988. pp. 8–10.
7. Hendy CW, Smith KG, Robinson PP. Surgical anatomy of the buccal nerve. *Br J Oral Maxillofac Surg* 1996;34:457–60.

Address correspondence and reprint requests to: Ali Hendi, MD, Department of Dermatology, Mayo Clinic, 4500 San Pablo Road, Jacksonville, FL 32224, or e-mail: hendi.ali@mayo.edu