

Adult laryngeal hemangioma: Report of four cases

Paul Lomeo, DO
John McDonald, DO
Judith Finneman, LPN, CST

Abstract

Laryngeal hemangiomas in adults are uncommon. We report four such cases seen at our clinic during an 18-month period in 1996 and 1997. All masses were detected by endoscopy, and all were biopsied and ablated uneventfully with a CO₂ laser. All four patients recovered without incident. We feel that laryngeal hemangiomas that affect only the glottic area can be treated endoscopically with a CO₂ laser without consequences.

Introduction

Hemangiomas are benign vascular tumors of unknown etiology. There are two types of laryngeal hemangioma: pediatric and adult. The pediatric type, also known as *congenital laryngeal hemangioma*, is the more common. It usually occurs in children younger than 2 months of age, although it is occasionally seen in children as old as 30 months. In adults, laryngeal hemangiomas can occur at any age. Patients with laryngeal hemangioma usually experience stridulous and difficult breathing.

The management of adult laryngeal hemangioma differs from that of pediatric disease. In the adult population, diagnosis and treatment are achieved by surgery. In the younger group, laryngeal hemangiomas usually resolve spontaneously during the first 2 years of life, and surgical intervention is rarely necessary. In this article, we briefly describe our experience in diagnosing and treating four adults with laryngeal hemangioma.

Case reports

During an 18-month period in 1996 and 1997, we saw four adults whose physical examinations were highly suspicious for laryngeal hemangioma. Each patient underwent

direct laryngoscopy with a CO₂ laser while under general anesthesia. A laser endotracheal tube was used for intubation, and the cuff was inflated with methylene blue. A Storz laryngoscope was used for direct visualization, and once the glottic region was inspected, the endoscope was placed in position with a suspension arm to prevent movement. Patients were positioned and draped according to standard laser surgery protocol. Their eyes were covered with saline-soaked pads, and all exposed skin was covered with saline-soaked towels.

In each case, a biopsy sample was obtained with a cup forceps, and the entire lesion was ablated with a CO₂ laser set at 10 W in the continuous mode. There was no damage to underlying structures. Bleeding was controlled by increasing the spot size on the micromanipulator and defocusing the laser beam. Following each procedure, each patient was awakened and observed for 2 to 3 hours prior to discharge. There were no signs of airway obstruction or bleeding at any time postoperatively. All patients were discharged on narcotic analgesics. No restrictions were put on their diet. Patients were asked to return to our clinic 1 week later, provided they did not experience any problems that would require an earlier visit.

Case 1. A 35-year-old woman came to our clinic complaining of breathing difficulties over the previous month, which had worsened within the previous few days. Her history was remarkable only in that she had smoked two packs of cigarettes per day for 15 years. Although the results of her standard physical examination were normal, both an indirect examination and a fiberoptic examination revealed that a large laryngeal mass was obstructing her airway (figure 1).

She was taken directly to the operating room so that measures could be instituted to protect her airway. She was told that a tracheotomy might be performed if her airway was compromised, but this was not necessary. Her airway was secured with a laser endotracheal tube, and her mass was biopsied and ablated. There was no involvement of any local or deep structures.

The woman was monitored closely for 6 months before

From the Department of Otolaryngology-Head and Neck Surgery, Mercy General Health Partners and Hackley Hospital, Muskegon, Mich.

Reprint requests: Paul Lomeo, DO, Shoreline ENT, 1762 Wagner Ave., Muskegon, MI 49442. Phone: (231) 777-2625; fax: (231) 773-8560.

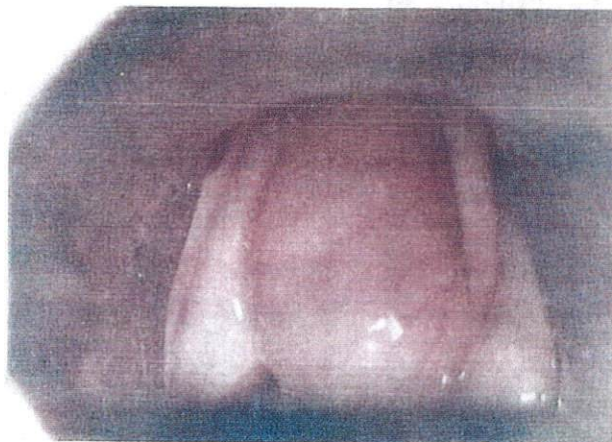

Figure 1. Case 1: Laryngoscopy shows a large, obstructing hemangioma on the right vocal fold in a 35-year-old woman.

being returned to the care of her primary care physician. Her glottic region returned to normal, and her voice improved. She experienced no further breathing difficulties, even in the supine position, despite the fact that she continued to smoke. She refused a videostroboscopic examination postoperatively. She was followed for approximately 18 months and was doing well, with no breathing or speaking difficulties.

Case 2. A 64-year-old woman reported a history of dyspnea and dysphonia of several years' duration. She had been seen by another otolaryngologist and diagnosed with Reinke's edema. She had smoked at least two packs of cigarettes per day for 40 years, and she was being treated for severe gastroesophageal reflux disease.

Videostroboscopy demonstrated a distinct blue mass on the right true vocal fold (figure 2). The mass was biopsied and ablated. There was no involvement of the deep structures.

The patient returned for frequent visits, and her voice improved over the course of several months. However, she continued to smoke heavily and refused to follow any medication or diet regimen to control her reflux. Otherwise, she was doing well 18 months later.

Case 3. A 38-year-old man was seen for persistent hoarseness. He was a known drug abuser, and he had smoked at least two packs of cigarettes per day for 15 years. Laryngoscopy showed that a hemangioma extended into the right anterior commissure (figure 3).

Biopsy and ablation were uneventful. The patient fared well postoperatively and underwent treatment in a drug rehabilitation program. He was also being treated with speech therapy. He continued to smoke, but he denied any further drug abuse.

Case 4. A 34-year-old woman came to the clinic complaining of hoarseness. She had smoked one pack of

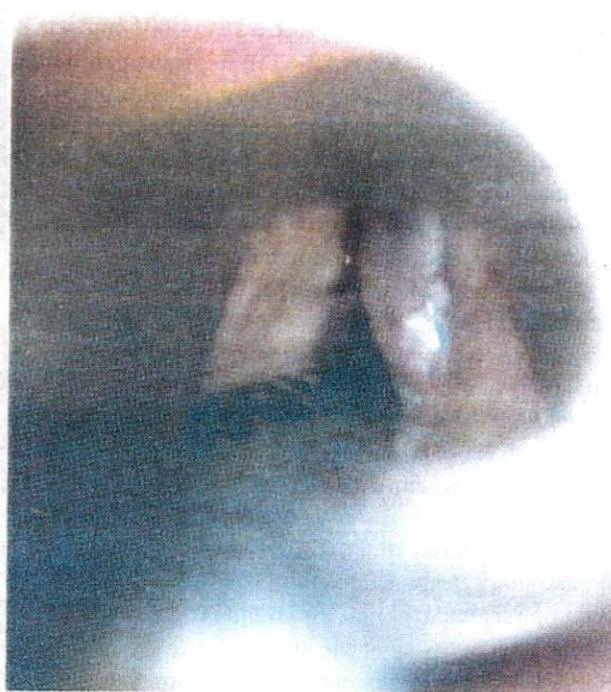

Figure 2. Case 2: Videostroboscopy shows a hemangioma on the right true vocal fold in a 64-year-old woman.

cigarettes per day for 10 years. The remainder of her history was unremarkable.

A fiberoptic examination in the office detected a lesion on the left true vocal fold, which laryngoscopy and biopsy later identified as a hemangioma. The mass was ablated, and no involvement of any other tissues was noted. During 12 months of followup, the woman was doing well. Her voice returned to normal, and she quit smoking.

Discussion

The first reported case of laryngeal hemangioma occurred in 1864.¹ Congenital laryngeal hemangioma was first reported in 1912.²

Adult hemangiomas. In an adult, a laryngeal hemangioma can occur at any age. Patients usually experience changes in voice quality or dysphagia. The only physical characteristic of an adult laryngeal hemangioma is irritation in the region. No skin lesions are present. The sex breakdown of our four cases notwithstanding, laryngeal hemangiomas are twice as common in men as in women.

Laryngeal hemangiomas can be detected on x-ray. They appear as a soft tissue density in the subglottic region that causes a narrowing of the airway. However, the diagnosis is very difficult to make without endoscopic examination. Endoscopy almost always reveals a unilateral bluish lesion.

The treatment of choice for adults is laser ablation. Two

types of laser have been used: the CO₂ laser (10,000-nm wavelength) and the Nd:YAG laser (1,604-nm wavelength). The CO₂ laser is set at 10 W in the continuous mode to perform direct laryngoscopy. Ablation carries no serious risk of injury to the deep structures when proper precautions are taken. The Nd:YAG laser is used in continuous mode as well, but at 15 to 20 W transmitting through a 25-mm optical fiber.³ Surgeon preference and availability at one's institution determine which is used.

Open surgery is indicated for severe cases, usually when there is an absolute airway obstruction that requires a tracheotomy or when a large mass extends into the deep structures of the laryngeal region.

Pediatric hemangiomas. In children, the differential diagnoses for airway obstruction are laryngomalacia, vocal fold paralysis, subglottic stenosis, laryngeal webbing, laryngeal atresia, laryngeal cleft, laryngeal saccular cyst, and laryngocele.

Pediatric laryngeal hemangiomas are usually accompanied by an abnormal cry, persistent stridor, and chronic

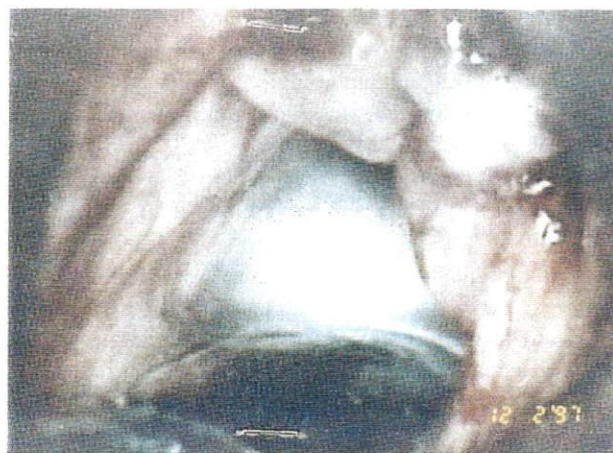

Figure 3. Case 3: Laryngoscopy shows a right hemangioma extending into the anterior commissure in a 38-year-old man.

cough. Stridor is usually noticed by a parent or guardian as abnormally noisy breathing sounds during the inspiratory phase. Unlike the adult type, approximately 50% of all pediatric laryngeal hemangiomas are accompanied by a cutaneous lesion. This condition can progress and become life threatening.

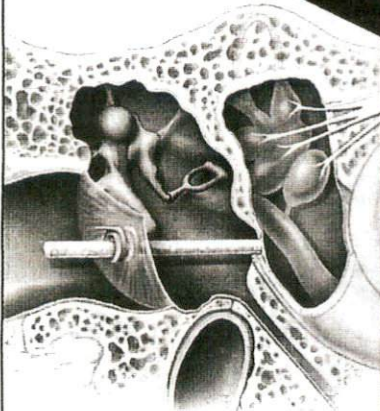
Pediatric laryngeal hemangiomas usually occur during the first 1 to 2 months of life. These masses rarely continue to grow after 2 years, and most undergo a complete involution by 30 months of age. Histologically, pediatric tumors have a capillary formation, whereas adult hemangiomas have a cavernous appearance. Unlike adult hemangiomas, the pediatric type is more common in girls than boys (ratio: 2:1).⁴

In those few instances when a mass has not involuted by 30 months of age, it can be treated by direct laser laryngoscopy. For large masses, an open surgery is effective. Other therapies have been tried and abandoned. For example, in the early 1980s, irradiation to the neck was attempted, but this procedure was halted because of the risk of tumor development later in life. Studies were conducted to determine if corticosteroid injections into the hemangioma would prevent the progression of the lesion, but this strategy also was discarded because of the risks of Cushing's syndrome, infection, and growth retardation.


References

1. MacKenzie M. Essay on Growths of the Larynx. Philadelphia: Lindsay and Blakeston, 1871.
2. Phillips J, Ruh HO. Angioma of the larynx: Especially its relationship to chronic laryngitis. *Am J Dis Child* 1912;5:123-30.
3. Yellin SA, LaBruna A, Anand VK. Nd:YAG laser treatment for laryngeal and hypopharyngeal hemangiomas: A new technique. *Ann Otol Rhinol Laryngol* 1996;105:510-5.
4. Konior RJ, Holinger LD, Russell EJ. Superselective embolization

Silverstein
MicroWick™



- Permits direct treatment of the diseased ear
- Simple, inexpensive office procedure
- Allows patient self-treatment (with minimal physician followup)
- Excellent clinical results



**FOR THE DIRECT TREATMENT
OF INNER EAR DISEASE**

www.micromedics-usa.com
1-800-624-5662

**Visit us at
AAO-HNSF
Booth 593**

micromedics, inc.
1285 Corporate Center Drive, #150
Eagan, Minnesota 55121 USA